

Elements of Morphology: Standard Terminology for the Ear

Alasdair Hunter,^{1*} Jaime L. Frias,² Gabriele Gillessen-Kaesbach,³ Helen Hughes,⁴
Kenneth Lyons Jones,⁵ and Louise Wilson⁶

¹Department of Genetics, Children's Hospital of Eastern Ontario, Ottawa, Canada

²Department of Pediatrics, Birth Defects Center, University of South Florida, Tampa, Florida

³Institut für Humangenetik, Universitätsklinikum Schleswig-Holstein, Campus Lübeck, Germany

⁴Institute of Medical Genetics, University Hospital of Wales, Cardiff, UK

⁵Division of Dysmorphology and Teratology, Department of Pediatrics, University of California, San Diego, La Jolla, California

⁶Department of Clinical Genetics, Great Ormond Street Hospital, University College London, London, UK

Received 9 September 2008; Accepted 15 October 2008

An international group of clinicians working in the field of dysmorphology has initiated the standardization of terms used to describe human morphology. The goals are to standardize these terms and reach consensus regarding their definitions. In this way, we will increase the utility of descriptions of the human phenotype and facilitate reliable comparisons of findings among patients. Discussions with other workers in dysmorphology and related fields, such as developmental biology and molecular genetics, will become more precise. Here we introduce the anatomy of the ear and define and illustrate the terms that describe the major characteristics of the ear.

© 2009 Wiley-Liss, Inc.

Key words: nomenclature; definitions; ear; anatomy; anthropometry

INTRODUCTION

General

This paper is part of a series of six papers defining the morphology of regions of the human body [Allanson et al., 2009b; Biesecker et al., 2009; Carey et al., 2009; Hall et al., 2009; Hennekam et al., 2009]. The series is accompanied by an introductory article describing general aspects of this study [Allanson et al., 2009a]. The reader is encouraged to consult the introduction when using the definitions.

Anatomy of the Ear

The anatomy of the external ear, also known as the auricle or pinna, is complex [Hunter and Yotsuyanagi, 2005] and remarkably inaccurately described by most authors. The major landmarks of the external ear are depicted in Figure 1. The external ear consists of skin (with adnexa), cartilage, and six intrinsic muscles. The anatomy of the various components of the ear are described below, and illustrations are shown each time in the section describing the various features of the components (Figs. 3, 13, 18, 24, 28, 46, and 68).

How to Cite this Article:

Hunter A, Frias J, Gillessen-Kaesbach G, Hughes H, Jones K, Wilson L. 2009. Elements of morphology: Standard terminology for the ear.

Am J Med Genet Part A 149A:40–60.

Antihelix: A Y-shaped curved cartilaginous ridge arising from the antitragus and separating the concha, triangular fossa, and scapha (Fig. 3). The antihelix represents a folding of the conchal cartilage and it usually has similar prominence to a well-developed helix. The stem (the part below the bifurcation) of the normal antihelix is gently curved and branches about two thirds of the way along its course to form the broad fold of the superior (posterior) antihelical crus, and the more sharply folded inferior (anterior) crus. The inferior and superior crura of the antihelix can vary both in volume and degree of folding.

Antihelix, inferior crus: The lower cartilaginous ridge arising at the bifurcation of the antihelix that ends beneath the fold of the ascending helix, and separates the concha from the triangular fossa (Fig. 3). The inferior antihelical crus runs in an anterior and slightly superior direction, is usually sharply defined, and appears less variable than its superior counterpart. A synonym is anterior crus of the antihelix.

Antihelix, superior crus: The upper cartilaginous ridge arising at the bifurcation of the antihelix that separates the scapha from the triangular fossa (Fig. 3). The superior crus runs in a superior and slightly anterior direction and is usually less sharply folded than the

*Correspondence to:

Dr. Alasdair Hunter, 529 Clarence St East, Ottawa, ON, Canada K1N 5S4.
E-mail: heddaldasair@aol.com

Published online 16 January 2009 in Wiley InterScience
(www.interscience.wiley.com)

DOI 10.1002/ajmg.a.32599

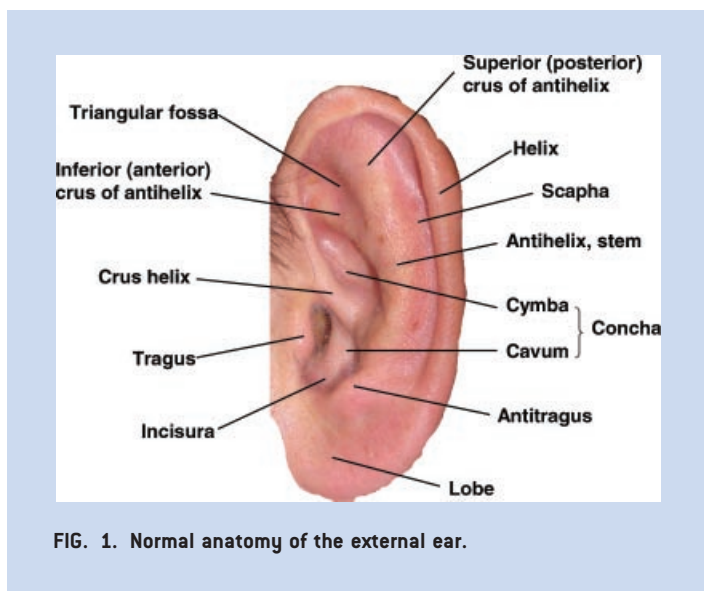


FIG. 1. Normal anatomy of the external ear.

lower portion and inferior crus. A synonym is the posterior crus of the antihelix.

Antitragus: The anterosuperior cartilaginous protrusion lying between the incisura and the origin of the antihelix (Fig. 13). The anterosuperior margin of the antitragus forms the posterior wall of the incisura.

Concha: The fossa bounded by the tragus, incisura, antitragus, antihelix, inferior crus of the antihelix, and root of the helix, into which opens the external auditory canal. It is usually bisected by the crus helix into the cymba superiorly and cavum inferiorly (Fig. 18).

Frankfurt horizontal: A plane connecting the lowest point on the lower margin of each orbit and highest point on the upper margin of the external auditory meatus [Farkas, 1981]. The Frankfurt horizontal or Frankfurt plane is used as the general horizontal plane of the head and as reference point for other planes and structures.

Helix: The outer rim of the ear that extends from the superior insertion of the ear on the scalp (root) to the termination of the cartilage at the earlobe (Fig. 28). The helix can be divided into three approximate parts: the *ascending* helix, which extends vertically from the root; the *superior* helix, which begins at the top of the ascending portion, extends horizontally and curves posteriorly to the site of Darwin tubercle (vide infra); the *descending* helix (sometimes called *posterior*), which begins inferior to Darwin tubercle and extends to the superior border of the earlobe. The lower portion of the posterior part is often non-cartilaginous. The border of the helix usually forms a rolled rim but the helix is highly variable in shape. Lange [1966] developed a graphic classification of folding variants (Fig. 29; modified from Lange [1966]). Figure 30 illustrates some variation in the helix observed among a small group of colleagues.

Helix, crus: The continuation of the anteroinferior ascending helix, which extends in a posteroinferior direction into the cavity of the concha above the external auditory meatus (Fig. 1). The average crus helix extends about one half to two thirds the distance across the concha. A synonym is *crista helicis*

Lobe: The soft, fleshy, inferior part of the pinna. It is bounded on its posterosuperior border by the end of the descending helix, on the anterosuperior border by the inferior border of the antitragus and superiorly by the incisura (Fig. 46). The earlobe is highly variable in size and in the degree of attachment of the anteroinferior portion to the face.

Scapha: The groove between the helix and the antihelix.

Tragus: A posterior, slightly inferior, protrusion of skin-covered cartilage, anterior to the auditory meatus. The inferoposterior margin of the tragus forms the anterior wall of the incisura (Fig. 68).

Triangular fossa: The concavity bounded by the superior and inferior crura of the antihelix and the ascending portion of the helix.

Anatomical Variation

Anomalies of the ear include quantitative traits and qualitative features of the entire ear, and of the individual components.

- (1) Variation in size (macrotia; microtia; anotia).
- (2) Variation in position (low-set ears; posterior angulation of the ear).
- (3) Variations of the individual anatomical parts: antihelix; antitragus; concha; helix; lobe; scapha; tragus; triangular fossa.
- (4) Named ear anomalies (crumpled ear; cryptotia; cupped ear; lop ear; preauricular and auricular pits; preauricular and auricular tags; preauricular ectopias; prominent ear; question mark ear; detachment of ascending helix; satyr ear; shell ear; Stahl ear).

The various features are listed alphabetically. If a feature is indicated in ***bold-italics***, the feature is listed and a definition is available. This can be in the present or one of the accompanying papers. The terms are alphabetized based on the physical feature, not the modifier.

The appearance of facial morphology varies considerably with the position of the observer and observed person, and facial movements. In assessing morphology, the head of the observed person should be held in the Frankfurt horizontal, with the facial and neck muscles relaxed, eyes open, lips making gentle contact, and a neutral facial expression. The face of the observer should be at the same height as the face of the observed person.

DEFINITIONS

Anotia

Definition: Complete absence of any auricular structures (Fig. 2).
objective

Synonym: Ear, absent

Antihelical Shelf

Definition: Antihelix protrusion directed more anteriorly than laterally, forming a shelf overlying the posterior concha (Figs. 3–4).
subjective

Comments: In marked cases this often appears to be associated with lack of lateral protrusion of the antihelix.

Synonym: Conchal shelf

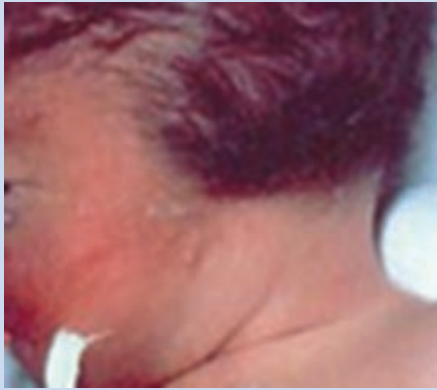

FIG. 2. Anotia.

Antihelix, Absent

Definition: No discernible ridge between concha and triangular fossa, and helix (Fig. 5). *objective*

Comment: This finding is common in a *Protruding* and *Cupped ear*, where the superior and inferior parts of the antihelix are often absent. This is distinct from partial absence of the antihelix as may occur in, for example, *Underdeveloped inferior crus of the antihelix*.

Antihelix, Additional Crus

Definition: Supernumerary ridge or crus of the ear arising from the antihelix (Fig. 6). *objective*

Comment: The supernumerary crus usually emanates posteriorly from the antihelix at, or just above, the point of its bifurcation, but may have a different origin. In the former case, the finding is termed *Stahl ear* [Yamada and Fukuda, 1980].

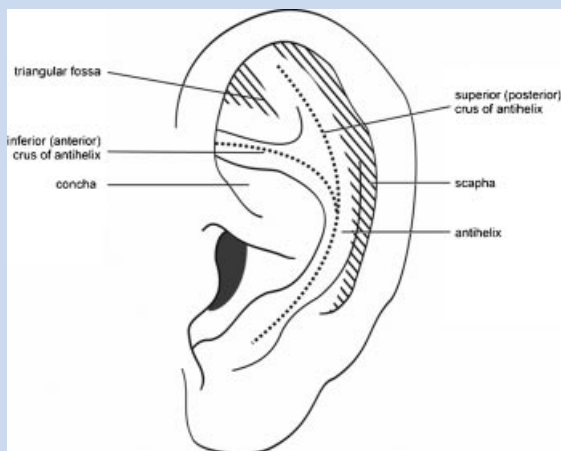


FIG. 3. Anatomy of antihelix.

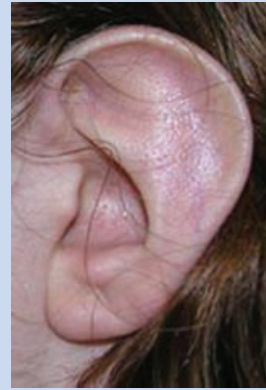

FIG. 4. Antihelical shelf.

Antihelix, Angulated

Definition: Antihelical ridge that forms an acute angle between the antitragus and its bifurcation (stem) instead of a gently curving arc (Fig. 7). *subjective*

Antihelix, Inferior Crus, Broad

Definition: Increased width of the inferior cross-section of the inferior crus (Fig. 8c). *subjective*

Comment: This finding is highly variable, and the range is illustrated in Figure 8. The inferior crus is usually sharply folded giving a narrow profile.

Antihelix, inferior crus, hypoplastic: see *Antihelix, inferior crus, underdeveloped*

Antihelix, inferior crus, hypotrophic: see *Antihelix, inferior crus, underdeveloped*

Antihelix, inferior crus, hyperplastic: see *Antihelix, inferior crus, prominent*

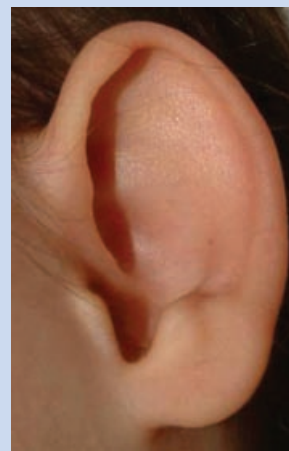


FIG. 5. Absent antihelix.

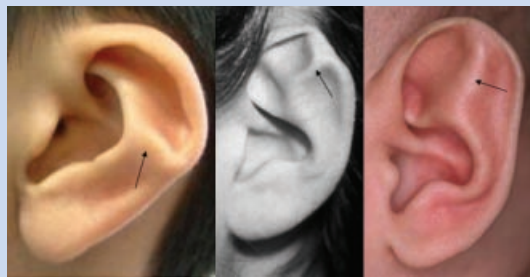


FIG. 6. Additional crus of antihelix (Stahl ear). The additional crus is indicated in each panel by an arrow.

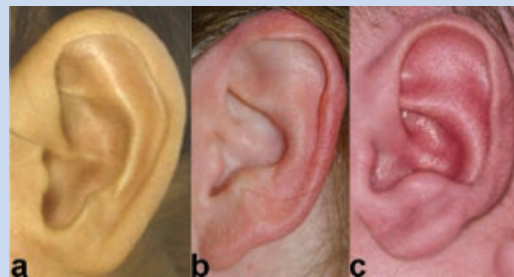

FIG. 8. Variation in width of the inferior crus of the antihelix. a: Narrow. b: Average. c: Broad.

Antihelix, inferior crus, hypertrophic: see *Antihelix, inferior crus, prominent*

Antihelix, Inferior Crus, Prominent

Definition: Increased protrusion of the inferior crus relative to the prominence of the antihelix stem (Fig. 9c). *subjective*

Comment: This finding is highly variable, and the range is illustrated in Figure 9.

Replaces: Inferior crus of antihelix, hyperplastic; inferior crus of antihelix, hypertrophic

Antihelix, Inferior Crus, Underdeveloped

Definition: Decreased protrusion of the inferior crus relative to the prominence of the antihelix stem (Fig. 9a). *subjective*

Comment: This finding is highly variable.

Replaces: Inferior crus of antihelix, hypotrophic; inferior crus of antihelix, hypoplastic

Antihelix, stem, hyperplastic: see *Antihelix, stem, prominent*

Antihelix, stem, hypertrophic: see *Antihelix, stem, prominent*

Antihelix, stem, hypoplastic: see *Antihelix, stem, underdeveloped*

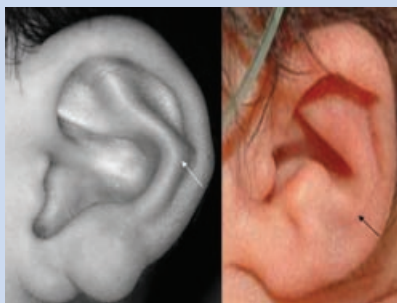

FIG. 7. Angulated antihelix. Note also the presence of a bifid lobe in the left panel.

Antihelix, stem, hypotrophic: see *Antihelix, stem, underdeveloped*

Antihelix, Stem, Prominent

Definition: Increased protrusion of the antihelical ridge, proximal to its bifurcation, relative to the prominence of the helix (Fig. 10d,e). *subjective*

Comments: This finding is highly variable, and the range is illustrated in Figure 10. The relative prominence is attributable to either increased volume of the cartilage and/or the acuteness of the folding angle. Interpretation of relative antihelical prominence may be difficult when the conchal anatomy is distorted, for example a *Cupped ear*.

Replaces: Antihelix stem, hyperplastic; antihelix stem, hypertrophic

Antihelix, Stem, Serpiginous

Definition: Posterior curving of the antihelix from its origin at the antitragus, traveling initially almost perpendicular to the descending helix and obscuring some of the concha (Fig. 11). *subjective*

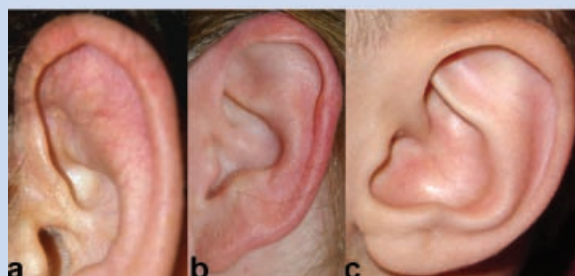


FIG. 9. Prominent and underdeveloped inferior crus of antihelix. a: Underdeveloped. b: Average. c: Prominent.

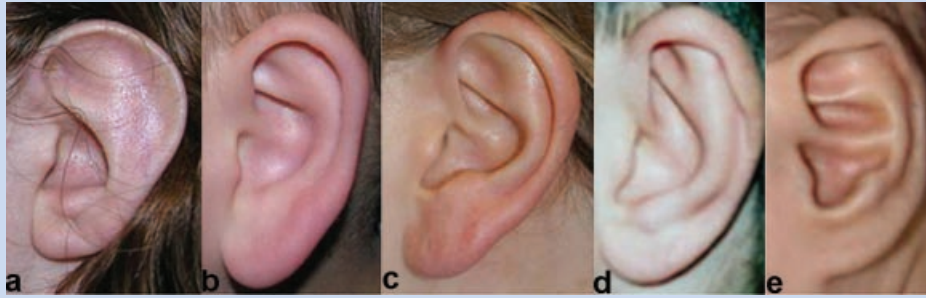


FIG. 10. Variation in protrusion of the antihelix stem. a: Marked underdevelopment. b: Mild underdevelopment. c: Average development. d: Mild prominence. e: Marked prominence.

Antihelix, Stem, Underdeveloped

Definition: Decreased protrusion of the antihelical ridge, proximal to its bifurcation, relative to the prominence of a normal helix (Fig. 10a,b). *subjective*

Comments: This finding is highly variable, and the range is illustrated in Figure 10. The degree of prominence is attributable to the volume of the cartilage and/or the acuteness of the folding angle. Interpretation of degree of antihelical prominence may be difficult when the conchal anatomy is distorted, for example a *Cupped ear*.

Replaces: Antihelix stem, hypotrophic; antihelix stem, hypoplastic

Antihelix, superior crus, hyperplastic: see *Antihelix, superior crus, prominent*

Antihelix, superior crus, hypertrophic: see *Antihelix, superior crus, prominent*

Antihelix, superior crus, hypoplastic: see *Antihelix, superior crus, underdeveloped*

Antihelix, superior crus, hypotrophic: see *Antihelix, superior crus, underdeveloped*

Antihelix, Superior Crus, Prominent

Definition: Increased protrusion of the superior crus relative to the prominence of a normal antihelix stem (Fig. 12d,e). *subjective*

Comment: This finding is highly variable, and the range is illustrated in Figure 12. There may be an inverse relationship between the relative sizes of the superior and inferior crura, but these should be coded separately.

Replaces: Superior crus of antihelix, hypertrophic; superior crus of antihelix, hyperplastic

Antihelix, Superior Crus, Underdeveloped

Definition: Decreased protrusion of the superior crus relative to the prominence of a normal antihelix stem (Fig. 12a,b). *subjective*

Comment: This finding is highly variable, and the range is illustrated in Figure 12. There may be an inverse relationship between the relative size of the superior and inferior crura, but these should be assessed separately.

Replaces: Superior crus of antihelix, hypotrophic; superior crus of antihelix, hypoplastic

Antihelix, third crus: see *Antihelix, additional crus* and *Stahl ear*

Antitragus, Absent

Definition: Absence of the anterosuperior prominence of the area between the bottom of the incisura and the inner margin of the antihelix (Figs. 13 and 14a,b [line 0]). *objective*

Comment: The size of the antitragus is highly variable, and the range is illustrated in Figure 14b [modified from Lange, 1966].

Antitragus, Bifid

Definition: Double rather than single peak of the antitragus (Fig. 15). *objective*

Synonym: Antitragus, double

Antitragus, double: see *Antitragus, bifid*

Antitragus, enlarged: see *Antitragus, prominent*

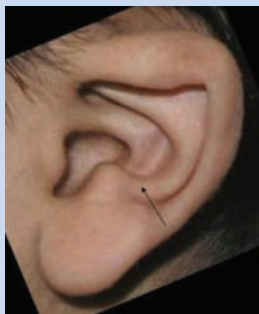


FIG. 11. Serpiginous stem.

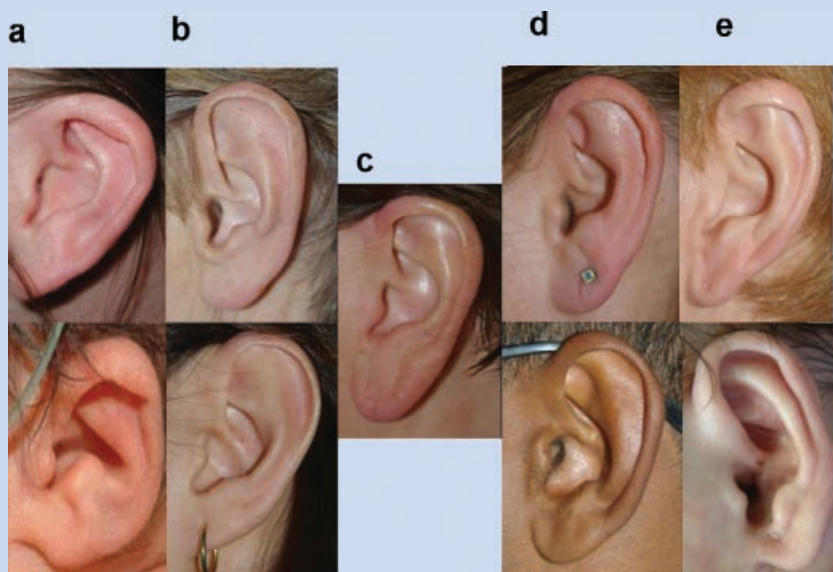


FIG. 12. Prominent and underdeveloped superior crus of antihelix. a: Absent, very indistinct. b: Slightly indistinct. c: Average. d: Slightly more distinct. e: Very distinct, sharp.

Antitragus, Everted

Definition: Positioning of the antitragus at an angle perpendicular to the plane of the ear (oriented away from the plane of the ear) (Fig. 16). *objective*

Comment: This is a common feature.

Antitragus, hyperplastic: see *Antitragus, prominent*

Antitragus, hypertrophic: see *Antitragus, prominent*

Antitragus, hypoplastic: see *Antitragus, underdeveloped*

Antitragus, hypotrophic: see *Antitragus, underdeveloped*

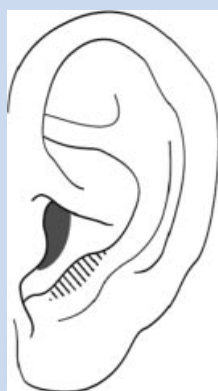

FIG. 13. Normal anatomy of antitragus.

Antitragus, Prominent

Definition: Increased anterosuperior prominence of the area between the bottom of the incisura and the inner margin of the antihelix (Figs. 14b [line 3], 17c). *subjective*

Comment: This finding is highly variable, and the range is illustrated in Figures 14 and 17.

Synonym: Antitragus, enlarged

Replaces: Antitragus, hyperplastic; antitragus, hypertrophic

Antitragus, small: see *Antitragus, underdeveloped*

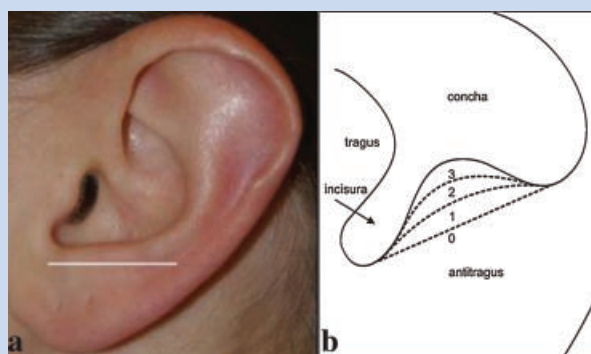


FIG. 14. Variation in size of the antitragus. a: Absent antitragus. b: The size of the antitragus is divided into 4°, of which 0 indicates absence, 1 is underdeveloped, 2 indicates the average size, and 3 indicates prominence (Fig. 14b adapted from Lange, 1966).

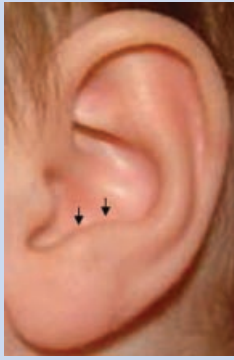

FIG. 15. Bifid antitragus.

Antitragus, Underdeveloped

Definition: Reduction in the anterosuperior prominence of the area between the bottom of the incisura and the inner margin of the antihelix (Figs. 14b [line 1], 17a). *subjective*

Comment: This finding is highly variable, and the range is illustrated in Figures 14 and 17.

Synonym: Antitragus, small

Replaces: Antitragus, hypoplastic; antitragus, hypotrophic

Concha, Extra Fold

Definition: Folds or ridges within the concha that are distinct from the crus helix (Figs. 18–19). *objective*

Comment: These folds may occur in the absence of a well developed crus helix and can be distinguished by their separate origin and position.

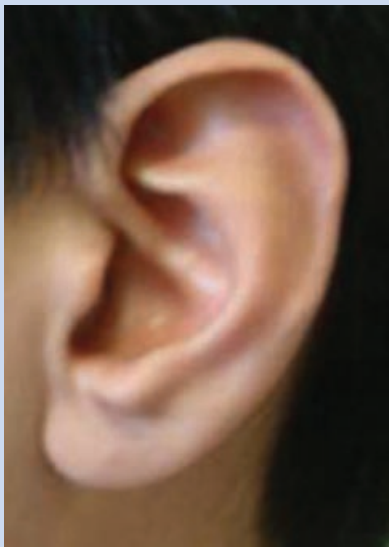

FIG. 16. Everted antitragus.

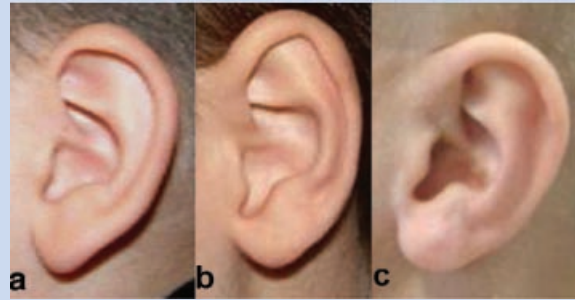


FIG. 17. Prominent and underdeveloped antitragus. a: Underdeveloped. b: Average. c: Prominent.

Conchal shelf: see *Antihelical shelf*

Constricted ear: see *Question mark ear*

Cosman ear: see *Question mark ear*

Cryptotia

Definition: Invagination of the superior part of the auricle under a fold of temporal skin (Fig. 20). *objective*

Comments: There are associated anomalies of the upper antihelix and crura. The upper one-third of the auricle is primarily affected and there is an inferomedial displacement of the *Helical Darwin tubercle*. Two types are recognized: Type I, the antihelix and superior crus are reduced in size (Fig. 20a); Type II, it is the antihelix and inferior crus that are affected (Fig. 20b) [Hirose et al., 1985].

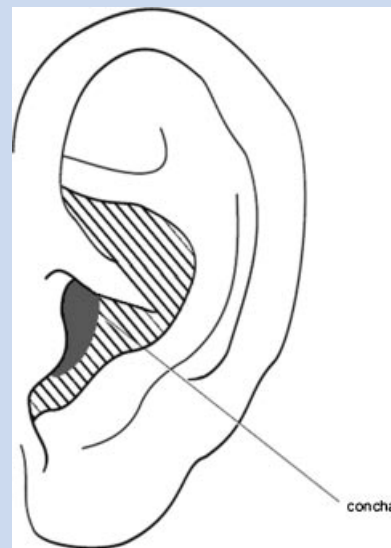


FIG. 18. Normal area of concha.

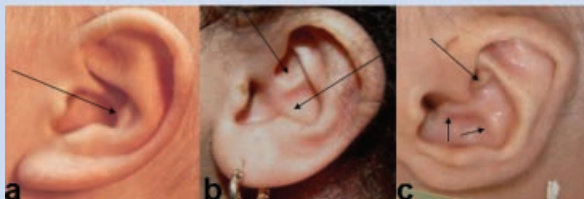


FIG. 19. Extra folds in the concha.

Ear, absent: see *Anotia*

Ear, additional crus: see *Antihelix*, *additional crus* and *Stahl ear*

Ear, bat: see *Ear, protruding*

Ear, capuchin: see *Ear, cupped*

Ear, cockleshell: see *Microtia*, *second degree*

Ear, constricted helix type IV: see *Microtia*, *second degree*

Ear, Crumpled

Definition: Distortion of the course of the normal folds of the ear and the appearance of supernumerary crura and folds (Fig. 21). *subjective*

Comments: This is distinct from *Stahl ear* and *Shell ear*, with which the term has sometimes been conflated. The appearance often changes markedly after birth.

Ear, Cupped

Definition: Laterally protruding ear that lacks antihelical folding (including absence of inferior and superior crura) (Fig. 22). *subjective*

Replaces: Ear, Capuchin

Ear, cupped, severe/type III: see *Microtia*, *second degree*

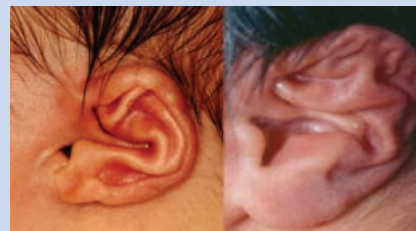

FIG. 21. Crumpled ear.

Ear, devil: see *Satyr ear*

Ear, dog-bite: see *Helix*, *underfolded*

Ear, dysplastic: The term “dysplastic” is no longer accepted as a descriptor for an ear with unusual morphology. Each specific anatomical component of the ear should be described when the ear is thought to be “abnormal” in appearance.

Ear, Focal Absence

Definition: Absence of a localized portion of the ear, when that cannot be described by a more precise term (e.g., absent ear lobe) (Fig. 23). *objective*

Comment: This definition is in the terminology set to acknowledge that there may be particular instances of absent structures not captured by the included terms. The specific affected area should be noted. For example, focal absence of the triangular fossa.

Ear, grade II dysplasia: see *Microtia*, *second degree*

Ear, grade III dysplasia: see *Microtia*, *third degree*

Ear, hypoplastic, group II: see *Microtia*, *third degree*

Ear, long

Definition: Median longitudinal ear length greater than two SD above the mean (Fig. 24). *objective* OR

Apparently increased length of the ear. *subjective*

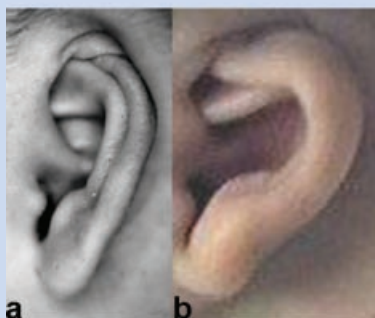


FIG. 20. Cryptotia. a. Type I; b. Type II.

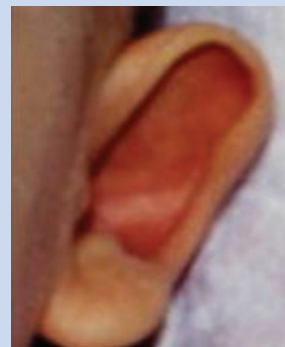


FIG. 22. Cupped ear.

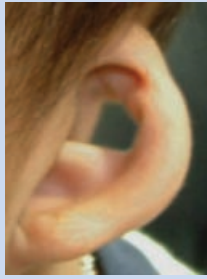


FIG. 23. Focal aplasia of ear.

Comments: Ear length is determined by the maximal distance from the superior aspect to the inferior aspect of the external ear. Normal values are available from birth to 16 years of age [Feingold and Bossert, 1974; Hall et al., 2007] and birth to 18 years of age [Farkas, 1981] specific for sex. Adult values for length and width, separated by sex, are published from a sample of US Army personnel (Tech Report NATICK/TR-89/027, pp 89–90) but these are difficult to obtain. Adult Japanese data are also available [Itoh et al., 2001]. Both adult sets suggest ears increase in length into adulthood and ears in males are larger than those in females. Ears probably more often look large in relation to a small head than actually are large. For this reason we strongly support measurements in assessing ear length. Subjective assessments of ear length should only be used if unavoidable. We encourage recording ear width as well [Farkas, 1981]. In fact, the commonly used term *Macrotia* is a bundled term comprising increased length and width (surface area).

Ear, Low-Set

Definition: Upper insertion of the ear to the scalp below an imaginary horizontal passing through the inner canthi and extend that line posteriorly to the ear (Fig. 25). *objective*

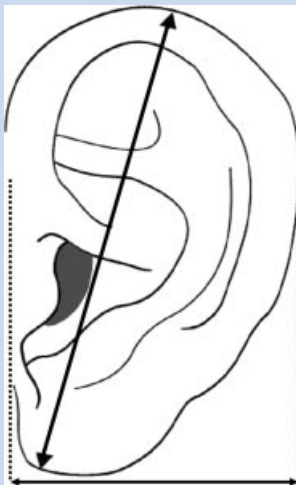


FIG. 24. Lines illustrating maximal longitudinal ear length and ear width.

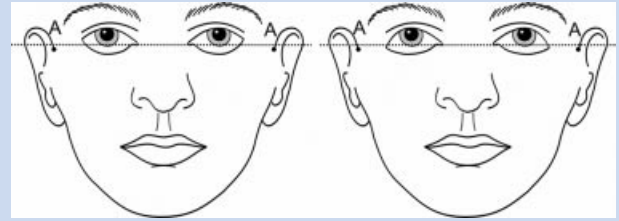


FIG. 25. Ear positioning. Please note that the position of the ears is normal in both graphs despite the difference in positioning of the outer canthi.

Comments: The position of the ear can be determined in four different ways [Hall et al., 2007]. There is some controversy regarding objective assessments of ear position as methods do not place the ear with respect to a fixed plane [Hall et al., 2007]. The Frankfurt plane uses the position of the auditory meatus as a landmark and thus can not be used to assess ear position. If palpebral fissures run horizontal they can be used to guide the plane. The definition used here minimizes the problem whereby the position of the subject's head relative to the observer may influence the subjective impression of the position of the ears. Subjective assessment of ear position is unacceptable since it is unreliable and often confounded by changes in head shape, size and tilt or changes in ear anatomy, especially the superior portion.

Ear, mini: see *Microtia, second degree*

Ear, peanut: see *Microtia, third degree*

Ear, Posterior Angulation, Increased

Definition: Angle formed by the line perpendicular to the Frankfurt plane and the medial longitudinal axis of the ear (the two most remote points of the ear) greater than 2 SD above the mean for age (Fig. 26). *objective*

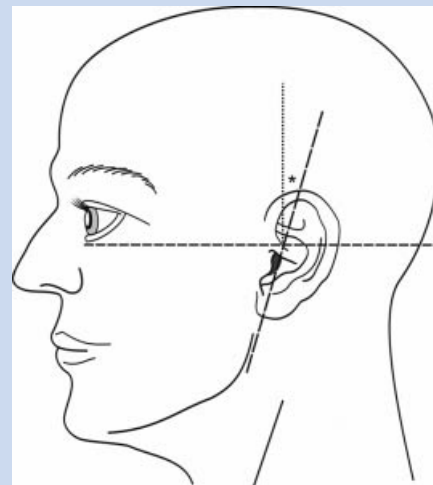


FIG. 26. Measurement of posterior rotation of the ear. Angle * is presently used to determine the degree of rotation.

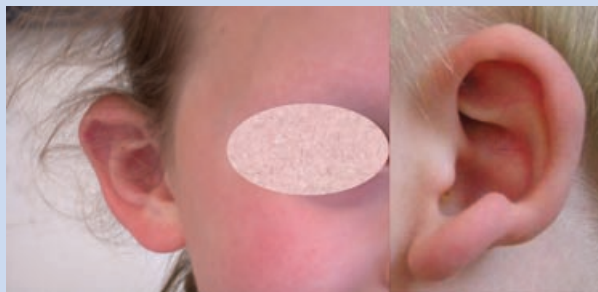

FIG. 27. Protruding ears.

Comments: Normal values are available [Farkas, 1981; Hall et al., 2007]. The mean angle is near 20° used the Frankfurt plane is compromised if the ear is also low-set. Subjective assessment of ear rotation is unacceptable because it is unreliable and often confounded by changes in head position. Abnormalities of ear shape may make it difficult to reliably determine the medial longitudinal axis of the ear. In such cases, it is probably unwise to make an assessment of the rotational status of the ear.

Synonym: Ear, posteriorly rotated

Ear, posterior helical groove: see *Helix, posterior pit*

Ear, posterior helical notch: see *Helix, posterior pit*

Ear, posteriorly rotated: see *Ear, posterior angulation, increased*

Ear, prominent: see *Ear, protruding*

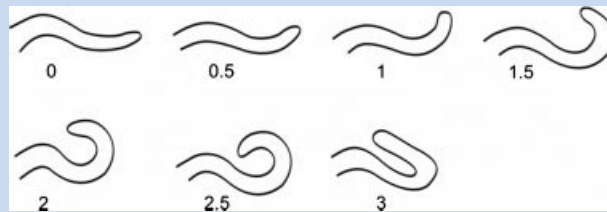


FIG. 29. Variations in folding of the helix in cross-section [adapted from Lange, 1966].

Ear, Protruding

Definition: Angle formed by the plane of the ear and the mastoid bone greater than the 97th centile for age (Fig. 27). *objective* OR

Outer edge of the helix more than 2 cm from the mastoid at the point of maximum distance. *objective*

Comments: Normal values are available [Farkas, 1981; Hall et al., 2007]. In mild cases the superior crus of the antihelix is deficient; in more severe cases the lack of normal folding may be more extensive, but these should be recorded separately. Ears that are protruding may give the appearance of increased size, but this should be assessed separately.

Synonym: Ear, prominent

Replaces: Ear, bat

Ear, shell: see *Microtia, second degree*

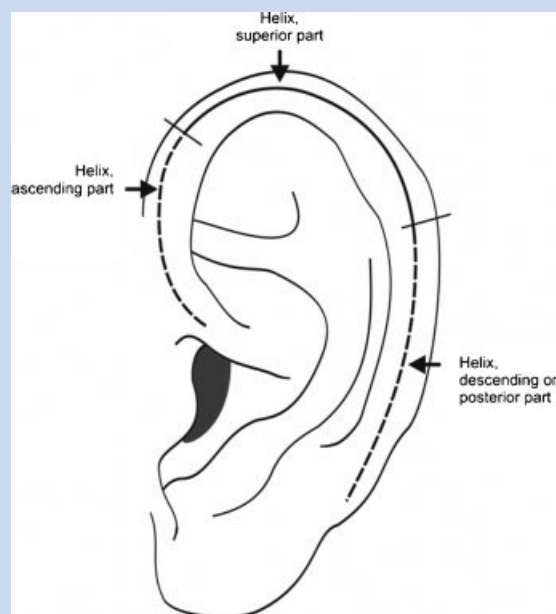

FIG. 28. Normal anatomy of the helix. a: Ascending part. b: Superior part. c: Descending or posterior part.

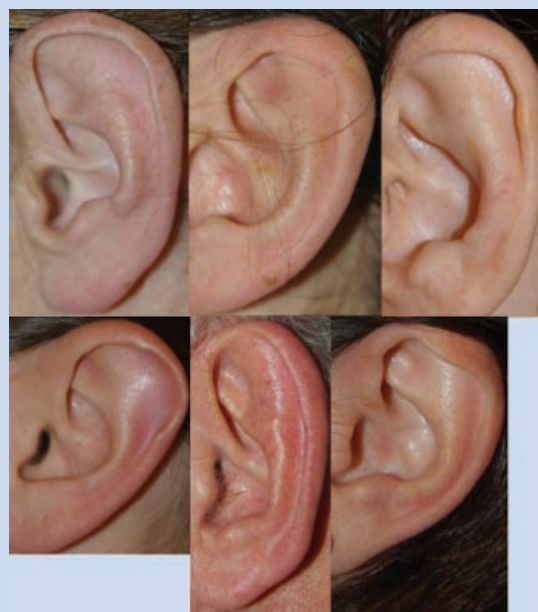

FIG. 30. Variation in helix formation among the group of clinical geneticists involved in defining morphology.

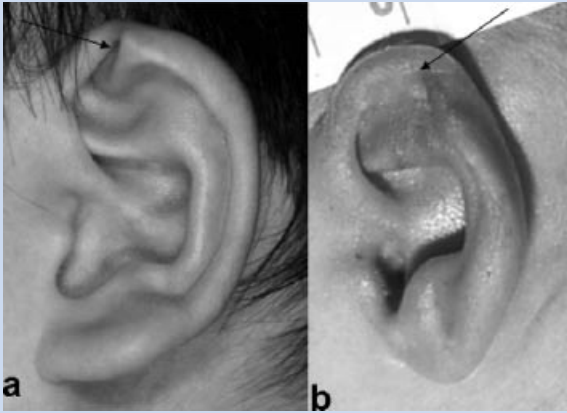


FIG. 31. Cleft helix. In b, the term notched helix is also used.

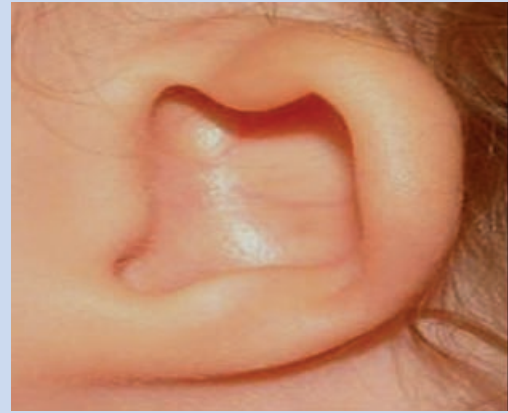

FIG. 33. Absent crus of helix.

Ear, Short

Definition: Median longitudinal ear length greater than 2 SD below the mean (Fig. 24). *objective* OR

Apparently decreased length of the ear. *subjective*

Comments: Ear length is determined by the maximal distance from the superior aspect to the inferior aspect of the external ear. Normal values are available from birth to 16 years of age [Feingold and Bossert, 1974; Hall et al., 2007] and birth to 18 years of age [Farkas, 1981] specific for sex. Adult values for length and width, separated by sex, are published from a sample of US Army personnel (Tech Report NATICK/TR-89/027, pp 89–90) but these are difficult to obtain. Adult Japanese data are also available [Itoh et al., 2001]. Both adult sets suggest ears increase in length into adulthood and ears in males are larger than those in females. Subjective assessment of the length of the ear is markedly influenced by the other craniofacial dimensions and easily distorted. For this reason we strongly support measurements in assessing ear length. Subjective assessments of shortness of the ear should only be used if unavoidable. The commonly used term *Microtia* is a bundled term comprising decreased length and width (surface area).

Ear, snail: see *Microtia, second degree*

Helix, Cleft

Definition: Defect in the continuity of the helix, which may occur at any point along its length (Figs. 28, 31). *objective*

Comment: This may take the form of a sharp cleft as in Figure 31a, or a less well-demarcated area as in the outer upper portion of Figure 31b. This should be distinguished from a *Question-mark ear*. If the defect or notch occurs at the junction of the superior and descending portions of the helix, it should be coded as *Darwin notch of the helix*.

Synonym: Helix, notched

Helix, Crimped

Definition: Linear, circumferential indentation in the convexity of the outer surface of the helix (Fig. 32). *subjective*

Comment: The crimp is usually found in the middle third of the descending helix. The helix has the appearance of having been pinched or flattened along its posterior margin. The crimp may distort the free margin of the helix.

Synonym: Indented helix.

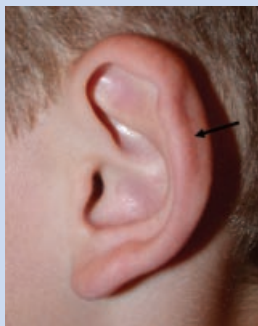


FIG. 32. Crimped helix.

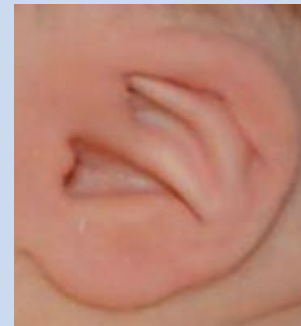


FIG. 34. Crus helix connected to antihelix.

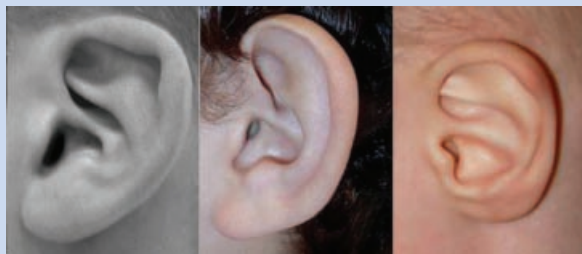


FIG. 35. Expanded terminal portion of crus helix.

Helix, Crus, Absent

Definition: Continuum between the tragus and ascending helix, without any evidence of a posterior extension (crus) towards the concha (Fig. 33). *subjective*

Helix, Crus, Connected to Antihelix

Definition: Extension of the ridge of the crus helix across the ear and connection of the crus to the antihelix (Fig. 34). *objective*

Helix, Crus, Expanded Terminal Portion

Definition: Widening, rather than tapering, of the crus at its posterior border near the antihelix (Fig. 35). *subjective*

Helix, Crus, Horizontal

Definition: Main axis of the crus of the helix perpendicular to the medial longitudinal axis of the ear, instead of sloping inferoposteriorly (Fig. 36). *subjective*

Comment: The term “railroad track sign” has been used to describe prominent horizontal crus of the helix in combination with prominent and parallel inferior crus of the antihelix. It is preferable to simply describe each component separately.

Helix, crus, hypertrophic: see **Helix, crus, prominent**

Helix, crus, hypertrophic: see **Helix, crus, prominent**

Helix, crus, hypoplastic: see **Helix, crus, underdeveloped**

Helix, crus, hypotrophic: see **Helix, crus, underdeveloped**

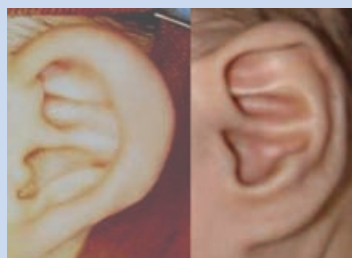


FIG. 36. Horizontal crus of helix.

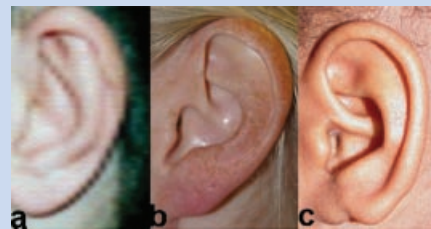


FIG. 37. Degree of development of the crus helix. a: Underdeveloped. b: Average. c: Prominent.

Helix, Crus, Prominent

Definition: Development of the crus helix to the same degree as an average antihelix stem or helix (Fig. 37c). *subjective*

Comments: This finding is highly variable, and the range is illustrated in Figure 37. Judgment of prominence is highly subjective and may be influenced by the relative development of the other ear components. There appears to be a correlation between the length of the crus helix and its relative prominence, but these should be coded separately.

Replaces: Hypertrophic crus helix; hyperplastic crus helix

Helix, Crus, Serpiginous

Definition: Curving course of the crus of the helix, approaching or joining the antitragus (Fig. 38). *subjective*

Helix, Crus, Tragal Bridge

Definition: The anterior origin of the crus encompasses the superior margin of the tragus, the crus overrides the upper portion of the conchal cavum and ends at the antihelix (Fig. 39). *subjective*

Comment: The antihelix can also be anomalous, but this should be coded separately.

Helix, Crus, Underdeveloped

Definition: Flatter and/or shorter crus helix than average (Fig. 37a). *subjective*

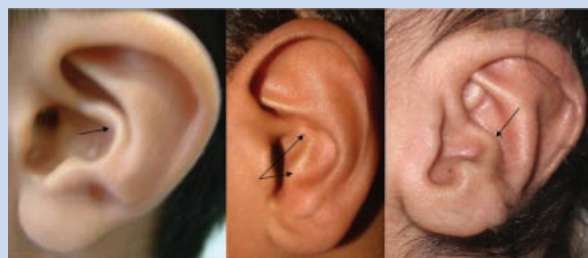


FIG. 38. Serpiginous crus of helix.

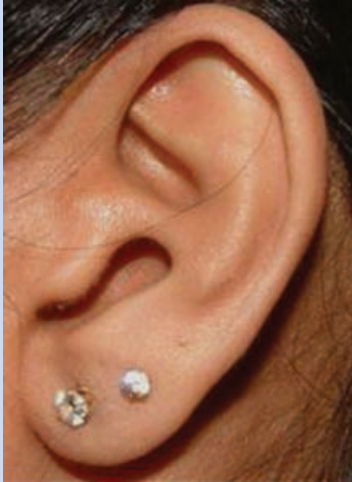

FIG. 39. Tragal bridge of crus of helix. Note the crus helix is also attached to the antihelix, which is under-developed in its lower portion.

Comments: This finding is highly variable, and the range is illustrated in Figure 37. There appears to be a correlation between the length of the crus helix and its relative prominence.

Replaces: Hypoplastic crus helix; hypotrophy crus helix

Helix, Darwin Notch

Definition: Small defect of the helical fold that lies at the junction of the superior and descending portions of the helix (Fig. 40b). *objective*

Comment: Defects at other points along the helix are coded as *Cleft helix*.

Helix, Darwin Tubercle

Definition: Small expansion of the helical fold at the junction of the superior and descending portions of the helix (Fig. 40a). *objective*

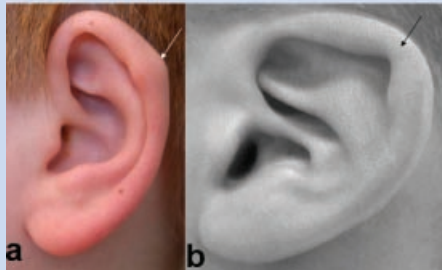


FIG. 40. Darwin tubercle (a) and Darwin notch (b).

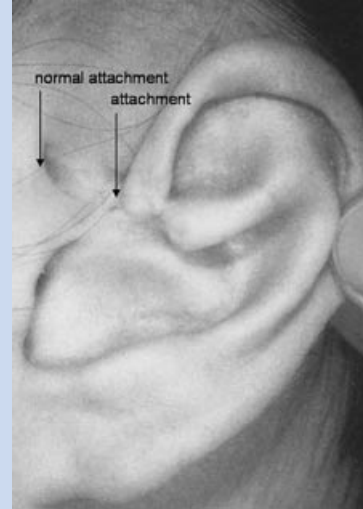


FIG. 41. Detachment of ascending part of helix (reprinted with permission from Park and Roh, 1999).

Helix, Discontinuous Ascending Root

Definition: Interruption between the ascending helix and the crus helix, allowing the ascending helix to be attached directly to the mastoid area (Fig. 41). *objective*

Comments: This is an uncommon feature.

Replaces: Helix, ascending, detachment

Synonym: Anomalous origin of ascending most of the helix.

Helix, indented: see *Helix, crimped*

Helix, notched: see *Helix, cleft*

Helix, overfolded

Definition: Excessive curling of the helix edge, whereby the free edge is parallel to the plane of the ear (Figs. 29 [example 3], 42). *subjective*

Comments: This is most often seen in the superior helix where it must be distinguished from a *Lop ear* (where the usual convexity of

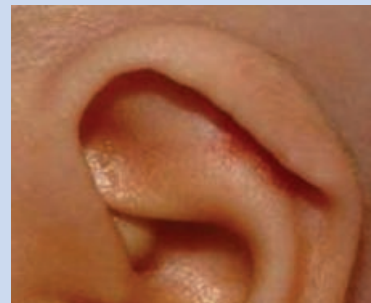

FIG. 42. Overfolded helix.

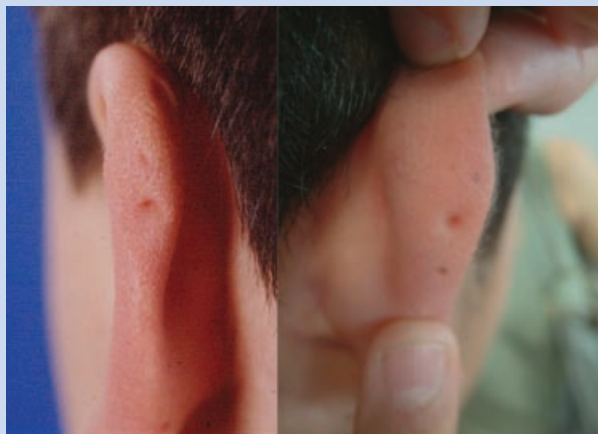

FIG. 43. Pits in posterior helix.

the posterior border of the ear is lost). Helix folding is highly variable, and the range is illustrated in Figures 29 and 30.

Helix, Posterior Pit

Definition: Permanent indentation on the posteromedial aspect of the helix that may be sharply or indistinctly delineated (Fig. 43). *objective*

Comment: They are usually linear to a narrow oval in shape and may be single or multiple [Prescott and Hennekam, 2007].

Replaces: Ear, posterior helical groove; ear, posterior helical notch

Helix, Squared Superior Portion

Definition: Flattening instead of curving or rounded superior helix, allowing the superior helix to run more horizontally than usual (Fig. 44). *subjective*

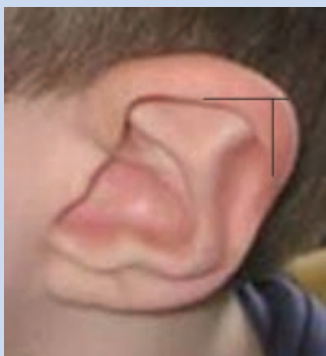


FIG. 44. Squared superior portion of helix.

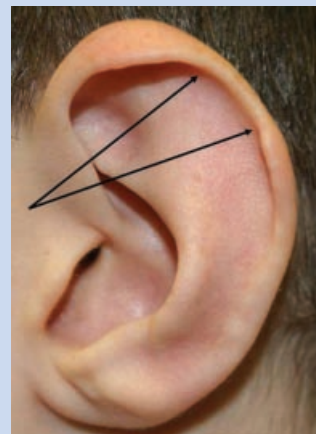


FIG. 45. Localized underdeveloped helix.

Comment: This is not to be confused with *Lop ear* or *Satyr ear* and may represent an underdevelopment of the upper third of the pinna. This is usually associated with a short ascending helix.

Helix, Underfolded

Definition: Underdevelopment of the helix that either affects the entire helix, or is localized (Fig. 45). *subjective*

Comment: Helix folding is highly variable, and the range is illustrated in Figures 29 and 30. To use this term, the affected area must be too long to be considered a *Cleft helix*. Underdevelopment of part of the helix can lead to the impression that the scaphal area is enlarged.

Replaces: Ear, dog-bite

Lobe, Absent

Definition: Absence of fleshy non-cartilaginous tissue inferior to the tragus and incisura (Figs. 46 and 47). *objective*

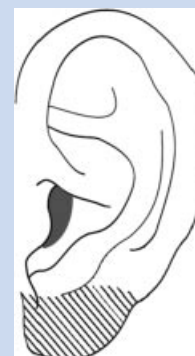

FIG. 46. Normal anatomy of the lobe.

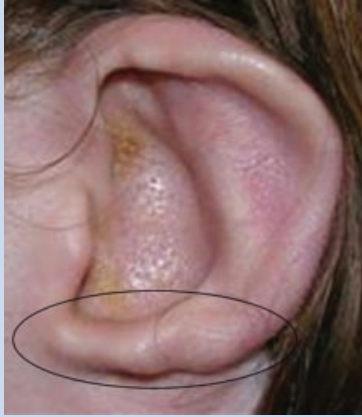

FIG. 47. Absent lobe.

Comments: See *Attached lobe* for a finding that should be distinguished from *Absent lobe*.

Lobe, Anterior Crease(s)

Definition: Sharply demarcated, typically linear and approximately horizontal, indentations in the outer surface of the ear lobe (Fig. 48). *subjective*

Comment: Shallow grooves or indentations are quite common, especially in large lobes. Ear lobe creases may arise postnatally [Chitayat et al., 1990]. *Posterior helical pits* can be a related finding but should be assessed and coded separately.

Lobe, Attached

Definition: Attachment of the lobe to the side of the face at the lowest point of the lobe without curving upward (Fig. 49). *objective*

Comment: The earlobe does not have a dependent portion.

Lobe, bifid: see *Lobe, cleft*

Lobe, Cleft

Definition: Discontinuity in the convexity of the inferior margin of the lobe (Fig. 50). *objective*

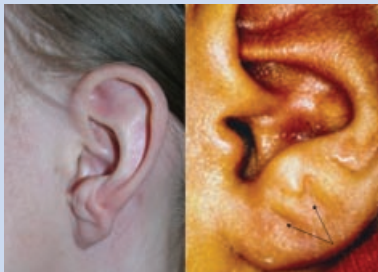

FIG. 48. Anterior creases in lobe.

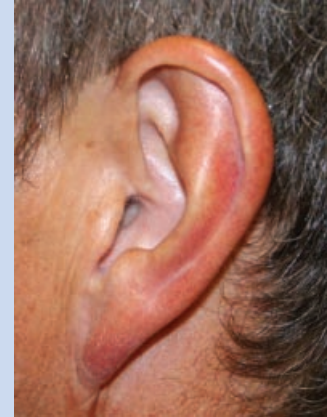

FIG. 49. Attached lobe.

Comment: The cleft is often more visible if the lobe is pulled forward or when seen from behind. Tears acquired from earrings should be distinguished.

Synonym: Bifid lobe; notched lobe

Lobe, fleshy: see *Lobe, large*

Lobe, Forward Facing

Definition: Positioning of the anterior surface of the ear lobe in a more coronal plane than the remainder of the ear (Fig. 51). *subjective*

Comment: The lobe should be viewed from the front. This feature is distinct from the situation where the entire ear is forward facing and prominent (as shown in Fig. 27). The lobe normally lies more or less in the same plane as the remainder of the ear. This feature should be distinguished from *Uplifted lobe*.

Lobe, hyperplastic: see *Lobe, large*

Lobe, hypertrophic: see *Lobe, large*

Lobe, hypoplastic: see *Lobe, small*

Lobe, hypotrophic: see *Lobe, small*

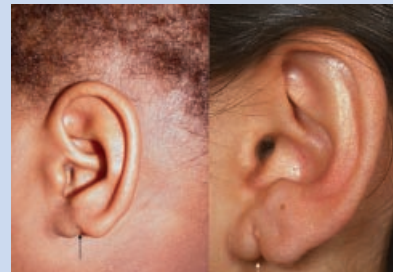

FIG. 50. Cleft lobe.

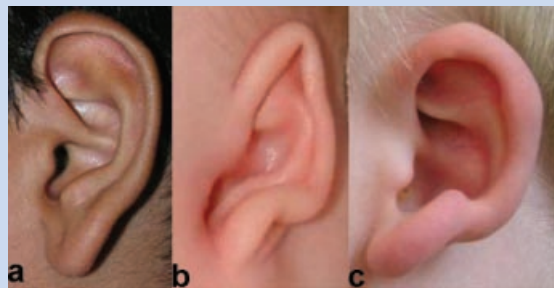


FIG. 51. Forward facing lobe. Note that in (c) the lobe is also uplifted.

Lobe, Large

Definition: Increased volume of the earlobe (Fig. 52d,e). *subjective*

Comments: All gradations in size of the earlobe may be seen from absent to clearly enlarged compared to average. This finding is highly variable, and the range is illustrated in Figure 52. Lobe size increases throughout adulthood [Ferrario et al., 1999; Itoh et al., 2001].

Replaces: Hyperplastic lobe; hypertrophic lobe; fleshy lobe

Lobe, notched: see *Lobe, cleft*

Lobe, Small

Definition: Reduced volume of the earlobe (Fig. 52a,b). *subjective*

Comments: All gradations in size of the earlobe may be seen from absent to clearly enlarged compared to average. This finding is highly variable, and the range is illustrated in Figure 52.

Replaces: Hypoplastic lobe; hypotrophic lobe

Lobe, Uplifted

Definition: Lateral surface of ear lobe faces superiorly (Fig. 53). *subjective*

Synonym: *Lobe, upturned*

Lobe, upturned: see *Lobe, uplifted*

Lop Ear

Definition: Anterior and inferior folding of the upper portion of the ear that obliterates triangular fossa and scapha (Fig. 54). *subjective*

Comments: Mild forms are limited to the superior ear, more severe forms affect the superior and posterior ear. The concha may be excessively concave. This should be distinguished from an *Overfolded helix* where the external contour of the ear is normal.

Macrotia

Definition: Median longitudinal ear length greater than 2 SD above the mean and median ear width greater than 2 SD above the mean (Fig. 24). *objective* OR

Apparently increase in length and width of the pinna. *subjective*

Comment: This is acknowledged to be a bundled term but retained here because of its usefulness in practice. Ear length is determined by the maximal distance from the superior aspect to the inferior aspect of the external ear. Normal values are available from birth to 16 years of age [Feingold and Bossert, 1974; Hall et al., 2007] and birth to 18 years of age [Farkas, 1981] specific for sex. If only length is increased the term *Long ear* should be used. Normal values for ear width are available [Farkas, 1981].

Microtia, First Degree

The definitions of microtia below follow a widely used, surgically based, classification of ear anomalies outlined by Weerda [1988]. As

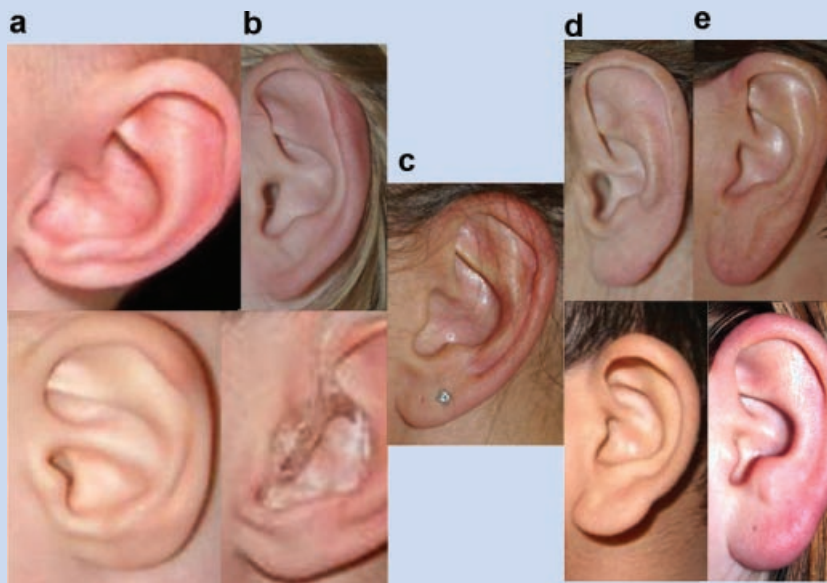


FIG. 52. Variations in volume of the earlobe. a: Very small. b: Small. c: Average. d: Large. e: Very large.

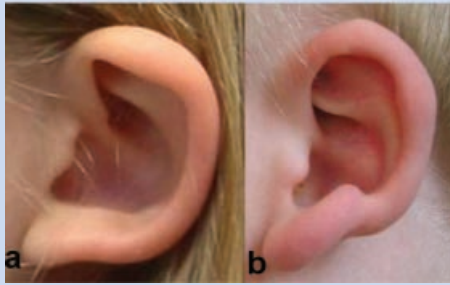


FIG. 53. Uplifted lobe; note that (b) is also forward-facing.

microtia indicates at least both decreased length and width, and in more severe forms it includes abnormal shape of structures, all forms are acknowledged to be bundled terms, but are retained here because they are well established.

Definition: Presence of all the normal ear components and the median longitudinal length more than 2 SD below the mean (Fig. 55). *objective*

Comments: See *Short ear* for a discussion of altered ear length. A better assessment of size would include both length and width (i.e., an estimate of surface area). Normal values for width and length measurements are available [Farkas, 1981; Hall et al., 2007].

Microtia, Second Degree

Definition: Median longitudinal length of the ear more than 2 SD below the mean in the presence of some, but not all, parts of the normal ear (Fig. 56). *subjective*

Replaces: Ear, grade II dysplasia; ear, cupped severe, type III; ear, cockleshell; ear, constricted helix type IV; ear, snail; ear, shell; ear, mini

Microtia, Third Degree

Definition: Presence of some auricular structures, but none of these structures conform to recognized ear components (Fig. 57). *objective*

Comments: This malformation is commonly associated with atresia of the external canal, but that anomaly should be coded separately. Complete absence of the ear should be coded as *Anotia*.

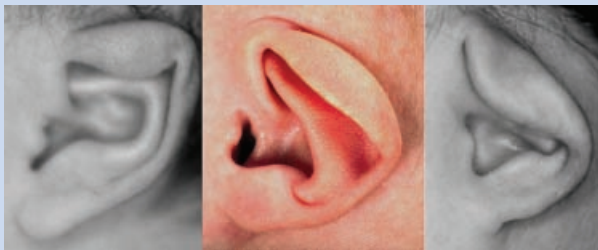

FIG. 54. Lop ear.

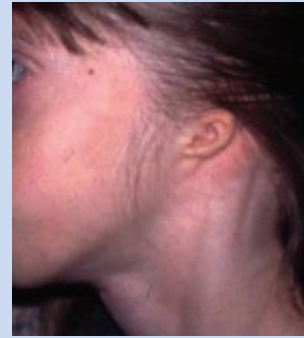


FIG. 55. Microtia, first degree.

Replaces: Ear, grade III dysplasia; ear, hypoplastic, group II; ear, peanut

Pit, Auricular

Definition: Small indentation in the lower part of the ascending helix, concha, or in the crus helix (Fig. 58). *objective*

Comment: The location of the pits is the plane of fusion of the first branchial cleft [Wood-Jones and I-Chuan, 1933].

Pit, Preauricular

Definition: Small indentation anterior to the insertion of the ear (Fig. 59). *objective*

Comment: The location of these pits is the plane of fusion of the first branchial cleft [Wood-Jones and I-Chuan, 1933].

Polyotia: see *Pretragial ectopia*

Pretragal duplication: see *Pretragial ectopia*

Pretragial Ectopia

Definition: Variably shaped, cartilage-containing tissue anterior to the external auditory meatus (Fig. 60). *objective*

Comment: These structures are frequently complex and should be distinguished from *Preauricular tags*. They may be difficult to distinguish from striated muscle hamartomas or *Tragal duplications*. *Pretragial ectopias* often appear helix-like (Fig. 61a), and in such cases may be called *Polyotia* (Fig. 61c).

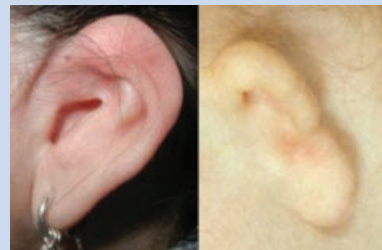


FIG. 56. Microtia, second degree.

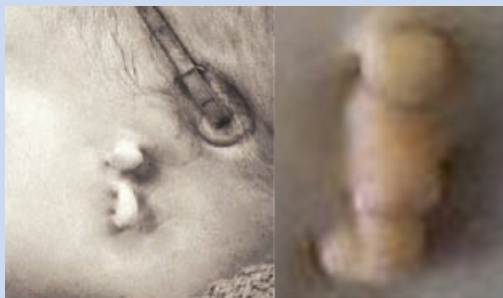

FIG. 57. Microtia, third degree.

Synonyms: Pretragal duplication; polyotia

Replaces: Accessory tragus

Quelprud Nodule

Definition: Small cartilaginous prominence on the posterior concha (Fig. 61). *objective*

Comments: This is best visualized when the lobe is tilted anteriorly.

Question Mark Ear

Definition: Cleft between the helix and the lobe (Fig. 62). *subjective*

Comments: Relatively few cases have been reported [Priolo et al., 2000]. Variation from a small notch to complete separation of the helix from the lobe is noted, there may be unilateral or bilateral involvement. The lobe is relatively laterally recessed compared to the upper portion of the ear and the scapha may be absent. This is distinct from a **Cleft helix** where the cleft is within the helix.

Synonym: Cosman ear; constricted ear

Satyr Ear

Definition: Sharp pointed superior portion of the ear, with variable overfolding of the helix (Fig. 63). *subjective*

Comments: The satyr ear appears to have an abnormally small upper-lateral portion. More extensive underdevelopment continuing down to and including the lobe produces a more extreme anomaly that, unfortunately, has been called Devil ear.

Replaces: Ear, devil

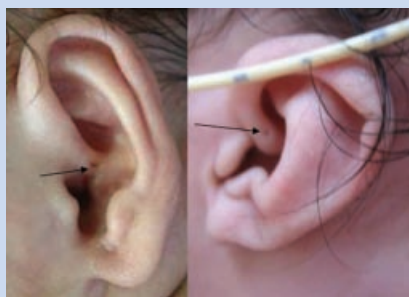

FIG. 58. Auricular pits.

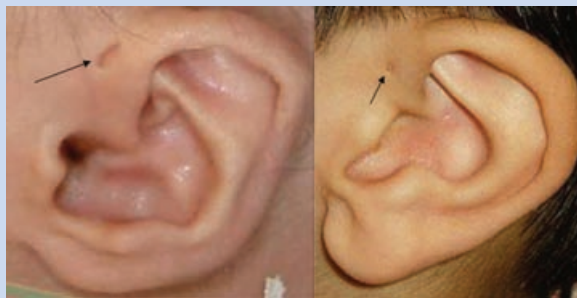

FIG. 59. Preauricular pits.

Shell Ear

Definition: Absence of the superior antihelical crus, and broadening of the inferior antihelical crus, which runs more horizontally with a sharper “take-off” from the helix than usual (Fig. 64). *subjective*

Comments: This is a bundled term, consisting of absence of the superior antihelical crus, broad inferior antihelical crus and abnormal orientation of the antihelix. As the term is much used in practice it is kept. In addition, the helix may show variable abnormalities of folding. The crus helix may be more protruding and extend further across the concha than usual.

Stahl Ear

Definition: Third crus arising at or above the normal bifurcation of the antihelix (Fig. 65). *objective*

Comments: The helix is often poorly formed. Four types have been recognized in the surgical literature [Yamada and Fukuda, 1980], but are not further delineated here.

Synonym: Antihelix, third crus; ear, additional crus

Tag, Auricular

Definition: Small protrusion within the pinna (Fig. 66). *objective*

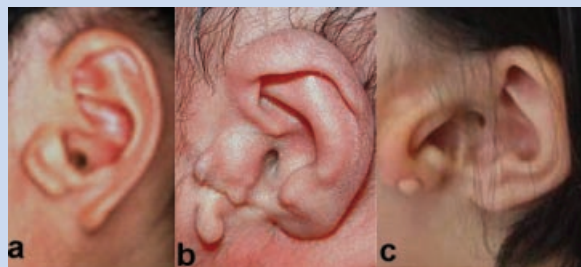


FIG. 60. Pretragal ectopias; in (a) note the resemblance of the ectopia to normal helix; in (c) there is clear duplication of hyoid components in this example of polyotia. Note the hair on part of the duplication in (b), which is typical of the infant helix but not the tragus. Note also that neither figure shows presence of a normal tragus. [(c) Courtesy of Dr Sergio B. De Sousa].

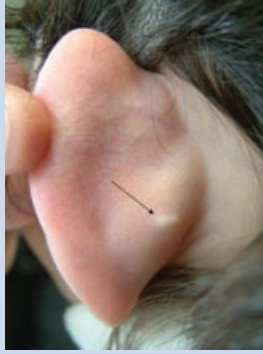

FIG. 61. Quelprud nodule.

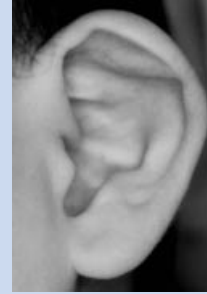

FIG. 64. Shell ear.

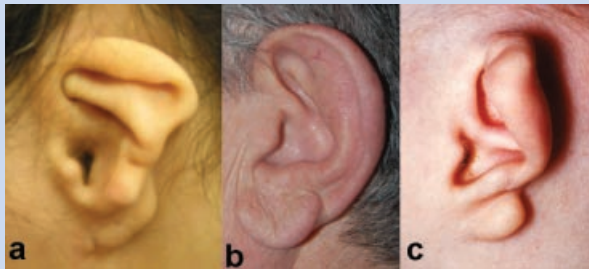


FIG. 62. Question mark ear in [a]; [b] represents a minor form. c: Courtesy of Dr Alison Stewart.

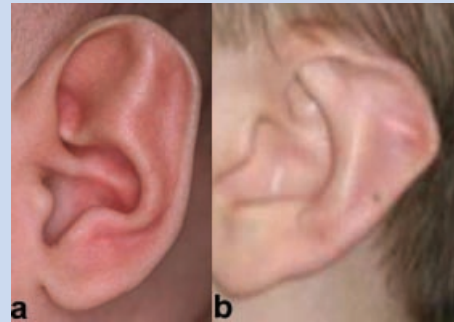


FIG. 65. Stahl ear.

Comment: The tag can be located on either side of the pinna.

Tag, Preauricular

Definition: Small non-cartilaginous protrusion anterior to the insertion of the ear (Fig. 67). *objective*

Comment: The location of these tags is the plane of fusion of the first branchial cleft [Wood-Jones and I-Chuan, 1933]. At times it can be a challenge to distinguish other pedunculated lesions in this area; specifically duplications of ear components, *Pretragal ecto-*

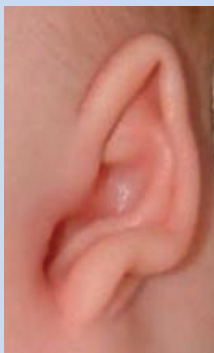


FIG. 63. Satyr ear.

pias, or a striated muscle hamartoma. Preauricular tags usually lack hair, are limited to the plane of fusion, and do not contain striated muscle.

Tragus, Absent

Definition: Lack of convexity or prominence of the contour of the ridge between the bottom of the incisura and the confluence of the ascending helix and crus helix (Figs. 68 and 69). *objective*

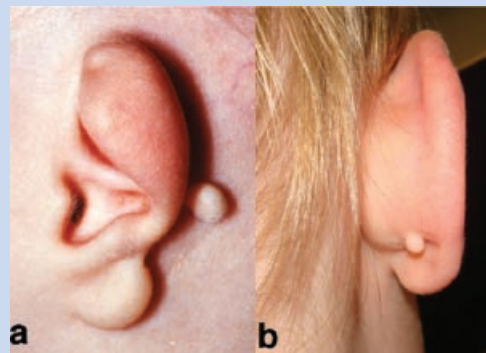
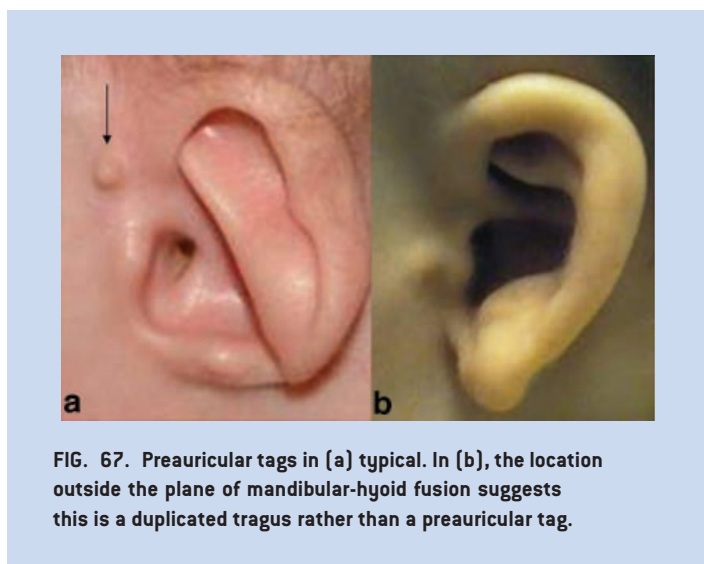


FIG. 66. Auricular tag. Both panels show a postauricular tag; [a] is in a question mark ear. a: courtesy of Dr Alison Stewart.



Comment: See Lange [1966]. This appears to be unusual in an otherwise normal ear, and is most often seen in microtia with atretic auditory meatus, but those findings should be coded separately.

Tragus, accessory: see *Tragus, duplicated*

Tragus, Bifid

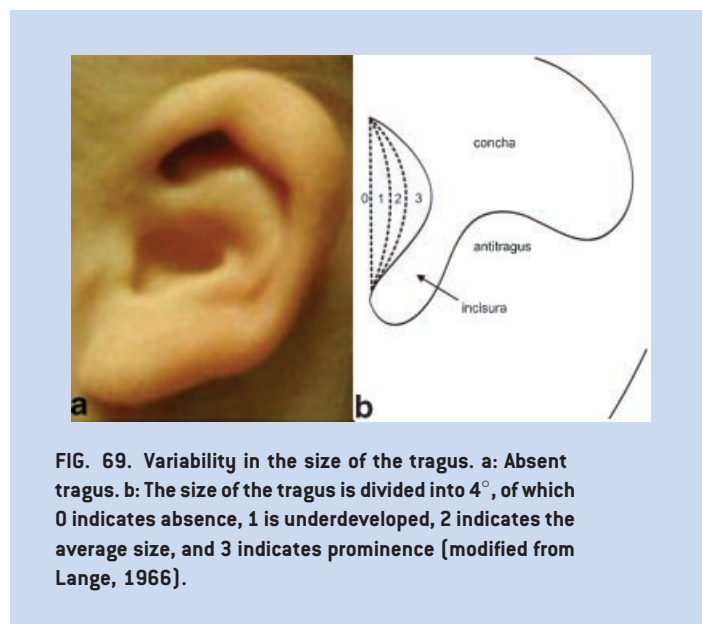
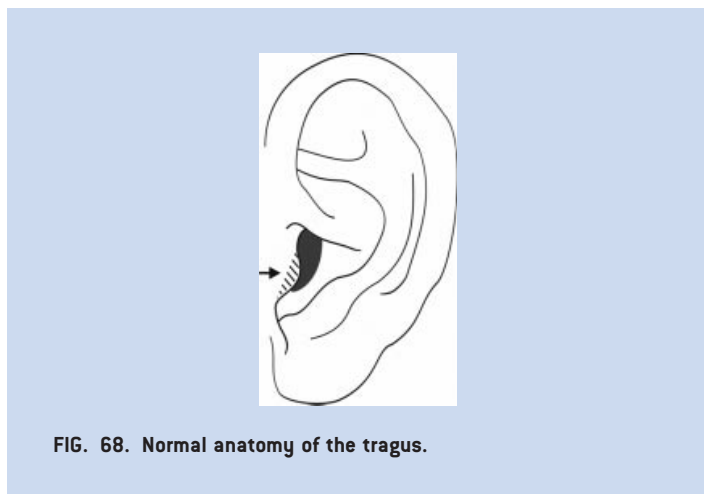
Definition: Increased height of the tragal ridge with a shallow indentation at the apex, giving the appearance of a double peak (Fig. 70). *objective*

Synonym: Tragus, notched

Tragus, Duplicated

Definition: A complete or partial duplication of the tragus; expected to lie anterior to the normal tragus (Fig. 67b). *objective*

Comment: It is unclear how often, or even whether, this feature which would represent a duplication of mandibular components, occurs. More common occurrences in this region would include preauricular tags and pretragial duplications of hyoid origin.



Synonym: Accessory tragus

Tragus, enlarged: see *Tragus prominent*

Tragus, hyperplastic: see *Tragus prominent*

Tragus, hypertrophic: see *Tragus prominent*

Tragus, hypoplastic: see *Tragus underdeveloped*

Tragus, hypotrophic: see *Tragus underdeveloped*

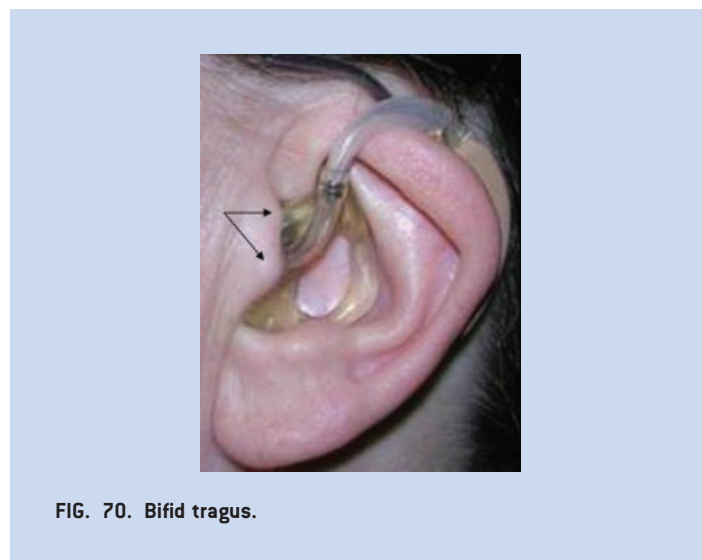
Tragus, notched: see *Tragus, bifid*

Tragus, Prominent

Definition: Increase posterolateral protrusion of the tragus (Figs. 69 [line 3] and 71d). *subjective*

Comment: This finding is highly variable, and the range is illustrated in Figures 69 and 71.

Synonym: Enlarged tragus



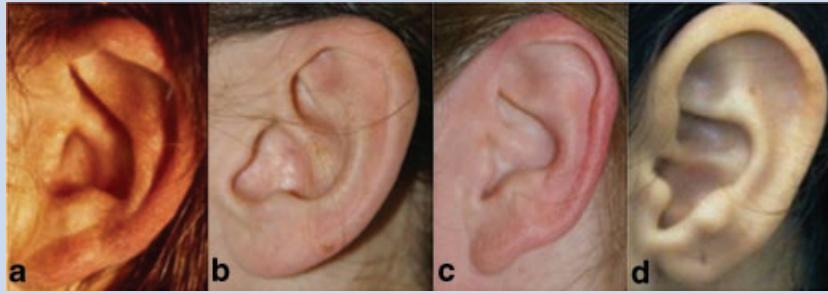


FIG. 71. Degree of prominence of the tragus. a: Very underdeveloped. b: Mildly underdeveloped. c: Average. d: Prominent.

Replaces: Hyperplastic tragus; hypertrophic tragus

Tragus, small: see *Tragus underdeveloped*

Tragus, Underdeveloped

Definition: Decreased posterolateral protrusion of the tragus (Figs. 69b [line 1] and 71a,b). *subjective*

Comment: This finding is highly variable, and the range is illustrated in Figures 69 and 71.

Synonym: Small tragus

Replaces: Hypoplastic tragus; hypotrophic tragus

ACKNOWLEDGMENTS

We are pleased to thank Astrid Sibbes, Medical Photography and Illustration, Academic Medical Centre, Amsterdam for all drawings. This paper was reviewed and edited by the co-Chairs of the International Dysmorphologic Terminology working group (Judith Allanson, Leslie G Biesecker, John Carey, and Raoul CM Hennekam). This review and editing was necessary to increase the consistency of formatting and content among the six manuscripts. While the authors of the papers are responsible for the original definitions and drafting of the papers, final responsibility for the content of each paper is shared by the authors and the four co-Chairs.

REFERENCES

- Allanson JE, Biesecker LG, Carey JC, Hennekam RCM. 2009a. Elements of morphology: Introduction. *Am J Med Genet Part A* 149A:2–5.
- Allanson JE, Cunniff C, Hoyme HE, McGaughran J, Muenke M, Neri G. 2009b. Elements of morphology: Standard terminology for the head and face. *Am J Med Genet Part A* 149A:6–28.
- Biesecker LG, Aase JM, Clericuzio C, Gurrieri F, Temple IK, Toriello H. 2009. Elements of morphology: Standard terminology for the hands and feet. *Am J Med Genet Part A* 149A:93–127.
- Carey JC, Cohen MM Jr, Curry CJR, Devriendt K, Holmes LB, Verloes A. 2009. Elements of morphology: Standard terminology for the lips, mouth, and oral region. *Am J Med Genet Part A* 149A:77–92.
- Chitayat D, Rothschild A, Ling E, Friedman JM, Couch RM, Yong SL, Baldwin VJ, Hall JG. 1990. Apparent postnatal onset of some manifestations of the Wiedemann-Beckwith syndrome. *Am J Med Genet* 36:434–439.
- Farkas LG. 1981. Anthropometry of the head and face in medicine. New York: Elsevier.
- Feingold M, Bossert WH. 1974. Normal values for selected physical parameters: An aid to syndrome delineation. *BDOAS X* 1–15.
- Ferrario VF, Sforza C, Ciusa V, Serrao G, Tartaglia GM. 1999. Morphometry of the normal ear: A cross-sectional study from adolescence to mid-adulthood. *J Craniofac Genet Dev Biol* 19:226–233.
- Hall BD, Graham JM Jr, Cassidy SB, Opitz JM. 2009. Elements of morphology: Standard terminology for the periorbital region. *Am J Med Genet Part A* 149A:29–39.
- Hall JG, Allanson JE, Gripp KW, Slavotinek AM. 2007. Handbook of Physical Measurements, 2nd edition. New York: Oxford University Press.
- Hennekam RCM, Cormier-Daire V, Hall J, Méhes K, Patton M, Stevenson R. 2009. Elements of morphology: Standard terminology for the nose and philtrum. *Am J Med Genet Part A* 149A:61–76.
- Hirose T, Tomono T, Matsuo K, Katohda S, Takahashi N, Iwasawa M, Satoh R. 1985. Cryptotia: Our classification and treatment. *Br J Plast Surg* 38:352–360.
- Hunter AGW, Yotsuyanagi T. 2005. The external ear: More attention to detail may aid syndrome diagnosis and contribute answers to embryological questions. *Am J Med Genet Part A* 135A:237–250.
- Itoh I, Ikeda M, Sueno K, Sugiura M, Suzuki S, Kida A. 2001. Anthropometric study on normal human auricle in Japan. *Nippon Jibiinkoka Gakkai Kaiho* 104:165–174.
- Lange G. 1966. Familieuntersuchungen über die Erbllichkeit metrischer und morphologischer Merkmale des ausserer Ohres. *Z Morphol Anthropol* 57:111–187.
- Park C, Roh TS. 1999. Congenital upper auricular detachment. *Plast Reconstr Surg* 104:488–490.
- Prescott TE, Hennekam RC. 2007. Posterior helical pits. *Eur J Med Genet* 50:159–161.
- Priolo M, Lerone M, Rosaia L, Calcagno EP, Sadeghi AK, Ghezzi F, Ravazzolo R, Silengo M. 2000. Question mark ears, temporo-mandibular joint malformation and hypotonia: Auriculo-condylar syndrome or a distinct entity? *Clin Dysmorphol* 9:277–280.
- Weerda H. 1988. Classification of congenital deformities of the auricle. *Facial Plastic Surg* 5:385–388.
- Wood-Jones F, I-Chuan W. 1933. The development of the external ear. *J Anat* 68:525–533.
- Yamada A, Fukuda O. 1980. Evaluation of Stahl's ear, third crus of antihelix. *Ann Plast Surg* 4:511–515.