

Elements of Morphology: Standard Terminology for the Nose and Philtrum

Raoul C.M. Hennekam,^{1,2*} Valerie Cormier-Daire,³ Judith G. Hall,⁴ Károly Méhes,⁵ Michael Patton,⁶ and Roger E. Stevenson⁷

¹Clinical and Molecular Genetics Unit, Institute of Child Health, Great Ormond Street Hospital for Children, UCL, London, UK

²Department of Pediatrics, Academic Medical Center, UVA, Amsterdam, The Netherlands

³Department of Medical Genetics and INSERM U781, Hopital Necker, Paris, France

⁴Department of Paediatrics, BC's Children's Hospital, Vancouver, British Columbia, Canada

⁵Department of Medical Genetics and Child Development, University of Pecs, Pecs, Hungary

⁶Medical Genetics, St Georges Hospital Medical School, London, UK

⁷Greenwood Genetic Center, Greenwood, South Carolina

Received 6 September 2008; Accepted 15 October 2008

An international group of clinicians working in the field of dysmorphology has initiated the standardization of terms used to describe human morphology. The goals are to standardize these terms and reach consensus regarding their definitions. In this way, we will increase the utility of descriptions of the human phenotype and facilitate reliable comparisons of findings among patients. Discussions with other workers in dysmorphology and related fields, such as developmental biology and molecular genetics, will become more precise. Here we introduce the anatomy of the nose and philtrum, and define and illustrate the terms that describe the major characteristics of these body regions. © 2009 Wiley-Liss, Inc.

Key words: nomenclature; definitions; nose; philtrum; anatomy; anthropometry; morphology; dysmorphology

INTRODUCTION

General

This paper is part of a series of six papers defining the morphology of regions of the human body [Allanson et al., 2009b; Biesecker et al., 2009; Carey et al., 2009; Hall et al., 2009; Hunter et al., 2009]. The series is accompanied by an introductory paper describing general aspects of this study [Allanson et al., 2009a]. The reader is encouraged to consult the introduction when using the definitions.

Anatomy of the Nose

The normal anatomy of the nose is shown in Figures 1–3: the various terms used for nasal structures and dimensions (Fig. 1), the cartilaginous components of the nose and terms for regions (Fig. 2), and in Figure 3 the cross section is shown.

Some anatomical landmarks deserve specific mention as these are not always used with standard meaning.

Nasal root: the most depressed, superior part of the nose along the nasal ridge.

How to Cite this Article:

Hennekam RCM, Cormier-Daire V, Hall J, Méhes K, Patton M, Stevenson R. 2009. Elements of morphology: Standard terminology for the Nose and philtrum. *Am J Med Genet Part A* 149A:61–76.

Nasion: the midline point just superior to the nasal root overlying the naso-frontal suture.

Nasal bridge: A saddle-shaped area that includes the nasal root and the lateral aspects of the nose. It lies between the glabella and the inferior boundary of the nasal bone, and extends laterally to the inner canthi.

Nasal ridge: the midline prominence of the nose, extending from the nasal root to the tip (also called the dorsum of the nose).

Nasal base: an imaginary line between the most lateral points of the external inferior attachments of the alae nasi to the face.

Nasal tip: the junction of the inferior margin of the nasal ridge and the columella. Commonly, it is the part of the nose furthest from the plane of the face. In rare circumstances, such as markedly prominent and convex nasal profiles, other parts of the ridge may be further removed from the facial plane.

Ala: the tissue comprising the lateral boundary of the nose, inferiorly, surrounding the naris.

*Correspondence to:

Raoul C.M. Hennekam, Clinical and Molecular Genetics Unit, Institute of Child Health, 30 Guilford Street, London WC1N 1EH, UK.

E-mail: r.hennekam@ich.ucl.ac.uk

Published online 16 January 2009 in Wiley InterScience

(www.interscience.wiley.com)

DOI 10.1002/ajmg.a.32600

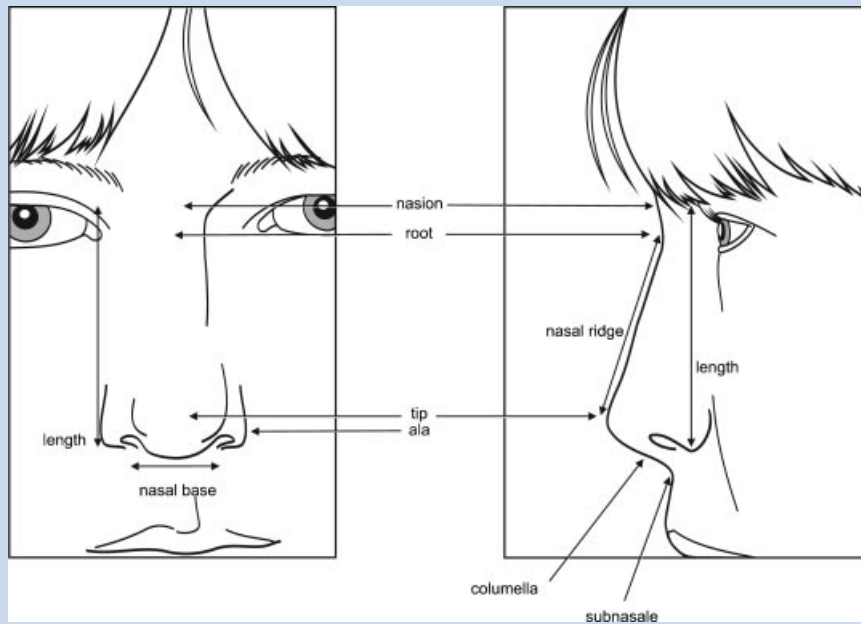


FIG. 1. Anatomy of the nose: Landmarks and distances.

Columella: the tissue that links the nasal tip to the nasal base, and separates the nares. It is the inferior margin of the nasal septum.

Measurements of the Nose

Measurements of the nose are possible using sliding calipers. The reliability of measurements using a tape measure is poor. Furthermore, the actual position of several of the landmarks may

preclude accurate measurement. For example, if the nasal tip overhangs the upper lip, the position of subnasale is difficult to define [Hall et al., 2007]. Nasal length and width are the most common measurements taken in practice. A short description of how to measure each dimension is provided as the various terms are defined.

Growth of the nose does not end at puberty: the nose continues to increase in size with age. There are no normal standards for nasal size in adulthood.

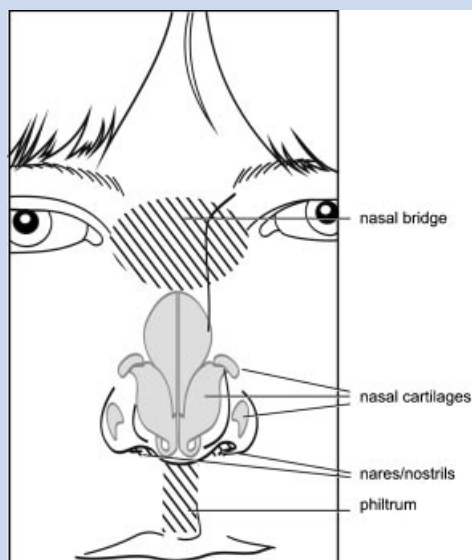


FIG. 2. Anatomy of the nose: Areas.

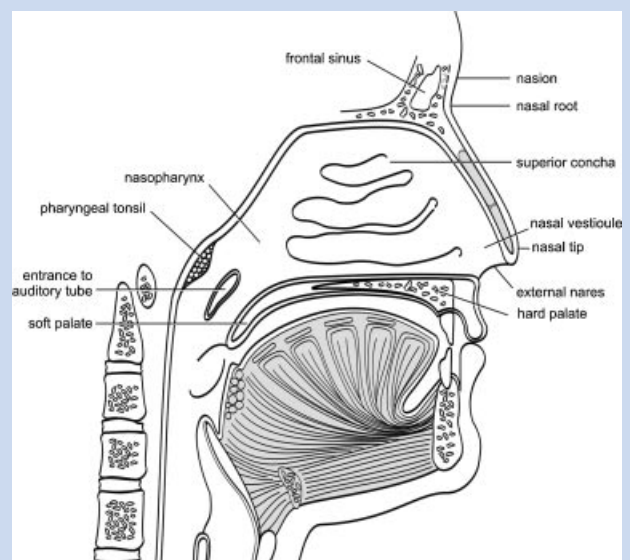


FIG. 3. Anatomy of the nose: Cross section.

The reader is referred to the *Handbook of Normal Physical Measurements* [Hall et al., 2007] for detailed descriptions of measurement techniques, additional nasal measurements not described here, and growth standards. Most are available for Caucasians of Northern European extraction only, and similar standards for other ethnicities are urgently needed.

Anatomical Variation

Anomalies of the nose may be classified into quantitative traits and qualitative features:

1. Variations in length: long; short
2. Variations in width: wide nose; narrow nose, broad nasal base; narrow nasal base; broad nasal tip; narrow nasal tip; wide nasal ridge; narrow nasal ridge; wide nasal bridge; narrow nasal bridge; broad columella.
3. Variations in length and width: prominent nose; absent nasal cartilage; absent nose.
4. Variations in shape or position: depressed nasal bridge; depressed nasal ridge; depressed nasal tip; bulbous nose; bifid nasal tip; bifid nose; overhanging nasal tip; deviated nasal tip; fullness of paranasal tissue; prominent nasal bridge; convex nasal ridge; concave nasal ridge; low insertion of the columella; low hanging columella; short columella; high insertion of the columella; thick ala nasi; underdeveloped ala nasi; cleft ala nasi; enlarged naris; narrow naris; single naris; proboscis; supernumerary naris; anteverted nares.

The various features are listed alphabetically. If a feature is indicated in ***bold-italics***, the feature is listed and a definition is available. This can be in the present or one of the accompanying papers. The terms are alphabetized based on the physical feature, not the modifier.

The appearance of facial morphology varies considerably with the position of the observer and observed person, and facial movements. In assessing morphology, the head of the observed person should be held in the Frankfurt horizontal, with the facial and neck muscles relaxed, eyes open, lips making gentle contact, and a neutral facial expression. The face of the observer should be at the same height as the face of the observed person.

DEFINITIONS

Ala Nasi, Cleft

Definition: Notch in the margin of the ala nasi (Fig. 4). *subjective*

Comments: The alae nasi are the lateral portions of the nose or the wings of the nostrils, which partly encircle the nostrils (nares). They are usually about the width of the columella, but vary greatly depending on the shape of the nostril. Note that individuals may be described as having a cleft ala nasi, but have a severely ***Underdeveloped ala nasi***. In an underdeveloped ala the continuity of the tissue encircling the nostril is undisturbed while in a cleft it is disrupted. The term coloboma has been replaced because a coloboma is a remnant of a physiologically occurring discontinuity of tissue; the alae nasi do not have such a discontinuity.

Synonym: Ala nasi, notched

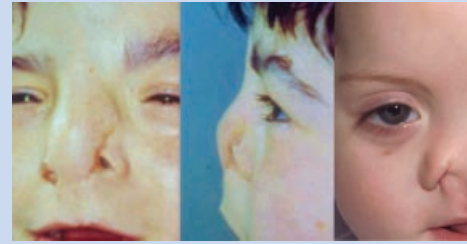

FIG. 4. Cleft alae nasi. Please note the difference with an underdeveloped ala nasi in Figure 6. Left hand and middle panel courtesy of Dr. Jenneke van den Ende and Dr. Yolande van Bever.

Replaces: Ala nasi, coloboma

Ala nasi, coloboma: see ***Ala nasi, cleft***

Ala nasi, hypoplastic: see ***Ala nasi, underdeveloped***

Ala nasi, notched: see ***Ala nasi, cleft***

Ala Nasi, Thick

Definition: Increase in bulk of the ala nasi (Fig. 5). *subjective*

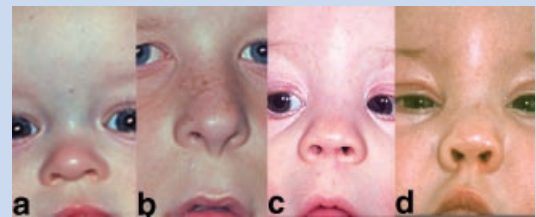


FIG. 5. Variation in thickening of the alae nasi: a, normal, b, mildly thickened, c, more expressed thickening, d, marked thickening. Note that also the extension of the alae towards the philtral ridges increases with increasing alar thickness.

Ala Nasi, Underdeveloped

Definition: Thinned, deficient, or excessively arched ala (Fig. 6). *subjective*

Comments: The alae nasi are the lateral portions of the nose or the wings of the nostrils, which partly encircle the nostrils (nares). They are usually about the width of the columella, but vary greatly depending on the shape of the nostril. Note that individuals may be described as having a ***Cleft ala nasi***, but have a severely underdeveloped ala nasi. In an underdeveloped ala the continuity of the tissue encircling the nostril is undisturbed while in a cleft it is disrupted.

Replaces: Ala nasi, hypoplastic

Columella below alae nasi: see ***Columella, low hanging***

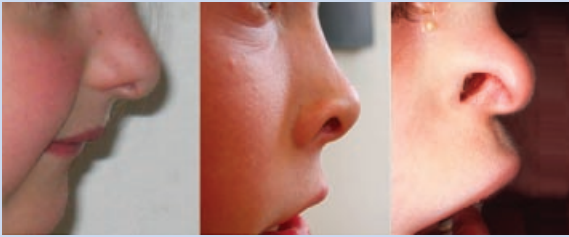


FIG. 6. Underdeveloped alae nasi. This feature is best assessed in a side view.

Columella, Broad

Definition: Increased width of the columella (Fig. 7). *subjective*

Comments: The columella should be viewed from below. This feature should be distinguished from *Narrow nares* although both may be present in a given individual.

Synonym: Columella, wide




FIG. 7. Broad columella. Please note that in the right panel not only the columella is broad but there are also soft tissue swellings on each side of the columella.

Columella, High Insertion

Definition: Insertion of the posterior columella superior to the nasal base (Fig. 8). *objective*

Columella, low: see *Columella, low hanging*

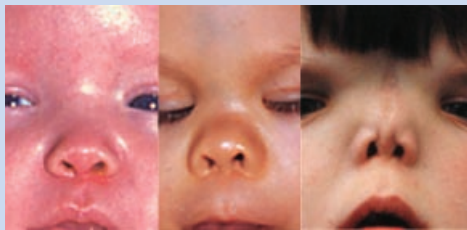

FIG. 8. High insertion of the columella. Note that it is usually impossible to determine whether the alar attachment to the face is lower than usual or the columella higher.

Columella, Low Hanging

Definition: Columella extending inferior to the level of the nasal base, when viewed from the side (Fig. 9). *subjective*

Comments: This feature may occur with or without low insertion of the columella. It may be confused with an *Overhanging nasal tip* which may co-occur but the two should be assessed and coded separately.

Synonym: Columella below alae nasi; Columella, low

Replaces: Columella, rounded

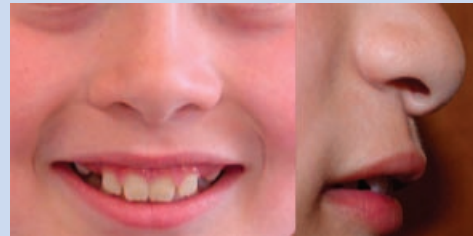

FIG. 9. Low hanging columella. Please note in the left panel that there is also a low insertion of the columella.

Columella, Low Insertion

Definition: Insertion of the posterior columella below the nasal base (Fig. 10). *objective*

Comments: This feature is different from a convex *Low hanging columella* that has a normal insertion. It may be associated with a *Short philtrum*, but this should be assessed and coded separately. A low insertion is best appreciated when viewed from the side.

Columella, rounded: see *Columella, low hanging*

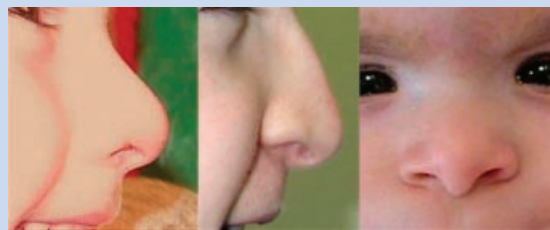


FIG. 10. Low insertion of the columella. Please note the difficulty to discern this from a low hanging columella in the frontal view in the right panel.

Columella, Short

Definition: Reduced distance from the anterior border of the nares to the subnasale (Fig. 11). *subjective*

Comment: This is often accompanied by a *Depressed nasal tip* but this should be assessed and coded separately. The term "Absent columella" has been deleted because a columella is thought to always be present, except in *Single nares* and *Proboscis*.

Columella, wide: see *Columella, broad*

Laterally built up nose: see *Paranasal tissue, fullness*

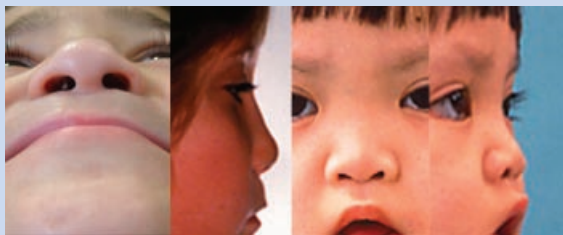

FIG. 11. Short columella. Note that the two panels on the right show the same child, but only in the most right-hand panel the feature is clear.

Nares, Anteverted

Definition: Anteriorly-facing nostrils viewed with the head in the Frankfurt horizontal and the eyes of the observer level with the eyes of the subject (Fig. 12). *subjective*

Comments: The tip of the nose is upturned and is positioned superiorly to the nasal base, allowing the nares to be easily visualized from the front. With maturation and growth of the nasal ridge and tip, the nares usually become more downwardly directed.

Synonym: Nasal tip, upturned

Replaces: Pug nose

Naris, broad: see *Naris, enlarged*

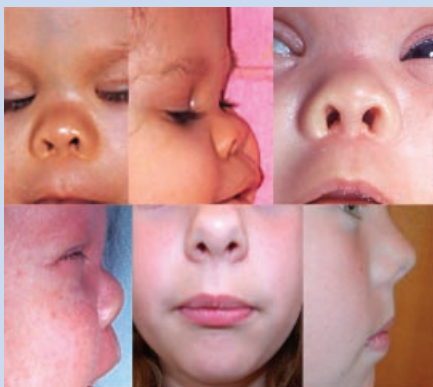

FIG. 12. Anteverted nares.

Naris, Enlarged

Definition: Increased aperture of the nostril (Fig. 13). *subjective*

Comments: The nostrils or nares are typically symmetric, wide openings. They should be assessed with the face at rest to avoid the effect of flared alae nasi that occurs with distress. Note that the nares change with age, from rounded in infancy to elongated at a later age.

Synonym: Naris, broad

Naris, flared: The term “flared naris” is not defined here as it is a functional characteristic (see *Naris, enlarged*)

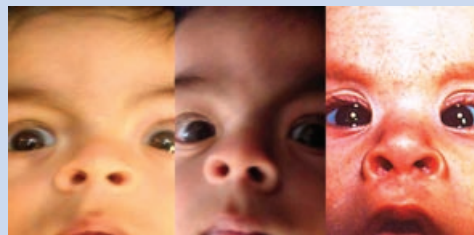


FIG. 13. Enlarged nares. Note subtlety of the enlargement in the left panel. The feature should be present with the face in a neutral position.

Naris, Narrow

Definition: Slender, slit-like aperture of the nostril (Fig. 14). *subjective*

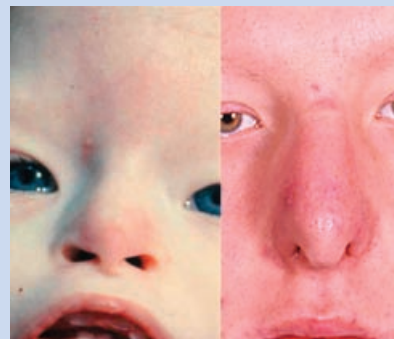


FIG. 14. Narrow nares. Note that the longest axis of the nares has a different direction in the two panels.

Comment: The shape of the nostrils has been classified into four main types by Paul Topinard (1830–1911) (Fig. 15). This classification is not in general use.

Synonym: Naris, thin; Naris, slit-like

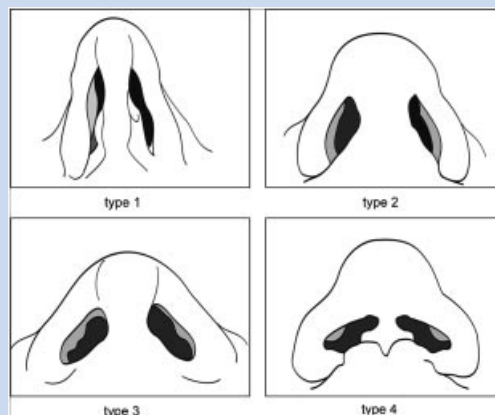


FIG. 15. Topinard classification of nostril shape. Type 2 is the most common type in the general population.

Naris, Single

Definition: One external opening of the nose (Fig. 16). *objective*

Comments: The single opening may occur in the midline or it can occur on one side, that is, it can be symmetric or asymmetric. Although the columella is invariably absent, this is implicit and does not need to be separately specified.

Naris, slit-like: see *Naris, narrow*

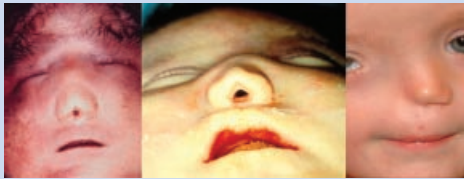

FIG. 16. Single naris. Note positioning in the midline in left and middle panel, and on the left side in right panel. The patient in the right panel has a heminasal agenesis.

Naris, Supernumerary

Definition: More than two nares (Fig. 17). *objective*

Naris, thin: see *Naris, narrow*

Nasal base, broad: see *Nasal base, wide*

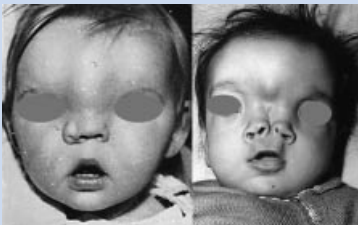

FIG. 17. Supernumerary nares. The right panel shows a completely duplicated nose.

Nasal Base, Narrow

Definition: Decreased distance between the attachments of the alae nasi to the face (Fig. 18). *subjective*

Comment: There is a marked difference in width of the nasal base depending on ethnic background

Nasal Base, Wide

Definition: Increased distance between the attachments of the alae nasi to the face (Fig. 19). *subjective*

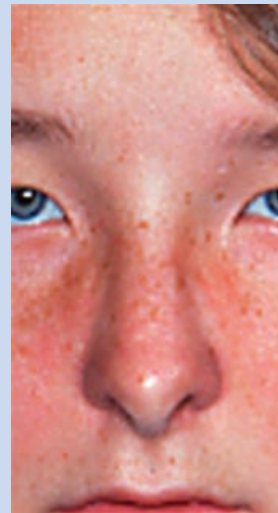


FIG. 18. Narrow nasal base.

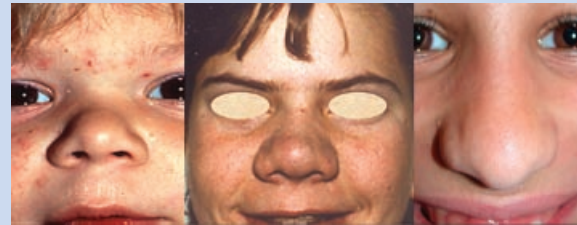

FIG. 19. Wide nasal base. Please note that in the right panel the picture is taken slightly from above allowing the overhanging nasal tip to obscure almost completely the broad nasal base, so this would not be a useful figure to show this feature.

Comment: There is a marked difference in width of the nasal base depending on ethnic background

Synonym: Nasal base, broad

Nasal bridge, broad: see *Nasal bridge, wide*

Nasal bridge, decreased protrusion: see *Nasal bridge depressed*

Nasal Bridge, Depressed

Definition: Posterior positioning of the nasal root in relation to the overall facial profile for age (Fig. 20). *subjective*

Comments: The adjective “depressed” here does not indicate an active process but a status. A depressed nasal bridge can occur irrespective of the width of the nasal bridge, and the width should be assessed independently. In infancy, the nasal bridge is relatively more posterior than in the older person. The term depressed nasal

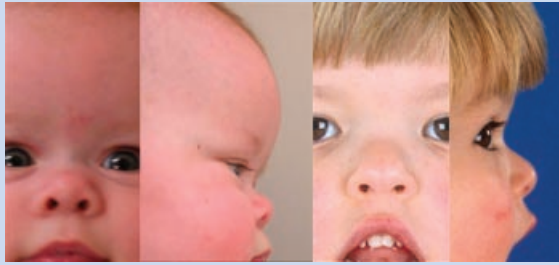


FIG. 20. Depressed nasal bridge. Although the nasal bridge in infants and toddlers is still at a more posterior position compared to older children and adults, the bridge can be tagged here depressed as it is more posterior compared to peers.

bridge should only be used when the bridge is more posterior than is typical for age and ethnic background.

Synonym: Protrusion of the nasal bridge, decreased; Nasal bridge, retruded; Nasal bridge, recessed; Nasal root, depressed; Nasal root, recessed

Replaces: Snub nose; Nasal bridge, low; Nasal bridge, flat

Nasal bridge, flat: see *Nasal bridge, depressed*

Nasal bridge, high: see *Nasal bridge, prominent*

Nasal bridge, low: see *Nasal bridge, depressed*

Nasal Bridge, Narrow

Definition: Decreased width of the bony bridge of the nose (Fig. 21). *subjective*

Comments: The narrowness may be accompanied by a sharp, keel-shaped appearance. The nasal bridge may narrow with age.

Synonym: Nasal bridge, thin

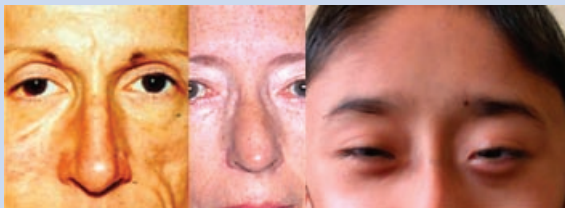


FIG. 21. Narrow nasal bridge. Sometimes just the nasal bridge is narrow, like in the middle panel, and sometimes both nasal bridge and ridge are narrow, like in the right panel.

Nasal Bridge, Prominent

Definition: Anterior positioning of the nasal root in comparison to the usual positioning for age (Fig. 22). *subjective*

Comments: A prominent nasal bridge can occur irrespective of the width of the nasal bridge, and the width should be assessed

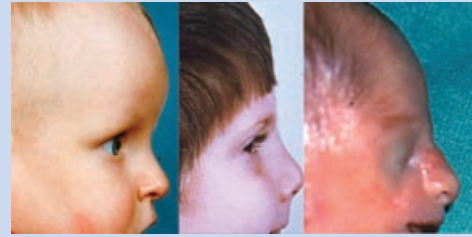

FIG. 22. Prominent nasal bridge. It can be difficult to determine whether in addition the eyes are deeply set.

separately. The nasal bridge becomes more prominent with age. Although the nasal root may be anteriorly placed without increasing the space between the eyes, prominence of the nasal bridge may be accompanied by *Telecanthus* or ocular *Hypertelorism* [Hall et al., 2009]. If such findings are present these should be coded separately. *Deep-set eyes* [Hall et al., 2009] may lead to the impression of a prominent nasal bridge, but this finding should be coded separately.

Synonym: Nasal bridge, high

Nasal bridge, recessed: see *Nasal bridge, depressed*

Nasal bridge, retruded: see *Nasal bridge, depressed*

Nasal bridge, thin: see *Nasal bridge, narrow*

Nasal Bridge, Wide

Definition: Increased breadth of the nasal bridge (Fig. 23). *subjective*

Comments: Care should be taken to distinguish between increased width of bone and *Fullness of paranasal tissue*. A wide nasal bridge should be distinguished from *Telecanthus* and *Hypertelorism* [Hall et al., 2009] (Fig. 2). A wide nasal bridge can be either prominent or depressed, which should be coded separately.

Synonym: Nasal bridge, broad

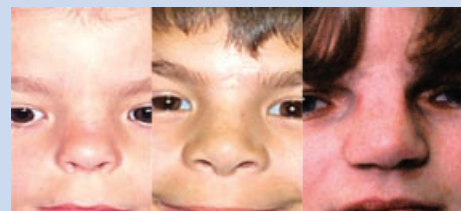

FIG. 23. Wide nasal bridge.

Nasal Cartilage, Absent

Definition: Lack of a palpable nasal cartilage (Fig. 24). *objective*

Comments: This feature may be accompanied by a deficiency of the nasal bone. Absence of the nasal cartilage may lead to a *Depressed nasal tip*, which should be coded separately.

Nasal cartilages, separated: see *Nasal tip, bifid*

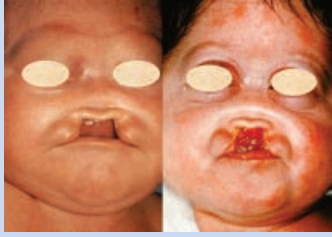

FIG. 24. Absent nasal cartilage. This usually but not always goes along with holoprosencephaly.

Nasal ridge, broad: see *Nasal ridge, wide*

Nasal Ridge, Concave

Definition: Nasal ridge curving posteriorly to an imaginary line that connects the nasal root and tip (Fig. 25). *objective*

Comments: Note the difference from *Depressed nasal bridge*.

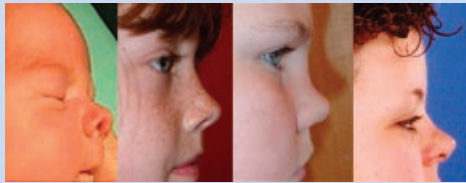

FIG. 25. Concave nasal ridge. Please note the concave nasal ridge goes along with anteverting nares in the left two panels but not in the right two.

Replaces: Saddle nose; Ski jump nose

Nasal Ridge, Convex

Definition: Nasal ridge curving anteriorly to an imaginary line that connects the nasal root and tip (Fig. 26). *objective*

Replaces: Nose, beaked; Nose, hooked

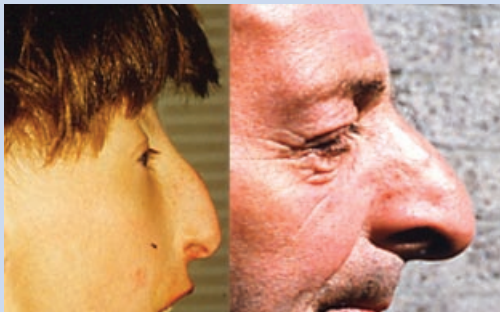

FIG. 26. Convex nasal profile. The nose appears often also prominent, and the columella low.

Nasal Ridge, Depressed

Definition: Posteriorly-placed nasal ridge (Fig. 27). *subjective*

Comments: The adjective “depressed” here does not indicate an active process but a status. The feature should be assessed in a profile view. This finding is typically associated with a *Short columella*, but this should be assessed separately.

Synonym: Nasal ridge, retruded; Nasal ridge, recessed

Replaces: Nose, flat

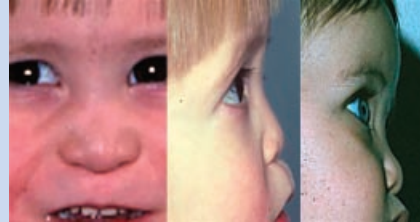

FIG. 27. Depressed nasal ridge. Please note that in addition the nasal bridge is flattened in each of the examples.

Nasal Ridge, Narrow

Definition: Decreased width of the nasal ridge (Fig. 28). *subjective*

Comments: A narrow nasal ridge may appear sharp, but this is not obligate. There is no objective measure of width.

Replaces: Nose, pinched

Nasal ridge, recessed: see *Nasal ridge, depressed*

Nasal ridge, retruded: see *Nasal ridge, depressed*

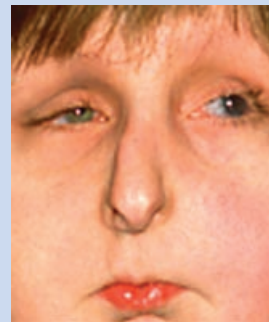


FIG. 28. Narrow nasal ridge. Note that there is also a narrow nasal bridge and narrow nasal base, so the nose in total is narrow.

Nasal Ridge, Wide

Definition: Increased width of the nasal ridge (Fig. 29). *subjective*

Comments: This feature should be assessed in a frontal view. There is no objective measure of width. This may give the impression of a *Depressed nasal ridge*, but this should be assessed in profile and separately coded. Marked widening of the nasal ridge may be difficult to distinguish from a *Bifid nose*.

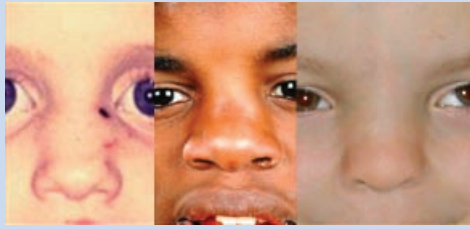

FIG. 29. Wide nasal ridge. Note widening over the base, ridge and bridge in all three examples.

Synonym: Nasal ridge, broad

Nasal root, depressed: see *Nasal bridge, depressed*

Nasal root, recessed: see *Nasal bridge, depressed*

Nasal Tip, Bifid

Definition: Visually assessable vertical indentation, cleft, or depression of the nasal tip (Fig. 30). *subjective*

Comments: Note that this definition does not require that the tip is wide. The division should be visible at inspection and not just palpable, as a palpable bifid tip is usual. If a bifid nasal tip goes along with an indentation or cleft of the nasal ridge and the nasal bridge, this should be coded as *Bifid nose*.

Replaces: Nasal cartilages, separated

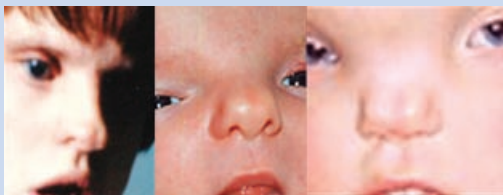

FIG. 30. Bifid nasal tip. Please note that in the middle and right panel the nasal bridge, ridge and base are also broad.

Nasal Tip, Broad

Definition: Increase in width of the nasal tip (Fig. 31). *subjective*

Comments: Nasal tip width is assessed at the anterior junction of the alae and the tip. This is easier in persons with a somewhat squared shape of the nasal tip. This may be best viewed from the

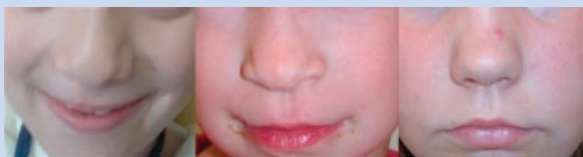


FIG. 31. Broad nasal tip.

inferior aspect of the nose. No objective measures are available. See *Bulbous nose* for a related term.

Synonym: Nasal tip, wide

Nasal tip, bulbous: see *Nose, bulbous*

Nasal Tip, Depressed

Definition: Decreased distance from the nasal tip to the nasal base (Fig. 32). *subjective*

Comments: This often accompanies a *Short columella*, *Overhanging nasal tip*, and *Underdeveloped nasal tip*, but these should be assessed and coded separately.

Synonym: Nasal tip, retruded; Nasal tip, recessed

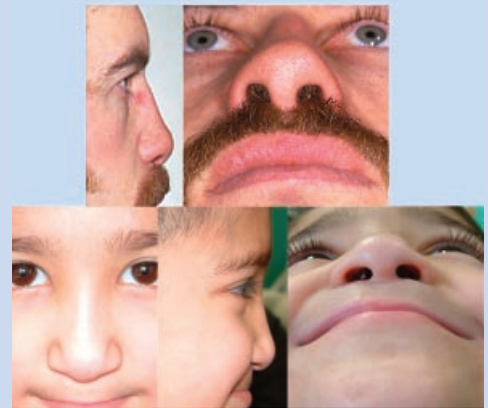

FIG. 32. Depressed nasal tip. Please note that in the three pictures from a single patient in the lower panels, the right panel shows this best, and also note the presence of a short columella in the lower right panel and less in upper right panel.

Nasal Tip, Deviated

Definition: Nasal tip positioned to one side of the midline (Fig. 33). *subjective*

Comments: There is no specific minimal angle before the tip can be determined to be deviated. The assessment of a mild degree of deviation is highly dependant on the experience of the observer. A deviated nasal septum can accompany a deviated nasal tip.

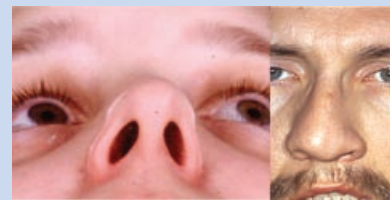


FIG. 33. Deviated nasal tip. Please note that a view from below the tip (left) shows this feature better than a frontal view (right).

Nasal Tip, Narrow

Definition: Decrease in width of the nasal tip (Fig. 34). *subjective*

Comments: Nasal tip width is assessed at the anterior junction of the alae and the tip. This is easier in persons with a somewhat squared shape of the nasal tip. This may be best viewed from the inferior aspect of the nose. No objective measures are available.

Replaces: Nasal tip, pinched

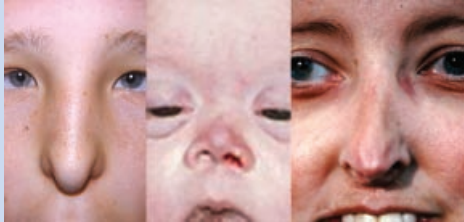

FIG. 34. Narrow nasal tip. Please note that in left panel the nasal bridge and ridge are broad and only the tip is narrow, while in right panel also the nasal bridge and ridge are narrow.

Nasal Tip, Overhanging

Definition: Positioning of the nasal tip inferior to the nasal base (Fig. 35). *subjective*

Comments: This finding is often associated with a long nasal ridge. It is best appreciated in profile. This may also coexist with a *Depressed nasal tip* and *Low insertion of the columella* and should be coded separately.

Nasal tip, pinched: see *Nasal tip, narrow*

Nasal tip, recessed: see *Nasal tip, depressed*

Nasal tip, retruded: see *Nasal tip, depressed*

Nasal tip, upturned: see *Nares, anteverted*

Nasal tip, wide: see *Nasal tip, broad*

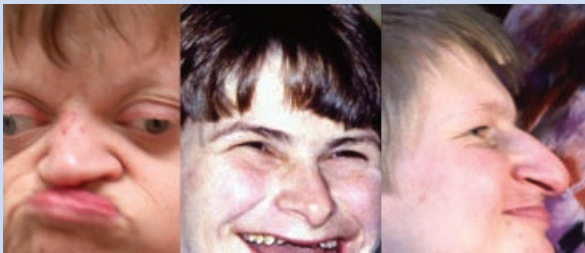


FIG. 35. Overhanging nasal tip. Please note that this feature should be evaluated from the side and can only be appreciated in a frontal view when very expressed as in the left panel.

Nose, Absent

Definition: Complete absence of all nasal structures (Fig. 36). *objective*

Nose, beaked: see *Nasal ridge, convex*

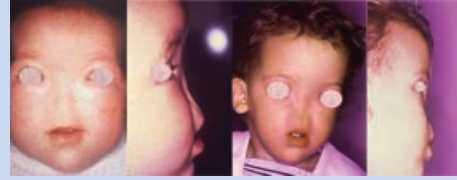

FIG. 36. Absent nose.

Nose, Bifid

Definition: Visually assessable vertical indentation, cleft, or depression of the nasal bridge, ridge and tip (Fig. 37). *subjective*

Comments: This is a bundled term, but as it is useful in practice it is kept here. If it is only an indentation or cleft of the nasal tip, this should be coded as *Bifid nasal tip*.

Nose, broad: see *Nose, wide*

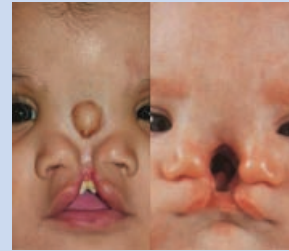

FIG. 37. Bifid nose.

Nose, Bulbous

Definition: Increased volume and globular shape of the anteroinferior aspect of the nose (Fig. 38). *subjective*

Comments: This is a bundled term, but as it is useful in practice it is kept here. This alteration of size and shape may be limited to the tip, but may involve the lower third of the nose. If only the width of the nasal tip is increased this should be coded as *Broad nasal tip*.



FIG. 38. Bulbous nose.

Replaces: Potato nose; Pear-shaped nose; Nasal tip, bulbous

Nose, flat: see *Nasal ridge, depressed*

Nose, hooked: see *Nasal ridge, convex*

Nose, Large: The term “large nose” has not been defined as it is a bundled term comprising several distinct features: prominent nose; wide nasal ridge; prominent nasal tip; and broad nasal base. It requires an assessment of volume that at present cannot be readily determined. A prominent nose is often mislabeled as a large nose.

Nose, Long

Definition: Distance from nasion to subnasale more than two SD above the mean (Fig. 39). *objective* OR

Apparently increased length from the nasal root to the nasal base. *subjective*

Comments: Normal values for length are available [Farkas, 1981; Zankl et al., 2002; Hall et al., 2007]. The length of the nose usually shows an apparent inverse relationship with the length of the philtrum. The nasion may be difficult to determine, in which case only the subjective assessment can be made. Sometimes a nose is well within normal limits in length when measured (objectively) but still appears large (subjectively). The infant’s nose usually appears shorter in relation to facial length than does that of the adult [Farkas and Munro, 1987]. The nose continues to grow throughout life, contributing in adulthood to increases in length of the nasal ridge but not necessarily of the nasal length. There are no normal adult standards to determine this. Long nose is distinct from large nose.

Synonym: Increased nasal height

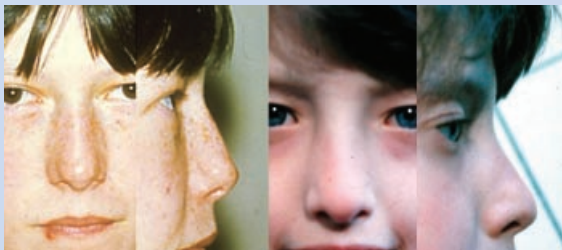

FIG. 39. Long nose. Please note that the length of the nose here is increased in an absolute sense. For an adequate subjective evaluation one needs the facial width and length for comparison.

Nose, Narrow

Definition: Interalar distance more than 2 SD below the mean for age (Fig. 40). *objective* OR

Apparently decreased width of the nasal base and alae. *subjective*

Comments: The nasal width is defined as the distance between the most lateral aspects of alae nasi. A narrow nose is often, but not necessarily, accompanied by a **Narrow nasal base**. It may also be accompanied by decreased thickness of the alae, narrow nares, or a narrow columella. The term narrow nose is also used by many to denote decreases in not only the interalar distance but also the nasal tip, ridge and bridge. As such it is a bundled term. We do not favor

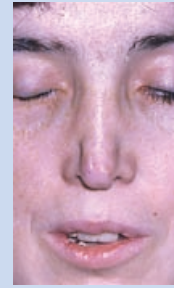

FIG. 40. Narrow nose.

this more general use of the term and instead recommend describing the individual components.

Nose, Prominent

Definition: Distance between subnasale and pronasale more than two standard deviations above the mean (Fig. 41). *objective* OR

Apparently increased anterior protrusion of the nasal tip. *subjective*

Replaces: Nose, large

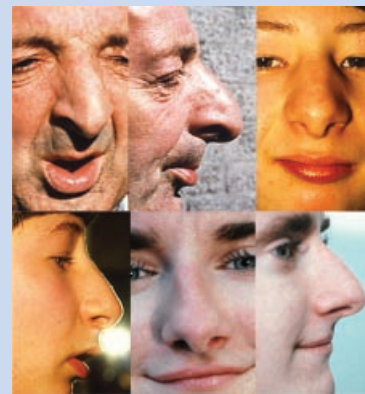

FIG. 41. Prominent nose. Please note that a prominent nose is best appreciated from the side, as the frontal pictures do not show the prominence well.

Nose, Short

Definition: Distance from nasion to subnasale more than two standard deviations below the mean (Fig. 42). *objective* OR

Apparently decreased length from the nasal root to the nasal tip. *subjective*

Comments: Normal values for length are available [Zankl et al., 2002; Hall et al., 2007]. The length of the nose usually shows a relation with the length of the philtrum. The nose and philtrum together occupy the central face zone; a change of length of one will usually be accompanied by a compensatory, opposite change in the length of the other. The nasion may be difficult to determine, in which case only the subjective assessment can be made. Sometimes a nose is well within normal limits in length when measured

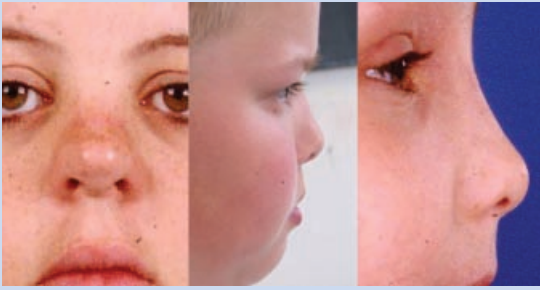


FIG. 42. Short nose. Please note that the length of the nose here is decreased in an absolute sense. For an adequate subjective evaluation one needs the facial width and length for comparison.

(objectively) but still appears small (subjectively) due to a large (mid)facial length. The infant's nose usually appears shorter in relation to facial length than does that of the adult. The nose continues to grow throughout life, contributing in adulthood to increases in length of the nasal ridge but not necessarily of the nasal length. There are no normal adult standards to determine this.

Replaces: Nose, small (a small nose both has a decreased height and a decreased width)

Nose, small: see *Nose, short*

Nose, Wide

Definition: Interalar distance more than 2 SD above the mean for age (Fig. 29). *objective* OR

Apparently increased width of the nasal base and alae. *subjective*

Comments: The nasal width is defined as the distance between the most lateral aspects of alae nasi. A broad nasal width is often, but not necessarily, accompanied by a **Wide nasal base**. It may also be accompanied by increased thickness of the alae, enlarged nares, or a broad columella. The term wide nose is used by many to denote increases in not only the interalar distance but also the nasal tip, ridge and bridge. As such it is a bundled term. We do not favor this more general use of the term and instead recommend describing the individual components.

Synonym: Nose, broad

Paranasal Tissue, Fullness

Definition: Increased bulk of tissue alongside the nose (Fig. 43). *subjective*

Comments: The fullness can be caused by both bony and soft tissues. This is distinct from **Wide nasal ridge** and **Wide nasal bridge**.

Replaces: Laterally built up nose

Pinched nose: see *Nasal ridge, narrow*

Potato nose: see *Nasal tip, bulbous*

Proboscis

Definition: a fleshy, tube-like structure usually located in the midline of the face or just to one side of the midline (Fig. 44). *objective*

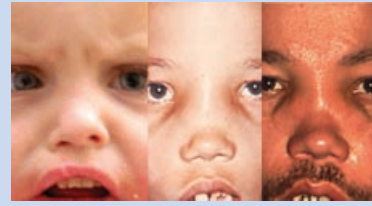

FIG. 43. Fullness of paranasal tissue. Please note that the fullness is very subtle in the left panel.

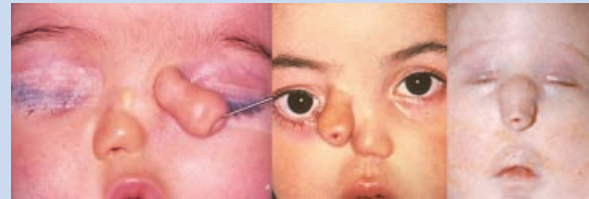

FIG. 44. Proboscis.

Comments: A proboscis has a single cavity [McGrath, 1992]. It may be found in association with a malformed nose and absence of one or both nares.

Pug nose: see *Nares, anteverted*

Saddle nose: see *Nasal ridge, concave*

Ski jump nose: see *Nasal ridge, concave*

Snub nose: see *Nasal bridge, flattened*

PHILTRUM

Anatomy of the Philtrum

The philtrum (Greek: philtron = *love potion* [ancient Greeks considered the philtrum to be one of the most erogenous spots on the human body]) is a vertical groove in the midline portion of the upper lip bordered by two lateral ridges or pillars (Fig. 2). It lies between the base of the nose (*subnasale*) and the vermilion border (*labiale superius*), which is also designated as the nasolabial distance. The lower end of the groove and the ridges form the central portion of the Cupid's bow of the vermilion [see Carey et al., 2009].

Measurements of the Philtrum

Measurement of the nasolabial distance is inaccurate, because determination of short distances between soft tissue points is difficult and may be misleading [Méhes, 1988; Ward and Jamison, 1991]. Several surveys of normal values of philtral length in various population samples have been published. For details see a selection of such papers listed in Table I.

Ideally the philtral length is measured with sliding calipers, but in practice it is typically performed with a transparent ruler [Hall et al., 2007]. Measurements should be performed in a neutral position, since facial expression can alter the landmarks. In addition to

TABLE I. Normal Values for Philtrum Length (Selected Studies)

Age of subjects/method	Country	References
13–42 weeks of gestation/sonography	Israel	Gull et al. [2005]
28–42 weeks of gestation/caliper ^a or blunt compasses	Hungary	Méhes [1981]
27–41 weeks of gestation/caliper	Japan	Fok et al. [2003]
37–41 weeks of gestation/caliper	Japan	Tateishi and Kajii [1992]
1 month to 15 years/calliper	Japan	Igarashi and Kajii [1988]
1–18 years/caliper	North America	Farkas et al. [1992]
Birth to 14 years	USA	Feingold [2001]
Birth to 12 years/photo-anthropometry	Germany	Stengel-Rutkowski et al. [1984]
Birth to 97 years/rigid transparent caliper	Switzerland	Zankl et al. [2002]

^aCaliper = sliding caliper in each case.

difficulties of measurement, significant ethnic, age and sex variations should also be considered [Stengel-Rutkowski et al., 1984].

Anatomic Variation

Characteristics of the philtrum may be classified into quantitative traits and qualitative features:

1. Variations in length: long; short
2. Variations in width: broad; narrow
3. Variations in depths: smooth; deep
4. Unusual appearance: tented; malaligned philtral ridges; midline raphe; midline sinus

DEFINITIONS

Philtral Ridges, Malaligned

Definition: Absence of the usual parallel position of philtral ridges (Fig. 45). *subjective*

Comments: Hajniš [1972] has described *downwards convergent*, *downwards divergent* (trapezoid or triangular), *convex* (ovoid), and *concave* philtral configurations. Any of these findings may be coded using the single term “malaligned philtral ridges.”

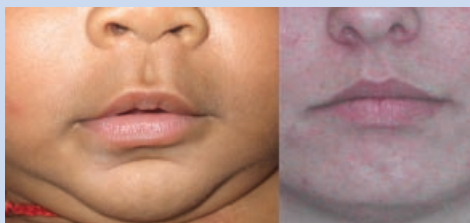


FIG. 45. Malaligned philtral ridges. In the left panel an ovoid philtrum and in the right panel a trapezoid philtrum is shown.

Philtrum, Broad

Definition: Distance between the philtral ridges, measured just above the vermillion border, more than 2 SD above the mean (Fig. 46). *objective* OR

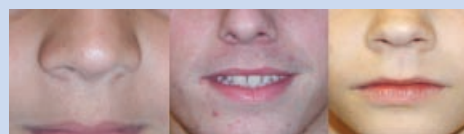


FIG. 46. Broad philtrum.

Apparently increased distance between the ridges of the philtrum. *subjective*

Comments: The mean width of the philtrum was found to be 7 mm in infants by Franz and Sokol [1971] and 9.7 mm in adults by Ward and Jamison [1991]. Measuring width of the philtrum is even more inaccurate than measuring length (vide supra). A broad philtrum may be associated with reduced ridge prominence or a shallow groove, a *Smooth philtrum*, which should be assessed and coded separately. It may be found with a broad nasal septum.

Synonym: Philtrum, wide

Philtrum, Deep

Definition: Accentuated, prominent philtral ridges giving rise to an exaggerated groove in the midline between the nasal base and upper vermillion border (Fig. 47). *subjective*

Comments: Some have used the term depressed philtrum, suggesting the presence of normal philtral ridges with a deeper

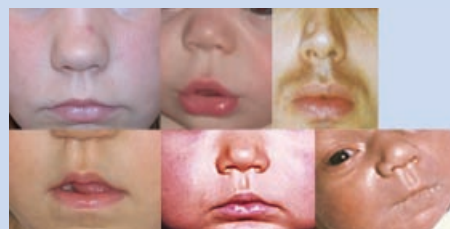

FIG. 47. Deep philtrum.

groove, while admitting the difficulty in distinguishing this from prominent ridges with a normal philtral groove [Pashayan, 1983]. We are unaware of a truly deepened philtral groove with normal height of the ridges.

Synonym: Philtrum, prominent

Replaces: Philtrum, depressed

Philtrum, depressed: see *Philtrum, deep*

Philtrum, flat: see *Philtrum, smooth*

Philtrum, indistinct: see *Philtrum, smooth*

Philtrum, Long

Definition: Distance between nasal base and midline upper lip vermilion border more than 2 SD above the mean (Fig. 48). *objective* OR

Apparently increased distance between nasal base and midline upper lip vermilion border. *subjective*

Comments: The length of the philtrum usually shows a relation with the length of the nose. The philtrum and nose together occupy the central face zone; a change of length of one will usually be accompanied by a compensatory, opposite change in the length of the other. Therefore a long philtrum often accompanies a *Short nose*, but this is not always the case and should be assessed and coded separately.

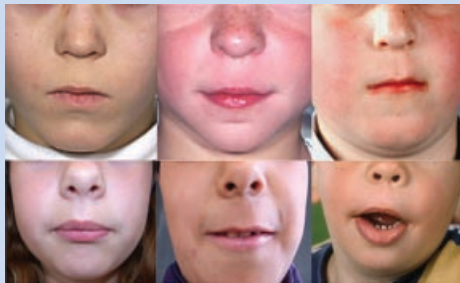

FIG. 48. Long philtrum. Please note that the length of the philtrum here is increased in an absolute sense. For an adequate subjective evaluation one needs the nasal length for comparison.

Philtrum, Midline Raphe

Definition: Narrow ridge in the midline of the philtral groove (Fig. 49). *objective*

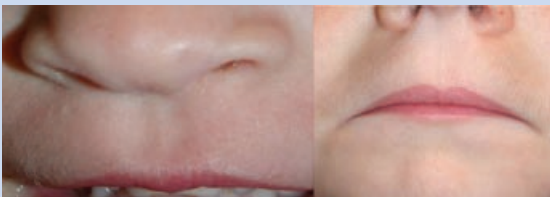


FIG. 49. Midline raphe of the philtrum.

Comment: The ridge may be very subtly elevated.

Philtrum, Midline Sinus

Definition: Pit in the midline of the philtral groove (Fig. 50). *objective*

Comments: Although congenital sinuses of the lips generally occur in the lower lip, in rare instances they may appear in the philtrum of the upper lip, commonly close to the insertion of the columella [Asahina et al., 1997].

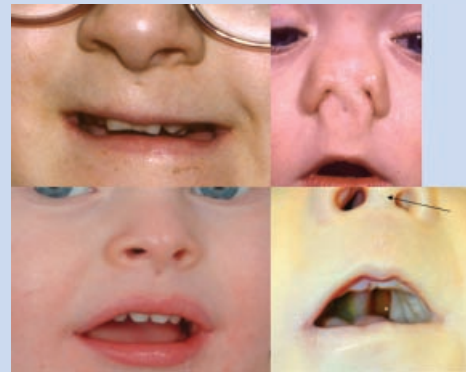

FIG. 50. Midline sinus of the philtrum. The lower two panels courtesy of Dr. Alan Fryer.

Philtrum, Narrow

Definition: Distance between the philtral ridges, measured just above the vermilion border, more than 2 SD below the mean (Fig. 51). *objective* OR

Apparently decreased distance between the ridges of the philtrum. *subjective*

Philtrum prominent: see *Philtrum, deep*

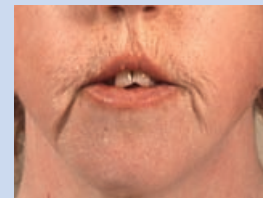

FIG. 51. Narrow philtrum.

Philtrum, Short

Definition: Distance between nasal base and midline upper lip vermilion border more than 2 SD below the mean (Fig. 52). *objective* OR

Apparently decreased distance between nasal base and midline upper lip vermilion border. *subjective*

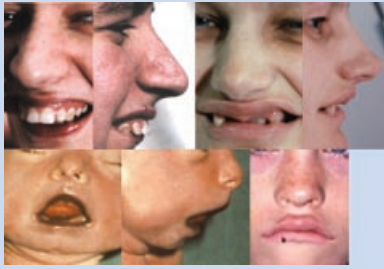

FIG. 52. Short philtrum.

Comments: Usually the nasal columella inserts at the base of the nose. A *Low insertion of the columella* leads to shortening of the philtrum, but these should be coded separately. Using the insertion of the columella as the upper limit of the philtrum would then lead to a false shortening. An *Everted upper lip* often leads to the subjective appearance of a short philtrum but these should be coded separately.

Philtrum, simple: see *Philtrum, smooth*

Philtrum, Smooth

Definition: Flat skin surface, with no ridge formation in the central region of the upper lip between the nasal base and upper vermillion border (Fig. 53). *subjective*

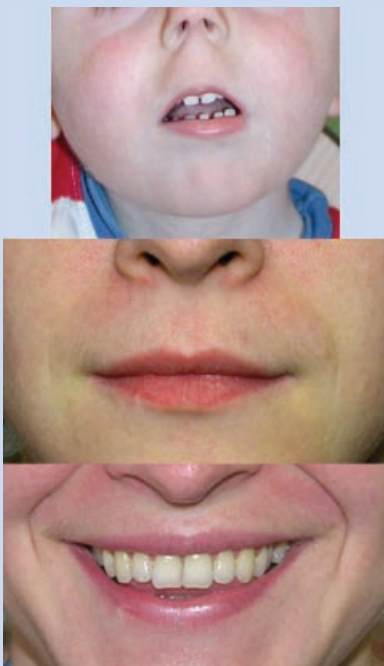

FIG. 53. Smooth philtrum. Please note that the facial movement in patient depicted in the lower panel gives the false impression of a smooth philtrum as becomes clear in the same patient with a neutral expression in the middle panel.

Comments: There is a spectrum of this finding from total absence of the philtral ridges to a some prominence of the ridges. The central groove varies from absent to shallow. Normal values for the frequency of smooth philtrum are available [Queisser-Luft et al., 2001]. Grading of the smoothness of the philtrum, used in the assessment of Fetal Alcohol Syndrome [Astley and Clarren, 1995] (Fig. 54), has been developed. This finding is greatly influenced by the facial expression, and care should be taken to evaluate the philtrum when the face is in a neutral position. A smooth philtrum can be associated with a *Long philtrum*. However, the two findings should be coded separately.

Synonym: Philtrum, flat

Replaces: Philtrum, indistinct; Philtrum, simple

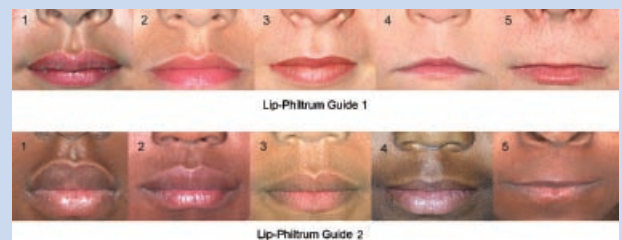

FIG. 54. Classification for the degree of smoothness in Caucasians (upper panels) and American Africans (lower panels) [Astley and Clarren, 1995]. In grade 4 and 5 the philtrum is considered smooth. Courtesy of Dr. Susan Asley.

Philtrum, Tented

Definition: Prominence of a triangular soft tissue area of the philtrum with the apex to the columella (Fig. 55). *subjective*

Comments: A tented philtrum may accompany a *Smooth philtrum*. If present this should be coded separately.

Philtrum, wide: see *Philtrum, broad*

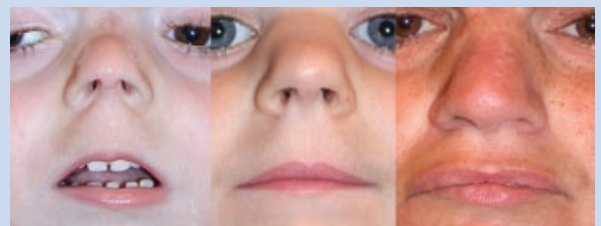


FIG. 55. Tented philtrum.

ACKNOWLEDGMENTS

We are pleased to thank Astrid Sibbes, Medical Photography and Illustration, Academic Medical Centre, Amsterdam for all drawings. This paper was reviewed and edited by the co-Chairs of the International Dysmorphologic Terminology working group (Judith Allanson, Leslie G Biesecker, John Carey, and Raoul CM Hennekam). This review and editing was necessary to increase the consistency of formatting and content among the six manuscripts. While the authors of the papers are responsible for the original definitions and drafting of the papers, final responsibility for the content of each paper is shared by the authors and the four co-Chairs.

REFERENCES

- Allanson JE, Biesecker LG, Carey JC, Hennekam RCM. 2009a. Elements of morphology: Introduction. *Am J Med Genet Part A* 149A:2–5.
- Allanson JE, Cunniff C, Hoyme HE, McGaughan J, Muenke M, Neri G. 2009b. Elements of morphology: Standard terminology for the head and face. *Am J Med Genet Part A* 149A:6–28.
- Asahina I, Sakakibara T, Miyashin M, Tachikawa N, Enomoto S. 1997. Congenital midline sinus of the upper lip: Case report and review of literature. *Cleft Palate Craniofac J* 34:83–85.
- Astley SJ, Clarren SK. 1995. A fetal alcohol syndrome screening tool. *Alcohol Clin Exp Res* 19:1565–1571.
- Biesecker LG, Aase JM, Clericuzio C, Gurrieri F, Temple IK, Toriello H. 2009. Elements of morphology: Standard terminology for the hands and feet. *Am J Med Genet Part A* 149A:93–127.
- Carey JC, Cohen MM Jr, Curry CJR, Devriendt K, Holmes LB, Verloes A. 2009. Elements of morphology: Standard terminology for the lips, mouth, and oral region. *Am J Med Genet Part A* 149A:77–92.
- Farkas LG. 1981. *Anthropometry of the head and face in medicine*. New York: Elsevier.
- Farkas LG, Munro IR. 1987. *Anthropometric facial proportions in medicine*. Springfield, IL: Charles C Thomas.
- Farkas LG, Posnick JC, Hreczko TM, Pron GE. 1992. Growth patterns of the nasolabial region: A morphometric study. *Cleft Palate Craniofac J* 29:318–324.
- Feingold M. 2001. In: Gorlin RJ, Cohen MM Jr, Hennekam RCM, editors. *Syndromes of the head and neck*, 4th edition. New York: Oxford Univ Press. p 1223.
- Fok TF, Hon KL, So HK, Wong E, Ng PC, Lee AKY, Chang A. 2003. Facial anthropometry of Hong Kong Chinese babies. *Orthod Craniofac Res* 6:164–172.
- Franz ML, Sokol AB. 1971. The proportioned philtrum: A helpful measurement and ratio. *Cleft Palate J* 1:143–146.
- Gull I, Wolman I, Merlob P, Jaffa AJ, Lessing JB, Yaron Y. 2005. Nomograms for the sonographic measurement of the fetal philtrum and chin. *Fetal Diagn Ther* 20:127–131.
- Hajniš K. 1972. Kopf-, Ohrmuschel- und Handwachstum. *Acta Univ Carol (Praha)* 2:77–294.
- Hall BD, Graham JM Jr, Cassidy SB, Opitz JM. 2009. Elements of morphology: Standard terminology for the periorbital region. *Am J Med Genet Part A* 149A:29–39.
- Hall JG, Allanson JA, Gripp K, Slavotinek A. 2007. *Handbook of normal physical measurements*, 2nd edition. New York: Oxford University Press.
- Hunter A, Frias J, Gillessen-Kaesbach G, Hughes H, Jones K, Wilson L. 2009. Elements of morphology: Standard terminology for the ear. *Am J Med Genet Part A* 149A:40–60.
- Igarashi M, Kajii T. 1988. Normal values for physical parameters of the head, face and hand in Japanese children. *Jpn J Human Genet* 33:9–31.
- McGrath P. 1992. The proboscis in human cyclopia: An anatomical study in 2 dimensions. *J Anat* 181:139–149.
- Méhes K. 1981. Normal values for philtral length, oral intercommissural distance, and sternal length in normal newborn infants. *J Craniofac Genet Dev Biol* 1:213–216.
- Méhes K. 1988. *Informative morphogenetic variants in the newborn infant*. Budapest: Akadémiai Kiad. pp 180–185.
- Pashayan HM. 1983. Recommended descriptive terms for the upper lip and philtrum. *J Clin Dysmorphol* 1:26–27.
- Queisser-Luft A, Wiesel A, Stolz G, Borck G, Schlaefer K, Zabel B, Spranger J. 2001. Klinisches Neugeborenen-screening zur Erfassung angeborener Fehlbildungen. *Monatsschr Kinderheilk* 149:1319–1325.
- Stengel-Rutkowski S, Schimanek P, Wernheimer A. 1984. Anthropometric definitions of dysmorphic facial signs. *Hum Genet* 67:272–295.
- Tateishi H, Kajii T. 1992. Physical parameters in Japanese newborns. *Jpn J Human Genet* 37:223–228.
- Ward RE, Jamison PL. 1991. Measurement precision and reliability in craniofacial anthropometry: Implications and suggestions for clinical applications. *J Craniofac Genet Dev Biol* 11:156–164.
- Zankl A, Eberle L, Molinari L, Schinzel A. 2002. Growth charts for nose length, nasal protrusion, and philtrum length from birth to 97 years. *Am J Med Genet* 111:388–391.