

Elements of Morphology: Standard Terminology for the Head and Face

Judith E. Allanson,^{1*} Christopher Cunniff,² H. Eugene Hoyme,³ Julie McGaughran,⁴ Max Muenke,⁵ and Giovanni Neri⁶

¹Department of Genetics, Children's Hospital of Eastern Ontario, Ottawa, Canada

²Section of Medical and Molecular Genetics, Department of Pediatrics, University of Arizona, Tucson, Arizona

³Department of Pediatrics, University of South Dakota, Sioux Falls, South Dakota

⁴Royal Children's Hospital, Genetic Health Queensland, Brisbane, Australia

⁵National Human Genome Research Institute, Medical Genetics Branch, National Institutes of Health, Bethesda, Maryland

⁶Istituto di Genetica Medica, Universita Cattolica, Roma, Italy

Received 15 September 2008; Accepted 19 October 2008

An international group of clinicians working in the field of dysmorphology has initiated the standardization of terms used to describe human morphology. The goals are to standardize these terms and reach consensus regarding their definitions. In this way, we will increase the utility of descriptions of the human phenotype and facilitate reliable comparisons of findings among patients. Discussions with other workers in dysmorphology and related fields, such as developmental biology and molecular genetics, will become more precise. Here we introduce the anatomy of the craniofacies and define and illustrate the terms that describe the major characteristics of the cranium and face. Published 2009 Wiley-Liss, Inc.[†]

Key words: nomenclature; definitions; anatomy; anthropometry; head; cranium; face; neck; chin; maxilla; mandible

INTRODUCTION

General

This paper is part of a series of six papers defining the morphology of regions of the human body [Biesecker et al., 2008; Carey et al., 2008; Hall et al., 2008; Hennekam et al., 2008; Hunter et al., 2008]. The series is accompanied by an introductory article describing general aspects of this study [Allanson et al., 2008]. The reader is encouraged to consult the introduction when using the definitions. The definitions are listed alphabetically based on the physical feature, not the modifier. When a feature is indicated in the text in **Bold-italics**, a definition is available either in this paper or one of the accompanying papers.

The appearance of facial morphology varies considerably with facial expression and movement, and depending on the position of the observer and observed person. When assessing a feature, the head of the observed person should be held in the Frankfurt horizontal, with the facial and neck muscles relaxed, eyes open, lips making gentle contact, and facial expression neutral. The face of the observer should be at the same height as the face of the observed person.

How to Cite this Article:

Allanson JE, Cunniff C, Hoyme HE, McGaughran J, Muenke M, Neri G. 2009. Elements morphology: Standard of terminology for the head and face. *Am J Med Genet Part A* 149A:6–28.

Anatomy of the Face and Cranium

Head shape and upper face shape are closely related to the shape of the bony skull. Figures 1 and 2 show the bony anatomy of the face. Many anthropological landmarks, bony and soft tissue, are illustrated in Figures 3 and 4.

The Anatomy of the Various Structures is Described in More Detail Below.

Cranium: The upper part of the skull consists of paired frontal and parietal bones and a single posterior occipital bone (Figs. 1 and 2). In early life these bones are separated by five major sutures (Figs. 1 and 2). Three, the coronal, lambdoidal and squamosal, are paired, and two, the sagittal and metopic, are single. Cranial growth normally occurs perpendicular to each of these major sutures.

Forehead: The part of the face above the eyebrows, below the hairline and between the temples. The paired frontalis muscles join in the midline and adhere to the superficial fascia over the frontal bone. These muscles effect forehead wrinkling or frowning. They have no bony attachments, but inferiorly the fibres blend with the

*Correspondence to:

Dr. Judith E. Allanson, Department of Genetics, Children's Hospital of Eastern Ontario, 401 Smyth Road, Ottawa, ON, Canada K1H 8L1.

E-mail: allanson@cheo.on.ca

Published online 5 January 2009 in Wiley InterScience
(www.interscience.wiley.com)

DOI 10.1002/ajmg.a.32612

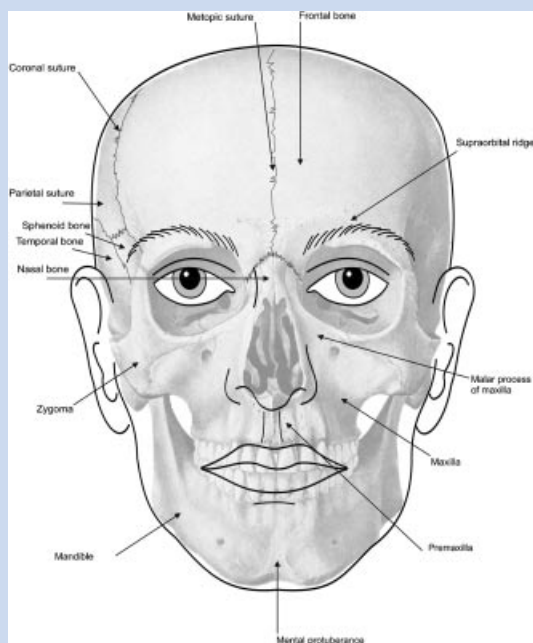


FIG. 1. An antero-posterior view of the cranium and face shows bony landmarks.

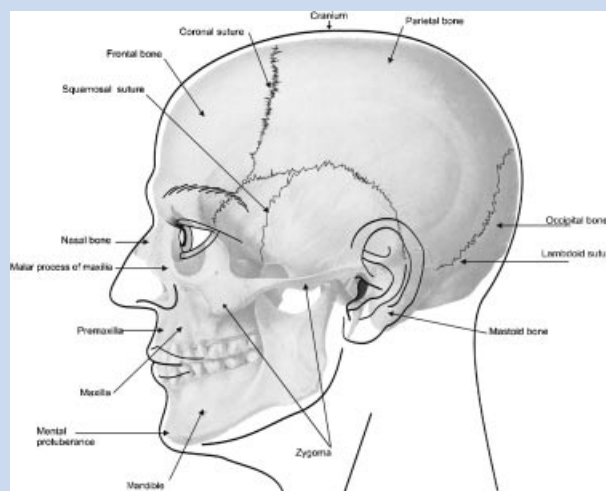


FIG. 2. A lateral view of the cranium and face shows bony landmarks.

muscles encircling the eyelids. From these attachments the fibers are directed upward, and join the galea aponeurotica below the coronal suture. The galea aponeurotica is a layer of dense fibrous tissue which covers the upper part of the cranium and attaches posteriorly to the occipital bone. It is closely connected to the integument by the firm, dense, fibro-fatty layer which forms the superficial fascia of the scalp. It cannot be wrinkled or furrowed because it does not contain muscle fibres. The anterior hairline is typically situated at the junction of frontalis muscle and galea aponeurotica.

Glabella: The most prominent point on the frontal bone above the root of the nose.

Supra-orbital ridge: The supraorbital portion of the frontal bones.

Midface: This is a region and not an anatomical term. It extends, superiorly, from the inferior orbital margin to, inferiorly, the level of nasal base. It is formed by the maxilla (upper jaw) and zygoma. Traditionally, the nose and premaxilla are not included in the midface.

Maxilla: These paired bones form, by their union, the upper jaw and contain the upper dentition. Each assists in forming the boundaries of three cavities—the palate, floor and lateral wall of the nose (frontal or malar process), and floor of the orbit. Each bone consists of a body and four processes—zygomatic, malar (frontal), alveolar and palatine.

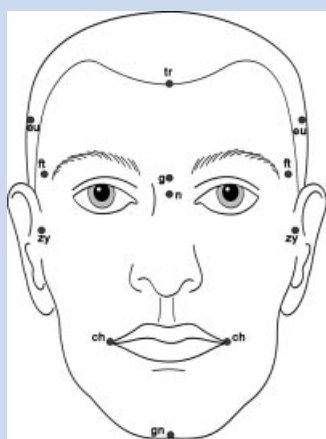


FIG. 3. Anthropological landmarks of the face, frontal view, which are described in this paper.

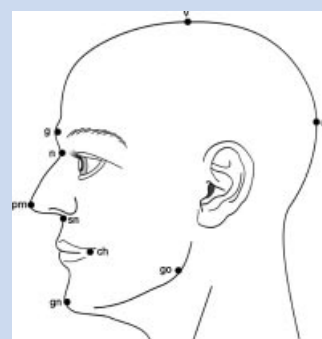


FIG. 4. Anthropological landmarks of the face, lateral view, which are described in this paper.

Malar process (syn. frontal process): The most medial and superior part of the maxilla. It forms the medial border of the inferior bony orbit, and is contiguous with the lateral boundary of the nasal bridge.

Zygoma: The part of the temporal bone of the skull that forms the prominence of the cheek. It is also known as the zygomatic bone or arch, the malar bone (creating confusion with the malar process of the maxilla), the cheek bone and the yoke bone. The zygomatic arch is composed of the malar process of the maxilla, medially, the zygoma, centrally, and the temporal bone, posterolaterally. It forms part of the part of the lateral wall and floor of the orbit.

Premaxilla: The part of the maxilla in which the 4 upper incisors develop, which forms the primary palate, and underlies the philtrum and upper lip.

Lower face: The part of the face between the mouth and the inferior point of the chin

Cheek: The soft tissues between the zygoma and mandible

Mandible: The lower jaw in which the lower teeth reside. It consists of a curved, horizontal portion, the body, and two perpendicular portions, the rami, which unite with the ends of the body nearly at right angles.

Chin: The inferior portion of the face lying inferior to the lower lip and including the central prominence of the lower jaw

Neck: The part of the body connecting the head with the shoulders

DEFINITIONS

CRANIUM

Acrocephaly: See *Turricephaly*

Brachycephaly

Definition: Cephalic index greater than 81% (Fig. 5). *objective* OR

Apparently shortened anteroposterior dimension (length) of the head compared to width. *subjective*

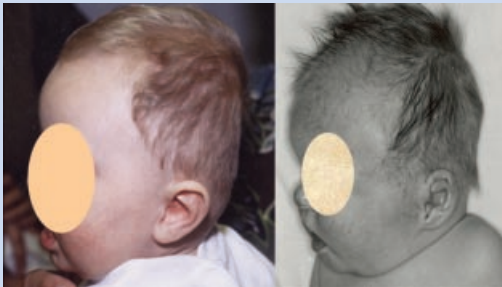

FIG. 5. *Brachycephaly*: The skull has a reduced anteroposterior dimension with the back of the head appearing to have reduced convexity.

Comments: Cephalic index is the ratio of head width expressed as a percentage of head length. The normal range is 76–80.9%. Head length is measured between the glabella (the most prominent point on the frontal bone above the root of the nose) and the most prominent part of the occiput in the midline, using spreading calipers. Head width is measured between the most lateral points of the parietal bones on each side of the head, using spreading calipers. Cephalic index standards are derived from Caucasians and have limited relevance for other races and ethnicities. Current norms also have limited validity because of changes in infant sleeping position and consequent changes in head shape. New data should be developed. Brachycephaly is distinct from *Flat occiput*, but both can be present in the same individual and should be coded separately.

Dolichocephaly

Definition: Cephalic index less than 76% (Fig. 6). *objective* OR

Apparently increased antero-posterior length of the head compared to width. *subjective*

Comments: Cephalic index is the ratio of head width expressed as a percentage of head length. The normal range is 76–80.9%. Head length is measured between the glabella (the most prominent point on the frontal bone above the root of the nose) and the most prominent part of the occiput in the midline, using spreading calipers. Head width is measured between the most lateral points of the parietal bones on each side of the head, using spreading calipers. Cephalic index standards are derived from Caucasians and have limited validity because of changes in infant sleeping position and consequent changes in head shape. New data should be developed. Dolichocephaly is distinct from *Prominent occiput*, but both can be present in the same individual and should be coded separately. Scaphocephaly is a subtype of dolichocephaly where the anterior and posterior aspects of the cranial vault are pointed (boat-shaped).

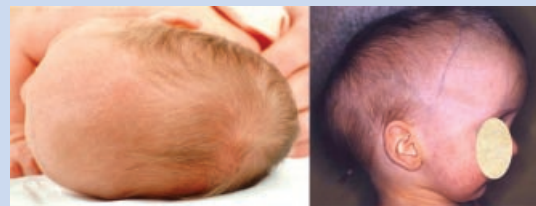


FIG. 6. *Dolichocephaly*. The skull has an increased anteroposterior dimension. Scaphocephaly is demonstrated on the right. Note that this subtype of dolichocephaly is “boat-shaped” with pointed anterior and posterior aspects of the cranial vault.

Head circumference, enlarged: See *Macrocephaly*

Head circumference, reduced: See *Microcephaly*

Kleeblattschädel: See *Skull, cloverleaf*

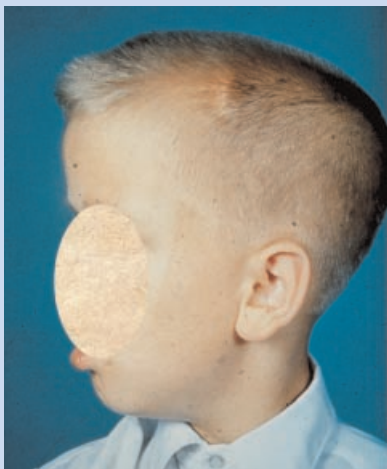

FIG. 7. **Macrocephaly.** Note the increased size of the cranium. Differences in size are difficult to appreciate but increased head size in this child is notable because of comparison with the smaller face.

Macrocephaly

Definition: Occipitofrontal (head) circumference greater than 97th centile compared to appropriate, age matched, sex-matched normal standards (Fig. 7). *objective* OR

Apparently increased size of the cranium. *subjective*

Comments: Head circumference is measured from just above the glabella (the most prominent point on the frontal bone above the root of the nose) to the most posterior prominent point of the occipital bone using a tape measure. Some standard charts are organized by centiles [Hall et al., 2007], others by standard deviations [Farkas, 1981]. It is important to add an indication of how far above the normal standard the head circumference is if an accurate assessment of this can be made. Macrocephaly is an absolute term. The term relative macrocephaly can be used when the head size centile exceeds the centile for height, for example, head size at the 75th centile with height at the 5th centile for age and sex.

Synonyms: Head circumference, enlarged; OFC, large.

Replaces: Macrocranium

Macrocranium: See **Macrocephaly**

Microcephaly

Definition: Occipito-frontal (head) circumference (OFC) less than 3rd centile compared to appropriate, age matched, normal standards (Fig. 8). *objective* OR

Apparently decreased size of the cranium. *subjective*

Comments: Head circumference is measured from just above the glabella (the most prominent point on the frontal bone above the root of the nose) to the most posterior prominent point of the occipital bone using a tape measure. Some standard charts are organized by centiles [Hall et al., 2007], others by standard deviations [Farkas, 1981]. It is important to add an indication of how far below the normal standard the head circumference is if an accurate assessment of this can be made. Microcephaly is an

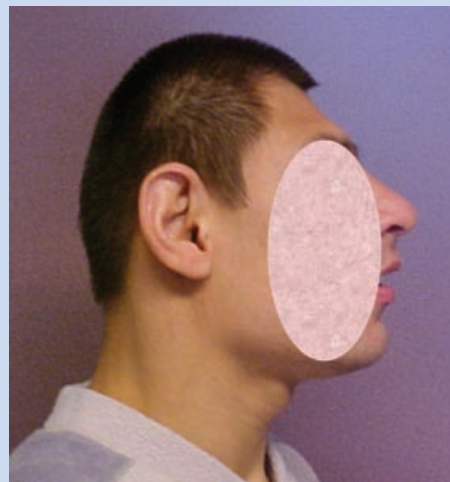

FIG. 8. **Microcephaly.** Decreased size of the cranium is accompanied by marked posterior sloping of the forehead.

absolute term. The term relative microcephaly can be used when the head size centile is less than the centile for height, for example, head size at the 3rd centile with height at the 75% for age and sex.

Synonyms: Head circumference, reduced small; OFC, small.

Replaces: Microcranium

Microcranium: See **Microcephaly**

Occiput, Flat

Definition: Reduced convexity of the occiput (posterior part of skull) (Fig. 9). *subjective*

Comments: Reduced convexity of the occiput gives an appearance of flattening. There are no objective measures for convexity of the occiput, and evaluation depends heavily on the experience of the observer. This finding may or may not be accompanied by **Brachycephaly** (which should be coded separately), and may be observed more frequently when an infant is placed to sleep on his/her back.

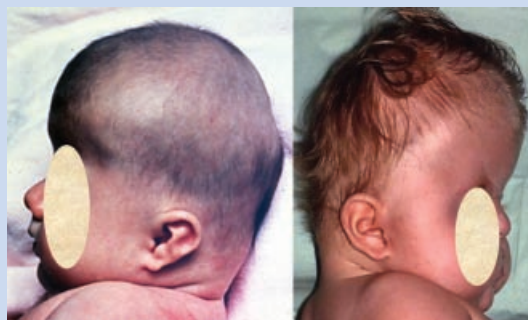

FIG. 9. **Occiput, flat.** There is reduced convexity of the occiput giving an appearance of flattening of the back of the skull.

Occiput, Prominent

Definition: Increased convexity of the occiput (posterior part of the skull) (Fig. 10). *subjective*

Comments: Increased convexity of the occiput gives an appearance of prominence. There are no objective measures for convexity of the occiput, and evaluation depends heavily on the experience of the observer. This finding may or may not be accompanied by *Dolichocephaly*, but this should be coded separately.

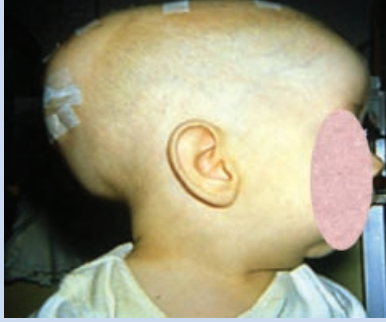

FIG. 10. *Occiput, prominent.* The posterior part of the skull shows increased convexity.

OFC, enlarged: See *Macrocephaly*

OFC, reduced: See *Microcephaly*

Oxycephaly: See *Turricephaly*

Plagiocephaly

Definition: Asymmetric head shape, which is usually a combination of unilateral occipital flattening with ipsilateral frontal prominence, leading to rhomboid cranial shape (Fig. 11). *subjective*

Comments: Plagiocephaly may affect the posterior skull alone.

Scaphocephaly: See *Dolichocephaly*

Skull, Cloverleaf

Definition: Trilobar skull configuration when viewed from the front or behind (Fig. 12). *subjective*

Synonym: Kleeblattschädel

Trigonocephaly

Definition: Wedge-shaped, or triangular head, with the apex of the triangle at the midline of the forehead and the base of the triangle at the occiput (Fig. 13). *subjective*

Comments: This shape should be assessed from above, with the examiner looking down on the head of the patient.

Turricephaly

Definition: Tall head relative to width and length (Fig. 14). *subjective*

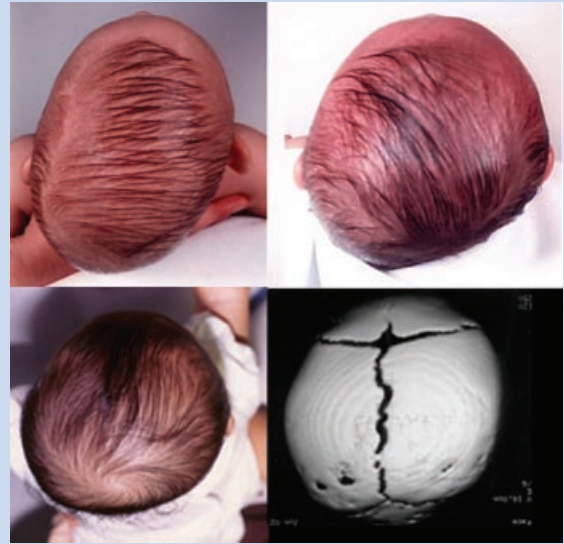


FIG. 11. *Plagiocephaly.* There is asymmetry of head shape: Note that one can see a combination of unilateral occipital flattening with ipsilateral frontal prominence, leading to rhomboid cranial shape or asymmetry of the posterior skull alone. These figures are kindly provided by John Graham Jr.

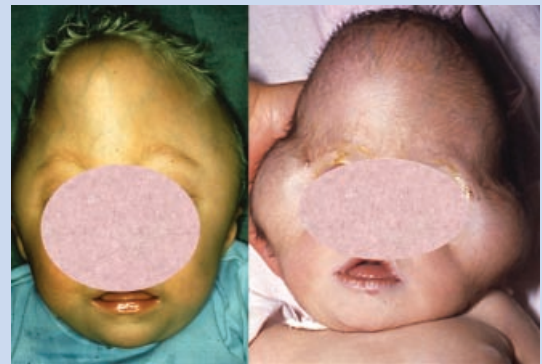

FIG. 12. *Skull, Cloverleaf.* The skull has a trilobar configuration when viewed from the front or behind.

Comments: This feature may have previously been considered to overlap with or include a tall forehead. *Turricephaly* is present when the head appears tall (subjective) and head length and width are reduced compared to normal age-related standards (objective). Head length is measured between the glabella (the most prominent point on the frontal bone above the root of the nose) and the most prominent part of the occiput in the midline, using spreading calipers. Head width is measured between the most lateral points of the parietal bones on each side of the head, using spreading calipers. The term *acrocephaly* (or *oxycephaly*) is used when there is *turricephaly* and the top of the skull assumes a cone shape.

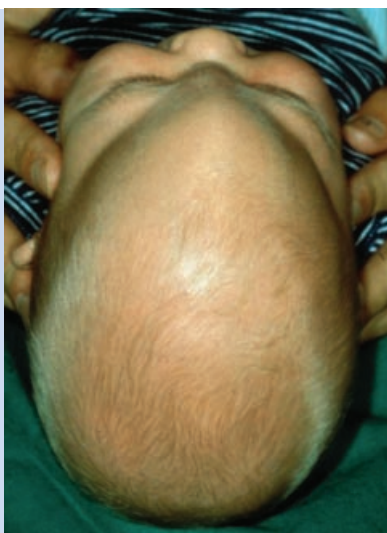

FIG. 13. *Trionocephaly*. Note the wedge-shaped, or triangular head, with the apex of the triangle at the midline of the forehead and the base of the triangle at the occiput.

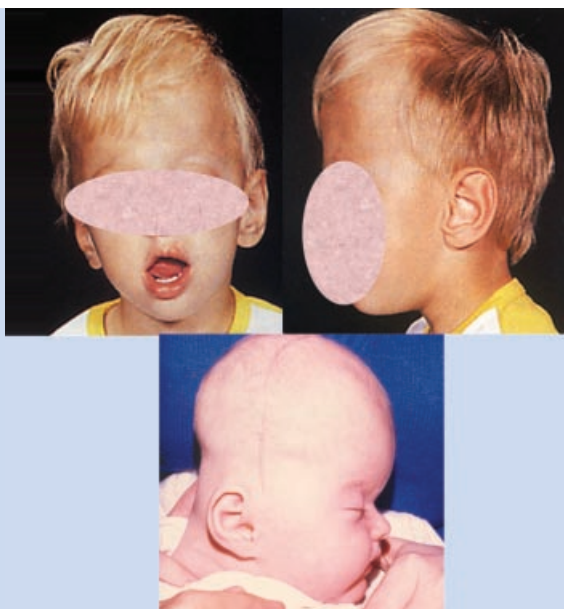


FIG. 14. *Turricephaly*. The head is tall head relative to its width and length. The terms *acrocephaly* or *oxycephaly* are used when there is *turricephaly* and the top of the skull assumes a cone shape [lower image].

SCALP HAIR

Cowlick: See *Hair, frontal upsweep*

Crown, double: See *Hair whorl, abnormal position*

Frontal Balding

Definition: Absence of hair in the anterior midline and/or parietal areas (Fig. 15). *subjective*

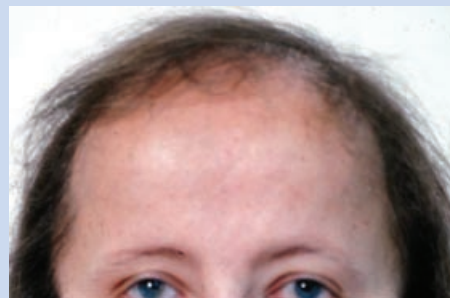

FIG. 15. *Frontal balding*. Note the absence of hair in the anterior midline and/or parietal areas.

Hair, Frontal Upsweep

Definition: Upward and/or sideward growth of anterior hair (Fig. 16). *subjective*

Replaces: Cowlick, which may be considered pejorative.




FIG. 16. *Hair, frontal upsweep*. Note the pattern of upward and sideward growth of anterior hair.

Hair Whorl, Abnormal Number

Definition: More than two clockwise hair whorls. *objective*

Comments: Most individuals have one clockwise hair whorl at a single point on the scalp lateral to the midline but close to the vertex of the skull. Five percent of the population has two whorls (Fig. 17). A double hair whorl is sometimes referred to as a double crown. In 10%, whorl direction is counter-clockwise.

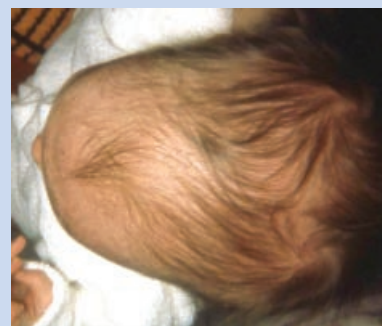

FIG. 17. *Hair whorl, double*.

Hair Whorl, Abnormal Position

Definition: Hair growth from a single point on the scalp in any location other than lateral to the midline and close to the vertex of the skull (Fig. 18). *objective*

Comments: Placement of hair whorl should be described as parietal, vertex, eccentric, etc. In addition, the number of hair whorls should be noted. Five percent of the population has two whorls.

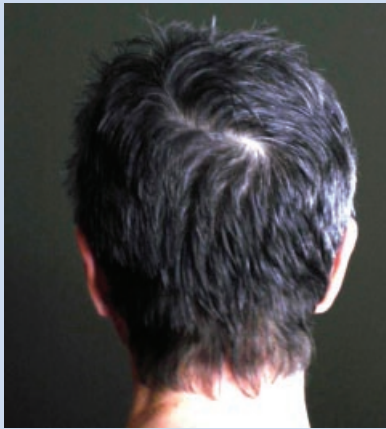

FIG. 18. *Hair whorl, abnormal position.* The hair whorl is positioned postero-inferiorly than its usual location lateral to the midline and close to the vertex of the skull.

Hairline, High Anterior

Definition: Distance between the hairline (trichion) and the glabella (the most prominent point on the frontal bone above the root of the nose), in the midline, more than two SD above the mean (Fig. 19a,b). *objective* OR

Apparently increased distance between the hairline and the glabella. *subjective*

Comments: This measurement is carried out with sliding calipers [Farkas, 1981].

This feature gives the appearance of a tall forehead, and may or may not include reduction of hair in the temporal areas. This can be distinguished from male pattern baldness as the hairline is the superior boundary of the muscular forehead, which can be actively wrinkled, in contrast to the scalp where no wrinkling can occur. In addition, texture of the skin of the scalp differs from the texture of the skin over the forehead.

Synonym: Forehead, tall

Hairline, Low Anterior

Definition: Distance between the hairline (trichion) and the glabella (the most prominent point on the frontal bone above the root of the nose), in the midline, more than two SD below the mean (Fig. 20a,b). *objective* OR

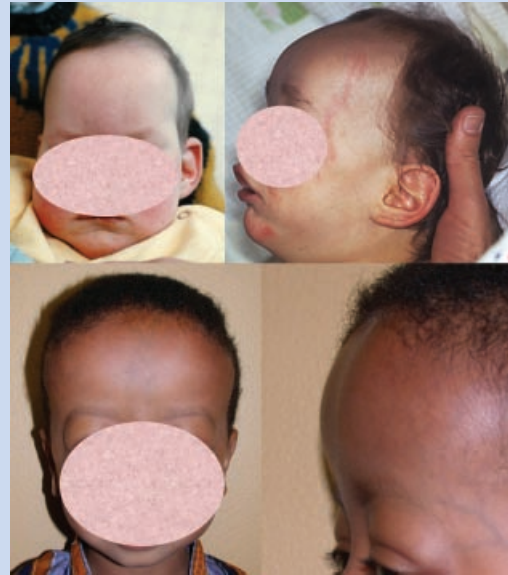

FIG. 19. *Hairline, high anterior.* The high anterior hairline contributes to an appearance of tall forehead.

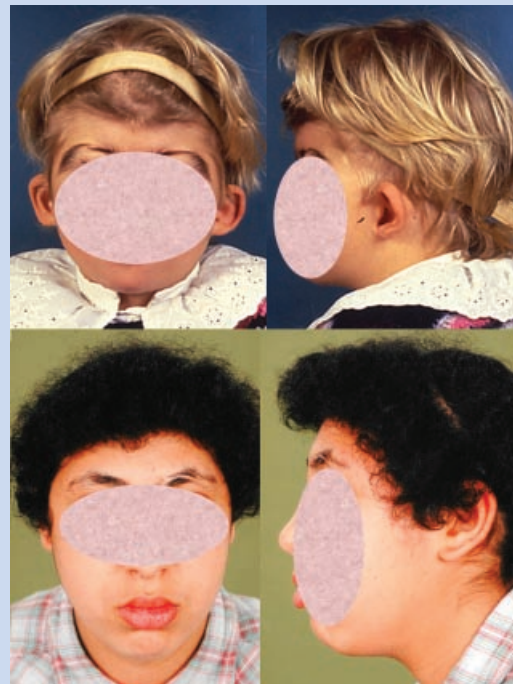

FIG. 20. *Hairline, low anterior.* The low anterior hairline contributes to an appearance of short forehead.

Apparently decreased distance between the hairline and the glabella. *subjective*

Comments: This measurement is carried out with sliding calipers [Farkas, 1981].

This feature gives the appearance of a short forehead. It is distinct from hirsutism of the forehead. In the latter, orientation of hair growth is lateral and texture and density of hair differs from scalp hair.

Synonym: Forehead, short

Hairline, Low Posterior

Definition: Hair on the neck extends more inferiorly than usual (Fig. 21). *subjective*

Comments: This feature is often seen in later childhood, as the neck lengthens, in an individual who was born with redundant nuchal skin, which should be assessed and coded separately.



FIG. 21. *Hairline, low posterior.* Hair on the neck extends more inferiorly than usual, particularly in the lateral aspects.

Scalp Hair, Sparse

Definition: Decreased number of hairs per unit area (Fig. 22). *subjective*

Comments: Hypotrichosis should not be used as a synonym as, formally, it means underdevelopment of the hair. No normal values for number of hairs per unit area exist.

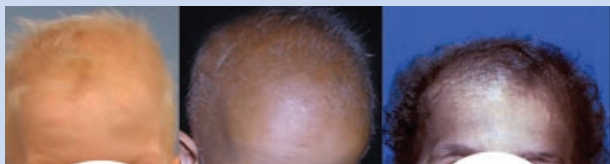

FIG. 22. *Scalp hair, sparse.* Hair density is reduced giving a thinned appearance.

Replaces: Scalp hair, thinning; Scalp hair, thin

Scalp hair, thin: See *Scalp hair, sparse*

Scalp hair, thinning: See *Scalp hair, sparse*

Widow's Peak

Definition: Frontal hairline with bilateral arcs to a low point in the midline of the forehead (Fig. 23). *subjective*

Comments: The hair may need to be pulled back to recognize this feature. Historically, English widows in the 18th century wore a black hat, triangular in shape, with a point facing forward in the midline.

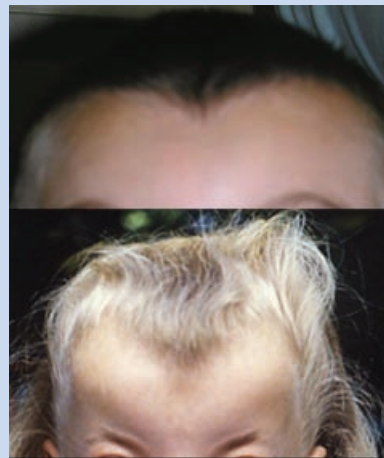

FIG. 23. *Widow's peak.* Frontal hairline shows bilateral arcs to a low point in the midline of the forehead.

FACE

Brows, prominent: See *Supraorbital ridges, prominent*

Brows, underdeveloped: See *Supraorbital ridges, underdeveloped*

Face, Broad

Definition: Bizygomatic (upper face) and bigonial (lower face) width greater than 2 SD above the mean (Fig. 24). *objective* OR

An apparent increase in the width of the face. *subjective*

Comments: Objective measurement of upper facial width is made with spreading calipers. The tips of the calipers are passed over the zygomatic arches until maximum width is determined. Objective measurement of the lower face is made with spreading calipers, with the tips firmly pressed against the inferomedial surface of the angle of the mandible [Farkas, 1981]. Broad face is distinct from *Round face*.

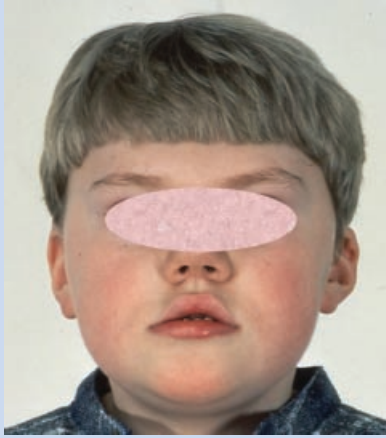

FIG. 24. *Face, broad*. An increased width of the upper and lower face.

Face, Coarse

Definition: Absence of fine and sharp appearance of brows, nose, lips, mouth and chin, usually because of rounded and heavy features or thickened skin with or without thickening of subcutaneous and bony tissues (Fig. 25). *subjective*

Comments: Note that this is a bundled term, which conveys an impression or gestalt. It is nonetheless a useful term. Note that the word coarse may be considered pejorative by some.

Synonyms: Lineaments, coarse; Features, coarse.

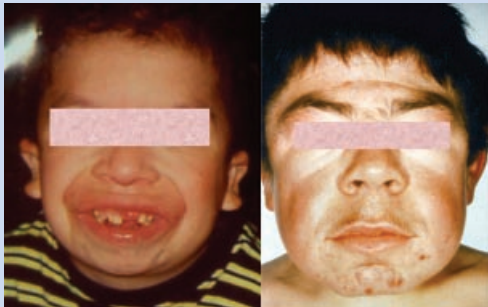

FIG. 25. *Face, coarse*. Facial features lack the usual fine and sharp appearance and are rounded and heavy with thickened skin, subcutaneous or bony tissues.

Face, elongated: See *Face, long*

Face, Expressionless

This term, which is synonymous with dull expression or hypomimic face, is not defined here as it describes a functional not a

structural feature (reduced facial movement leads to reduced crease formation).

Face, Flat

Definition: Absence of concavity or convexity of the face when viewed in profile (Fig. 26). *subjective*

Comments: A useful guide is to imagine that a line connecting the glabella to the anterior most part of the mandible touches the top of the philtrum where it meets the base of the columella. The glabella is the most prominent point on the frontal bone above the root of the nose. If the superior philtrum is anterior to this line the face is convex, if the superior philtrum is posterior to this line the face is concave.

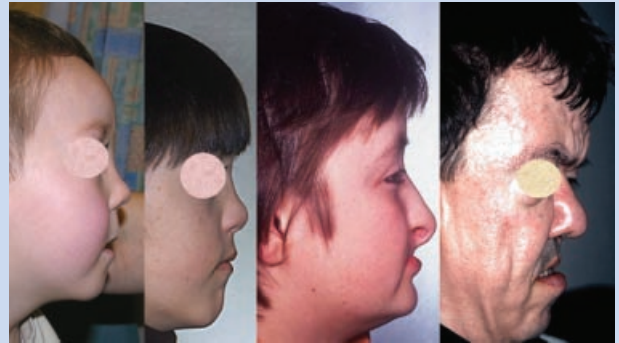

FIG. 26. *Face, flat*. The profile of the face is flat with no concavity or convexity.

Face, Hypotonic

This term is to be deleted as it is a functional, not anatomic, descriptor. Also, it is not a unitary objective finding and instead represents a conclusion based on a number of features that are defined elsewhere. These include reduced nasolabial folds, laxity and drooping of lateral supraorbital skin and ptosis, mouth held open and reduced facial expression.

Face, Long

Definition: Facial height (length) is more than 2 SD above the mean (Fig. 27). *objective* OR

An apparent increase in the height (length) of the face. *subjective*

Comments: Objective measurement of face height is made with sliding calipers from the nasion, just above the depth of the nasal root, to the gnathion, the inferior border of the mandible, both in the midline [Farkas, 1981]. Long face is distinct from *Narrow face*.

Synonym: Face, elongated

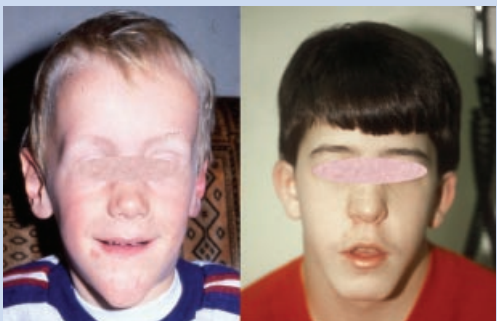

FIG. 27. *Face, long.* Height (length) of the face is increased in comparison to face width. Without actual measurement it can be difficult to decide whether increased height or reduced width is real.

Face, Narrow

Definition: Bizygomatic (upper face) and bigonial (lower face) width are more than 2 SD below the mean (Fig. 28). *objective* OR

An apparent reduction in the width of the upper and lower face. *subjective*

Comments: Objective measurement of upper facial width is made with spreading calipers. The tips of the calipers are passed over the zygomatic arches until maximum width is determined. Objective measurement of the lower face is made with spreading calipers, with the tips firmly pressed against the inferomedial surface of the angle of the mandible [Farkas, 1981]. Narrow face is distinct from *Long face*.

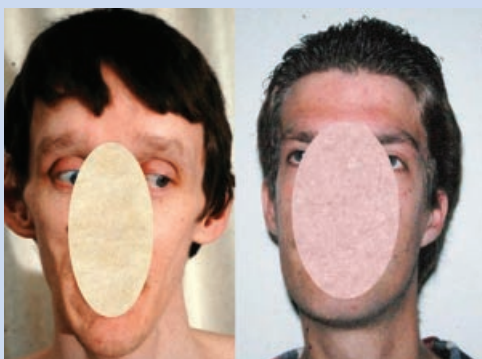

FIG. 28. *Face, narrow.* There is reduction in width of the upper and lower face. Without actual measurement it can be difficult to decide whether increased height or reduced width is real.

Face, Prematurely Aged

This term is to be deleted as it represents a conclusion based on a number of features, such as thin skin, more prominent subcutane-

ous venous patterning, lack of subcutaneous fat, excessive wrinkles, and pigmentary changes, that are defined elsewhere.

Face, Round

Definition: Facial appearance is more circular than usual, as viewed from the front (Fig. 29). *subjective*

Comment: While a *Broad face* may have rounded cheeks, a Round face appears to be as long as it is broad.

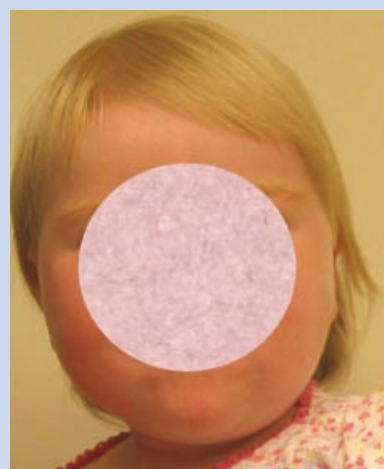

FIG. 29. *Face, round.* Facial appearance is more circular than usual.

Face, Short

Definition: Facial height (length) is more than 2 SD below the mean (Fig. 30). *objective* OR

An apparent decrease in the height (length) of the face. *subjective*

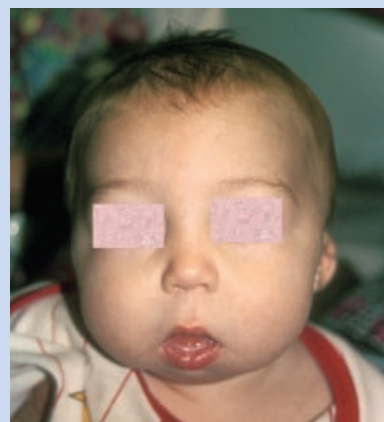

FIG. 30. *Face, short.* Decreased height (length) of the face is usually appreciated in comparison to face width and it may be difficult to decide whether reduced height or increased width is present without measurement.

Comments: Objective measurement of face height is made with sliding calipers from the nasion, just above the depth of the nasal root to the gnathion, the inferior border of the mandible, both in the midline [Farkas, 1981]. Short face is distinct from *Wide face*.

Face, Small

This term is to be deleted as it represents a combination of two terms: *Narrow face* and *Short face*. Both are defined elsewhere.

Face, Square

Definition: Facial contours, as viewed from the front, show a broad upper face/cranium and lower face/mandible, creating a square appearance (Fig. 31). *subjective*

Comments: Square face shape is usually related to increased lower facial width (a bigonial distance more than 2 SD above the mean). In *Broad jaw* the lower face is wider than the upper face.

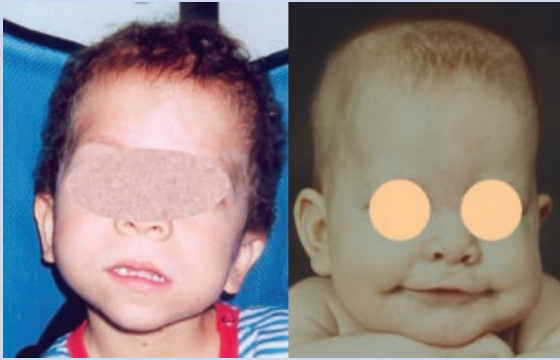

FIG. 31. *Face, square*. The upper face/cranium and lower face/mandible are both broad, creating a square appearance.

Face, Triangular

Definition: Facial contour, as viewed from the front, triangular in shape, with breadth at the temples and tapering to a narrow chin (Fig. 32). *subjective*

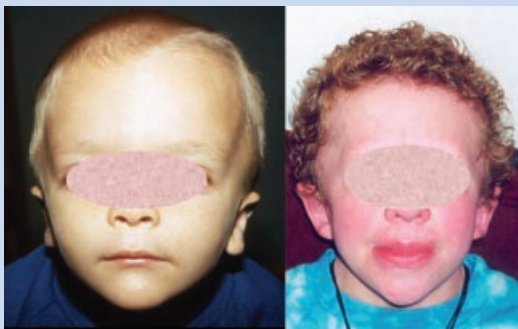

FIG. 32. *Face, triangular*. Facial contours are triangular in shape, with breadth at the temples tapering to a narrow chin.

Comment: This feature is distinct from *Narrow jaw* where width of the midface is unchanged.

Features, coarse: See *Face, coarse*

Lineaments, coarse: See *Face, coarse*

FOREHEAD

Bitemporal narrowing: See *Forehead, narrow*

Brows, prominent: See *Supraorbital ridges, prominent*

Brows, underdeveloped: See *Supraorbital ridges, underdeveloped*

Forehead, Broad

Definition: Width of the forehead or distance between the fronto-temporales is more than 2 SD above the mean (Fig. 33). *objective* OR

Apparently increased distance between the two sides of the forehead. *subjective*

Comments: Frontotemporalis is a point lateral to the vertical component of the supraorbital ridge, where there is a hollowing. Spreading caliper tips are placed in the deepest part of that hollow [Farkas, 1981]. This term should not be confused with *Prominent forehead*.

Synonym: Forehead, wide

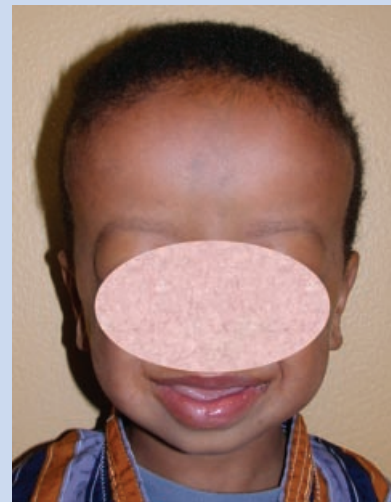

FIG. 33. *Forehead, broad*. Note the increased distance between the two sides of the forehead.

Forehead, bulging: See *Forehead, prominent* and *Frontal bossing*

Forehead, high: See *Hairline, high anterior*

Forehead, low: See *Hairline, low anterior*

Forehead, Narrow

Definition: Width of the forehead or distance between the fronto-temporales is more than two SD below the mean (Fig. 34). *objective* OR

Apparently narrow inter-temporal region. *subjective*

Comments: Frontotemporalis is a point lateral to the vertical component of the supraorbital ridge, where there is a hollowing. Spreading caliper tips are placed in the deepest part of that hollow [Farkas, 1981].

Synonyms: Bitemporal narrowing; Intertemporal narrowing

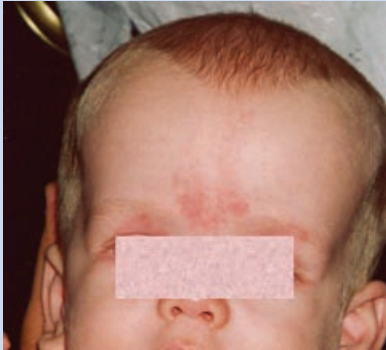

FIG. 34. *Forehead, narrow.* Note the decreased distance between the two sides of the forehead with narrowing at the temples.

Forehead, Prominent

Definition: Forward prominence of the entire forehead, due to protrusion of the frontal bone (Fig. 35). *subjective*

Comments: This is not the same as *Frontal bossing* (see below).

Replaces: Forehead, bulging

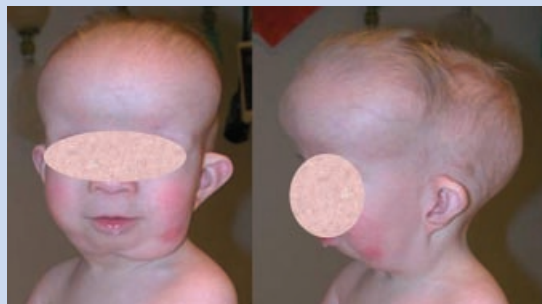

FIG. 35. *Forehead, prominent.* The entire forehead is prominent due to protrusion of the frontal bone.

Forehead, short: See *Hairline, low anterior*

Forehead, Sloping

Definition: Inclination of the anterior surface of the forehead from the vertical more than 2 SD above the mean (Fig. 36). *objective* OR

Apparently excessive posterior sloping of the forehead in a lateral view. *subjective*

Comments: Measurement requires an angle meter, inclined on the anterior surface of the forehead, in the midline, along a line connecting the hairline to the glabella, compared to the vertical [Farkas, 1981] with the head held in the Frankfurt horizontal.

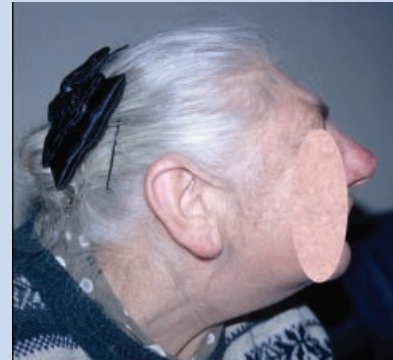

FIG. 36. *Forehead, sloping.* The anterior surface of the forehead slopes posteriorly in an excessive manner.

Forehead, tall: See *Hairline, high anterior*

Forehead, wide: See *Forehead, broad*

Forehead Creases, Vertical

Definition: Vertical soft tissue creases in the midline of the forehead, often extending from the hairline to the brow, and seen with facial expression, or when the face is at rest (Fig. 37). *subjective*

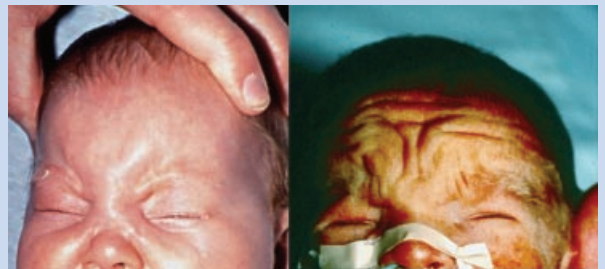

FIG. 37. *Forehead creases, vertical.* Vertical soft tissue creases are noted in the midline of the forehead. These often extend from the hairline to the brow.

Frontal Bossing

Definition: Bilateral bulging of the lateral frontal bone prominences with relative sparing of the midline (Fig. 38). *subjective*

Comments: This is not the same as **Prominent forehead** (see above)

Replaces: Forehead, bulging

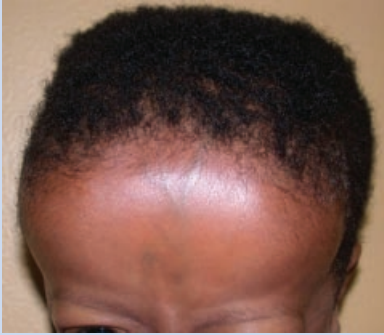

FIG. 38. **Frontal bossing.** There is bilateral bulging of the lateral aspects of the forehead with relative sparing of the midline.

Glabella, Depressed

Definition: Posterior positioning of the midline forehead between the supraorbital ridges (Fig. 39). *subjective*

Comments: The glabella is the area of the forehead in the midline between the supraorbital ridges, just above the nasal root. The term “depressed” used here is not meant to signify an active process.



FIG. 39. **Glabella, depressed.** Note the depression of the midline forehead between the supraorbital ridges.

Glabella, Prominent

Definition: Forward protrusion of the glabella (Fig. 40). *subjective*

Comments: The glabella is the area of the forehead in the midline between the supraorbital ridges, just above the nasal root.

Intertemporal narrowing: See **Forehead, narrow**

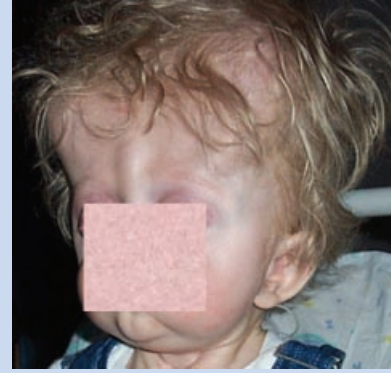

FIG. 40. **Glabella, prominent.** Note prominence of the glabella, the area of the forehead in the midline between the supraorbital ridges, just above the nasal root.

Metopic Depression

Definition: Linear vertical groove in the midline of the forehead, extending from hairline to glabella (Fig. 41). *subjective*

Comments: There is no underlying bony defect (metopism).

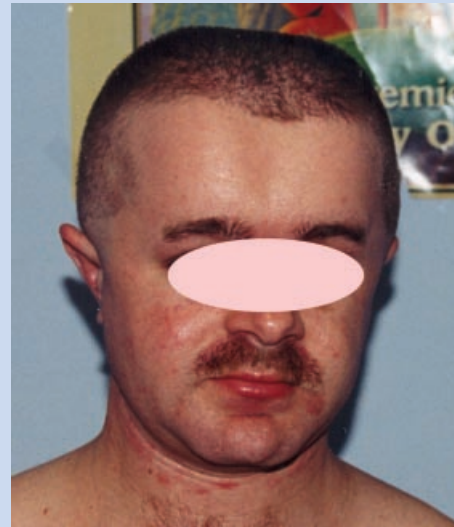

FIG. 41. **Metopic depression.** There is a linear vertical groove in the midline of the forehead, extending from hairline to glabella.

Metopic Ridge, Prominent

Definition: Vertical bony ridge positioned in the midline of the forehead (Fig. 42). *subjective*

Comments: The ridge may extend from the hairline to the glabella or may be partial.

Synonym: Metopic suture, prominent

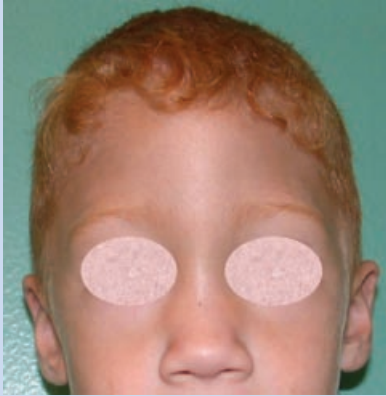

FIG. 42. *Metopic ridge, prominent.* Note the vertical bony ridge in the midline of the forehead.

Metopic suture, prominent: See *Metopic ridge, prominent*

Supraorbital ridges, flattened: See *Supraorbital ridges, underdeveloped*

Supraorbital ridges, hypoplastic: See *Supraorbital ridges, underdeveloped*

Supraorbital ridges, hyperplastic: See *Supraorbital ridges, prominent*

Supraorbital Ridges, Prominent

Definition: Greater than average forward and/or lateral protrusion of the supraorbital portion of the frontal bones (Fig. 43). *subjective*

Comments: The ridges need not be thickened or heavy to be prominent.

Replaces: Supraorbital ridges, hyperplastic; Brows, prominent

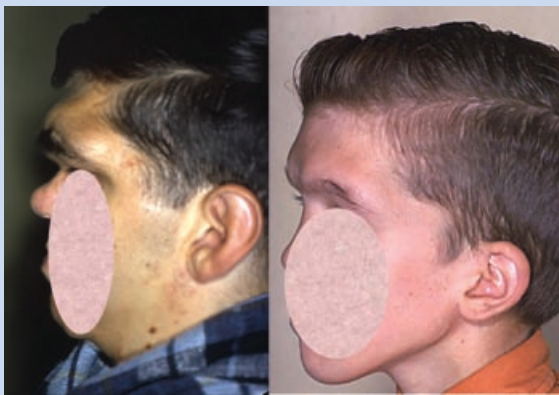

FIG. 43. *Supraorbital ridges, prominent.* The supraorbital portion of the frontal bones protrudes forward and laterally.

Supraorbital Ridges, Underdeveloped

Definition: Flatness of the supraorbital portion of the frontal bones (Fig. 44). *subjective*

Synonyms: Supraorbital ridges, flattened

Replaces: Supraorbital ridges, hypoplastic; Brows, underdeveloped

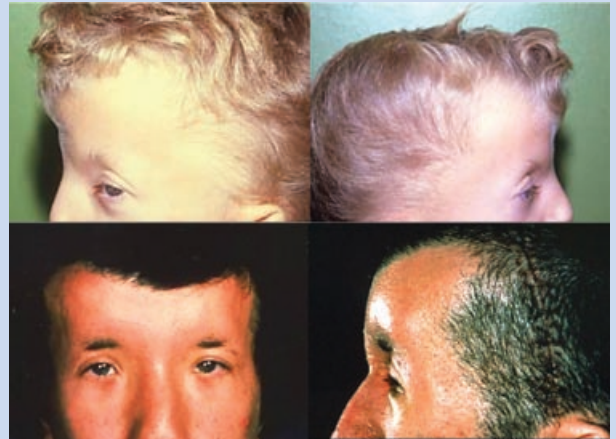

FIG. 44. *Supraorbital ridges, underdeveloped.* The supraorbital portion of the frontal bones is less prominent than usual.

MAXILLA AND MIDFACE

Cheekbone, flat: See *Cheekbone, underdeveloped*

Cheekbone Prominence

Definition: Enlargement of the zygomatic process of the temporal bone of the skull, which forms the middle and lateral inferior orbital margin (Fig. 45). *subjective*

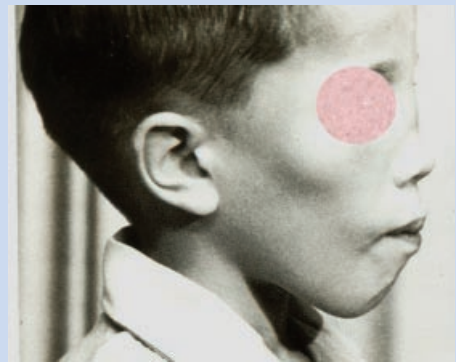

FIG. 45. *Cheekbone prominence.* The cheekbones overlying the zygoma of the temporal bone of the skull are more prominent than usual.

Synonym: Zygomatic prominence

Replaces: Zygomatic hyperplasia

Cheekbone Underdevelopment

Definition: Reduction in size of the zygomatic process of the temporal bone of the skull, which forms the middle and lateral inferior orbital margin (Fig. 46). *subjective*

Synonym: Cheekbone, flat; Zygomatic underdevelopment

Replaces: Zygomatic hypoplasia

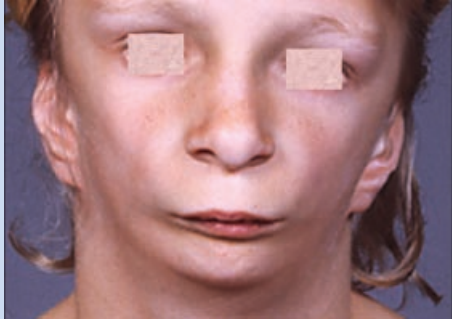

FIG. 46. *Cheekbone underdevelopment.* The cheekbones overlying the zygoma of the temporal bone of the skull are less prominent than usual.

Cheeks, Full

Definition: Increased prominence or roundness of the soft tissues between the zygomata and mandible (Fig. 47). *subjective*

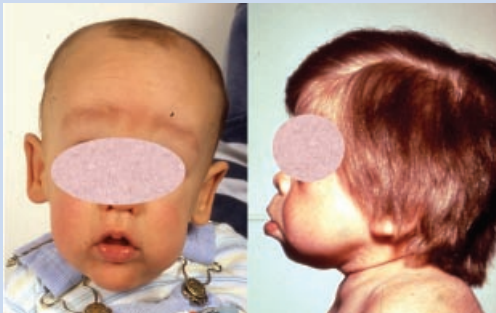

FIG. 47. *Cheeks, full.* Note the increased prominence or roundness of the soft tissues between the cheekbones and mandible.

Cheeks, Sunken

Definition: Lack or loss of the soft tissues between the zygomata and mandible (Fig. 48). *subjective*

Comments: This appearance is found more often in edentulous patients.

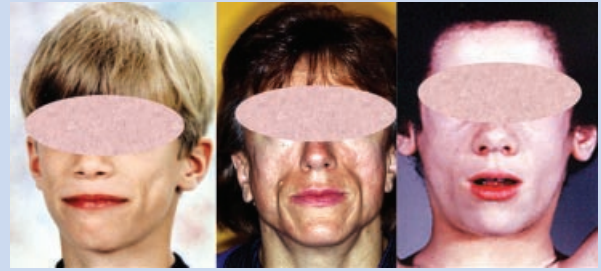

FIG. 48. *Cheeks, sunken.* Note the reduced prominence or fullness of the soft tissues between the cheekbones and mandible.

Malar Flattening

Definition: Underdevelopment of the malar (frontal) process of the maxilla, appreciated in profile and/or by palpation (Fig. 49). *subjective*

Comments: The malar process is the most medial and superior portion of the maxilla, contiguous with the lateral boundary of the nasal bridge.

Replaces: Malar hypoplasia (surface examination cannot distinguish hypoplasia from hypotrophy)

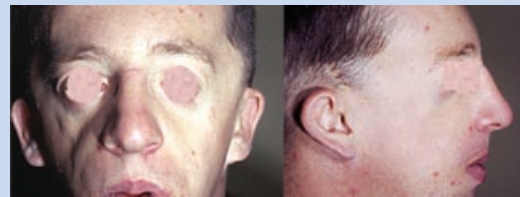

FIG. 49. *Malar flattening.* Note the underdevelopment of bony tissues lateral to the nasal bridge extending from the inner corner of the eye to the medial aspect of the cheekbone.

Malar hyperplasia: See *Malar prominence*

Malar hypertrophy: See *Malar prominence*

Malar hypoplasia: See *Malar flattening*

Malar Prominence

Definition: Prominence of the malar (frontal) process of the maxilla and infraorbital area, appreciated in profile and from front of the face (Fig. 50). *subjective*

Comments: The malar process is the most medial and superior portion of the maxilla, contiguous with the lateral boundary of the nasal bridge.

Replaces: Malar hypertrophy; malar hyperplasia

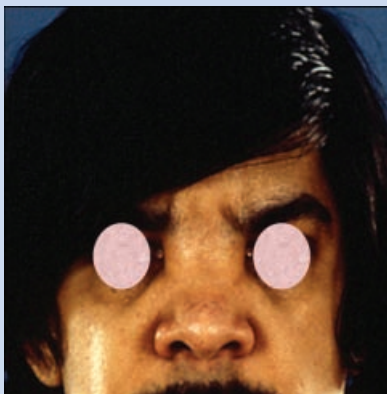

FIG. 50. *Malar prominence*. Note the prominence of bony tissues lateral to the nasal bridge extending from the inner corner of the eye to the medial aspect of the cheekbone.

Midface hyperplasia: See *Midface prominence*

Midface hypertrophy: See *Midface prominence*

Midface hypoplasia: See *Midface retrusion*

Midface Prominence

Definition: Anterior positioning of the infraorbital and perialar regions, or increased convexity of the face, or increased nasolabial angle (Fig. 51). *subjective*

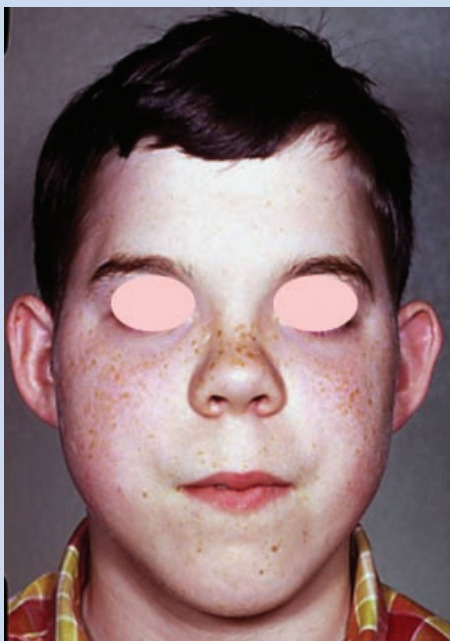

FIG. 51. *Midface prominence*. Note prominence of the infraorbital and perialar regions leading to more pronounced convexity of the face and increased nasolabial angle.

Comments: This term represents increased size of the maxilla (upper jaw) in length (increased midface height) or depth (midface prominence). In the presence of normal mandible size, maxillary prominence may give the appearance of retrognathia.

Replaces: Midface hyperplasia; Midface hypertrophy

Midface Retrusion

Definition: Posterior positioning and/or vertical shortening of the infraorbital and perialar regions, or increased concavity of the face and/or reduced nasolabial angle (Fig. 52). *subjective*

Comments: This term represents underdevelopment of the maxilla (upper jaw) in length (decreased midface height) or depth (retrusion of the maxilla). In the presence of normal mandible size, midface retrusion may give the appearance of prognathism. Caution should be used in making this assessment in edentulous patients. This is different from a *Flat face*.

Replaces: Midface hypoplasia

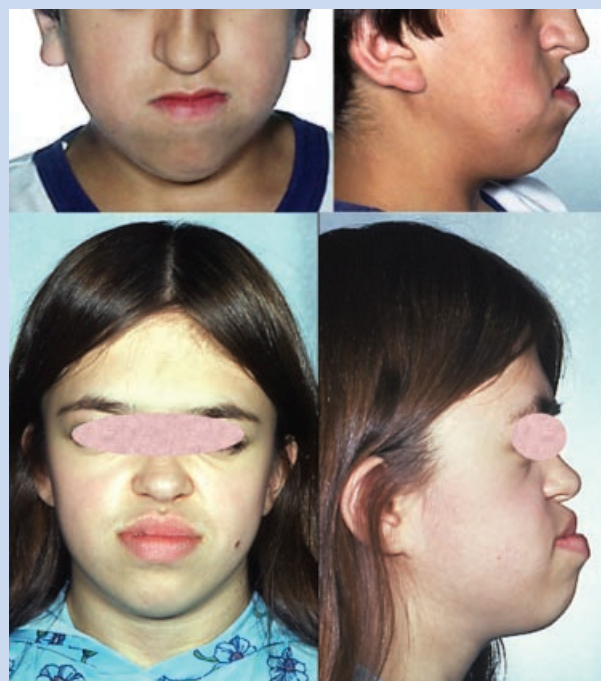

FIG. 52. *Midface retrusion*. Note underdevelopment of the infra-orbital and peri-alar regions leading to more pronounced concavity of the face and reduced nasolabial angle. This gives the appearance of prognathia.

Nasolabial crease, hypoplastic: See *Nasolabial fold, underdeveloped*

Nasolabial crease, prominent: See *Nasolabial fold, prominent*

Nasolabial crease, underdeveloped: See *Nasolabial fold, underdeveloped*

Nasolabial fold, hypoplastic: See *Nasolabial fold, underdeveloped*

Nasolabial Fold, Prominent

Definition: Exaggerated bulkiness of the crease or fold of skin running from the lateral margin of the nose, where nasal base meets the skin of the face, to a point just lateral to the corner of the mouth (cheilion, or commissure) (Fig. 53). *subjective*

Comments: Increasing prominence with age is usual.

Synonym: Nasolabial crease, prominent

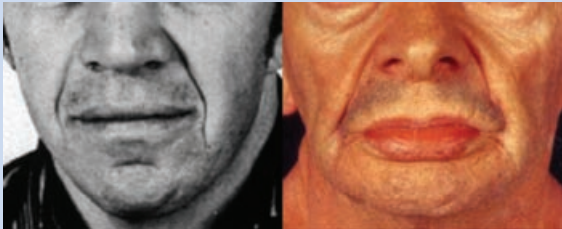

FIG. 53. *Nasolabial fold, prominent.* The crease or fold of skin running from the lateral margin of the nose, where nasal base meets the skin of the face, to a point just lateral to the corner of the mouth is more prominent than usual.

Nasolabial Fold, Underdeveloped

Definition: Reduced bulkiness of the crease or fold of skin running from the lateral margin of the nose, where nasal base meets the skin of the face, to a point just lateral to the corner of the mouth (cheilion or commissure) (Fig. 54). *subjective*

Synonym: Nasolabial crease, underdeveloped

Replaces: Nasolabial crease, hypoplastic; Nasolabial fold, hypoplastic

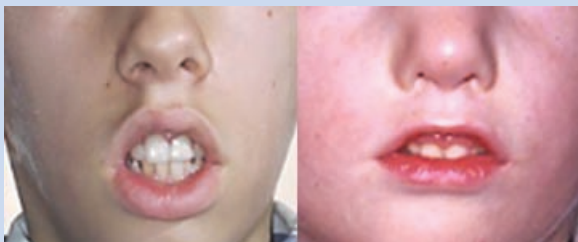

FIG. 54. *Nasolabial fold, underdeveloped.* The crease or fold of skin running from the lateral margin of the nose, where nasal base meets the skin of the face, to a point just lateral to the corner of the mouth is less prominent than usual.

Premaxillary hyperplasia: See *Premaxillary prominence*

Premaxillary hypoplasia: See *Premaxillary underdevelopment*

Premaxillary Prominence

Definition: Overdevelopment of the premaxilla (Fig. 55). *subjective*

Comments: As a consequence of prominence of the premaxilla, the overlying structures, the nose and philtrum, may appear prominent. There is increased convexity of the face and an increased nasolabial angle. In the presence of a normal sized mandible, retrognathia may be appreciated.

Replaces: Premaxillary hyperplasia

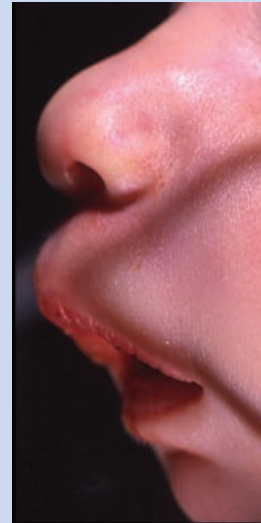

FIG. 55. *Premaxillary prominence.* Note increased convexity of the face and an increased nasolabial angle giving the impression of retrognathia.

Premaxillary Underdevelopment

Definition: Reduction in size of the premaxilla (Fig. 56). *subjective*

Comments: As a consequence of underdevelopment of the premaxilla, the overlying structures, the nose and philtrum, may appear flattened. There is increased concavity of the face and a reduced nasolabial angle. In the presence of a normal sized mandible, prognathism may be appreciated.

Replaces: Premaxillary hypoplasia

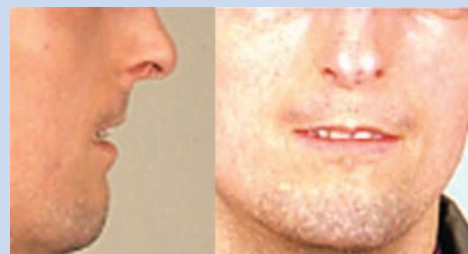


FIG. 56. *Premaxillary underdevelopment.* Note decreased convexity of the face and nasolabial angle giving the impression of prognathia.

Zygomatic hyperplasia: See *Cheekbone prominence*

Zygomatic hypoplasia: See *Cheekbone underdevelopment*

Zygomatic prominence: See *Cheekbone prominence*

Zygomatic underdevelopment: See *Cheekbone underdevelopment*

MANDIBLE

Chin, retruded: See *Retrognathia*

Habsburg/Hapsburg chin: See *Prognathism*

Habsburg/Hapsburg jaw: See *Prognathism*

Jaw, Broad

Definition: Bigonial distance (lower facial width) more than 2 SD above the mean (Fig. 57). *objective* OR

Apparently increased width of the lower jaw (mandible) when viewed from the front. *subjective*

Comments: The lower jaw is measured from the right gonion to the left gonion using spreading calipers. The gonion is the point at the angle of the bony mandible where the ramus changes direction to become the body of the mandible. It faces inferiorly and medially and is best found by placing a finger over the outward facing angle and rolling the finger downwards and inwards [Farkas, 1981]. When a broad jaw is accompanied by a broad upper face the term *Square face* is used.

Synonyms: Jaw, wide; Mandible, broad; Mandible, wide; Lower face, broad; Lower face, wide

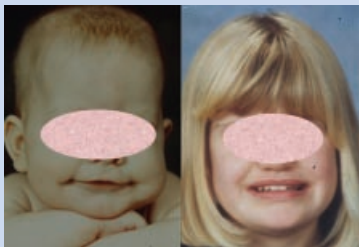

FIG. 57. *Jaw, broad*. Note increased width of the lower jaw (mandible).

Jaw, Narrow

Definition: Bigonial distance (lower facial width) more than 2 SD below the mean (Fig. 58). *objective* OR

Apparently decreased width of the lower jaw (mandible) when viewed from the front. *subjective*

Comments: This dimension is measured from the right gonion to the left gonion using spreading calipers. The gonion is the point at the angle of the bony mandible where the ramus changes direction to become the body of the mandible. It faces inferiorly and medially

and is best found by placing a finger over the outward facing angle and rolling the finger downwards and inwards [Farkas, 1981].

Synonyms: Mandible, narrow; Lower face, narrow

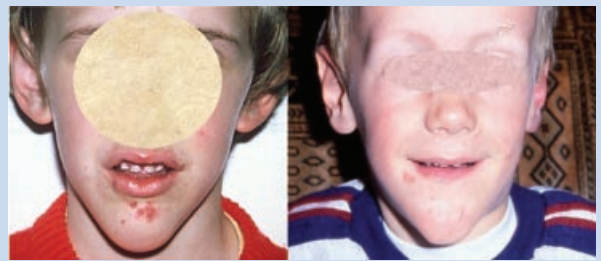

FIG. 58. *Jaw, narrow*. Note decreased width of the lower jaw (mandible).

Jaw, small: See *Micrognathia*

Jaw, wide: See *Jaw, broad*

Lower face, broad: See *Jaw, broad*

Lower face, narrow: See *Jaw, narrow*

Lower face, wide: See *Jaw, broad*

Mandible, broad: See *Jaw, broad*

Mandible narrow: See *Jaw, narrow*

Mandible, wide: See *Jaw, wide*

Mandible, Cleft

Definition: Midline deficiency of the mandible and some or all overlying tissues (Fig. 59). *objective*

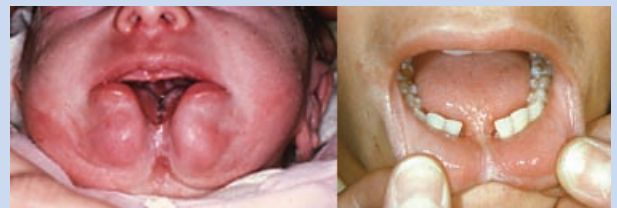

FIG. 59. *Mandible, cleft*. There is a complete midline deficiency of the mandible on the left and deficiency of overlying tissues on the right.

Mandible, narrow: See *Jaw, narrow*

Mandible, retruded: See *Retrognathia*

Mandible, wide: See *Jaw, broad*

Micrognathia

Definition: Apparently reduced length and width of the mandible when viewed from the front but not from the side (Fig. 60). *subjective*

Comments: This is a bundled term comprising shortening and narrowing of the mandible and chin. It is defined here as it is a term in common usage.

Synonyms: Micrognathism; Jaw, small

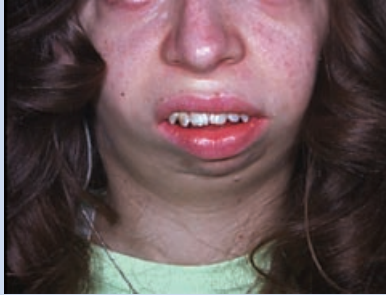

FIG. 60. *Micrognathia*. There is shortening and narrowing of the mandible and chin.

Micrognathism: See *Micrognathia*

Prognathia: See *Prognathism*

Prognathism

Definition: Anterior protrusion of the mandibular alveolar ridge beyond the vertical plane of the maxillary alveolar ridge, best appreciated in profile (Fig. 61). *subjective*

Comments: The examiner must use judgment to distinguish a protruding mandible from an *Underdeveloped premaxilla* or *Retruded midface*, either of which may be accompanied by class III malocclusion.

Synonym: Prognathia

Replaces: Habsburg chin; Hapsburg chin; Habsburg jaw; Hapsburg jaw

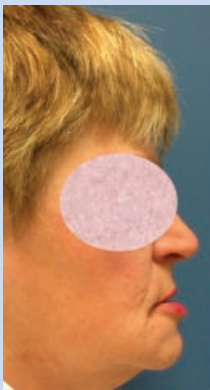

FIG. 61. *Prognathism*. There is anterior protrusion of the mandible such that the alveolar ridge extends beyond the vertical plane of the maxillary alveolar ridge.

Retrognathia

Definition: Posteriorly positioned lower jaw, which is set back from the plane of the face when viewed from the side but not from the front (Fig. 62). *subjective*

Comments: This feature may be accompanied by micrognathia (microretrognathia) in which case both retrognathia and micrognathia should be specified and coded separately. Alternatively, it may be a mismatch in the relative position of the mandible and premaxilla, with normal mandibular length and premaxillary prominence and is accompanied by a class II malocclusion.

Synonyms: Chin, retruded; Mandible, retruded; Retrognathism

Retrognathism: See *Retrognathia*

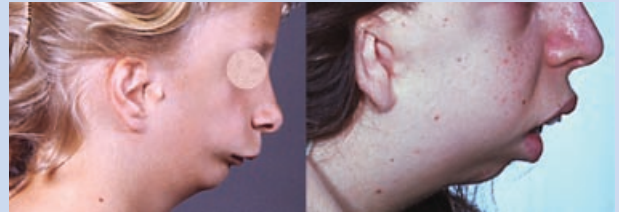

FIG. 62. *Retrognathia*. The lower jaw is set back from the plane of the face.

CHIN

Chin, Broad

Definition: Increased width of the midpoint of the mandible (mental protuberance) and overlying soft tissue (Fig. 63). *subjective*

Comments: Micrognathia is a term that represents reduction in size of both length and width of the chin. By contrast, increases in chin size are coded separately as *Tall chin* and *Broad chin*.

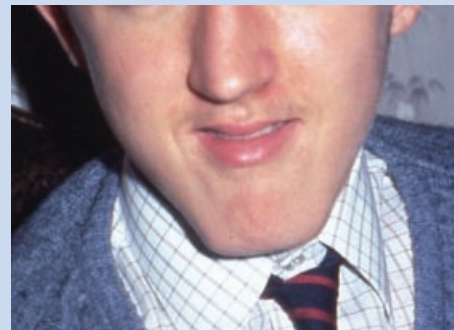

FIG. 63. *Chin, broad*. The midpoint of the mandible [mental protuberance] and overlying soft tissue is broader than usual.

Chin, cleft: See *Chin, vertical crease*

Chin Dimple

Definition: A persistent midline depression of the skin over the fat pad of the chin (Fig. 64). *subjective*

Comments: The borders of the depression are round.

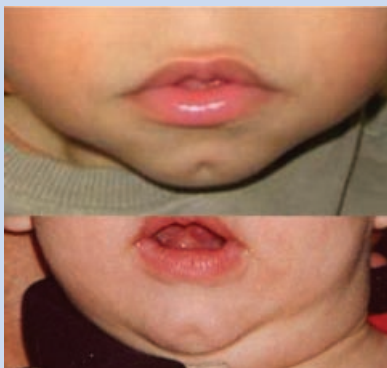

FIG. 64. *Chin dimple*. Note the midline depression of the skin over the fat pad of the chin.

Chin, Horizontal Crease

Definition: Horizontal crease or fold situated below the vermilion border of the lower lip and above the fatty pad of the chin, with the face at rest (Fig. 65). *subjective*

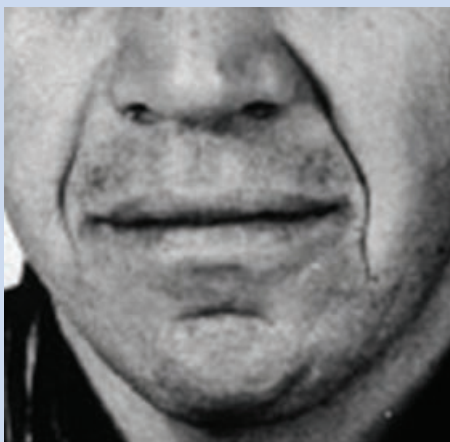

FIG. 65. *Chin, horizontal crease*. Note the horizontal crease or fold situated below the vermilion border of the lower lip and above the fatty pad of the chin.

Chin, H-Shaped Crease

Definition: H-shaped crease in the fat pad of the chin (Fig. 66). *subjective*

Comments: The H-shape must be distinguished from *Vertical crease of the chin*.

Synonym: Chin, H-shaped groove.

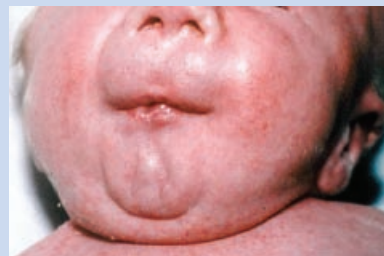

FIG. 66. *Chin, H-shaped crease*. Note the H-shaped crease in the fat pad of the chin.

Chin, H-shaped groove: See *Chin, H-shaped crease*

Chin, long: See *Chin, tall*

Chin, Pointed

Definition: A marked tapering of the lower face to the chin (Fig. 67). *subjective*

Comments: The two rami of the mandible meet at an acute angle.

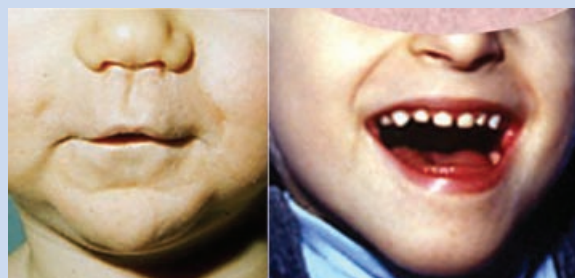

FIG. 67. *Chin, pointed*. Note the marked tapering of the lower face to the chin with the two sides of the mandible meeting at an acute angle.

Chin, Short

Definition: Decreased vertical distance from the vermilion border of the lower lip to the inferior-most point of the chin (Fig. 68). *subjective*

Comments: *Micrognathia* is used when the chin is both short (vertical dimension) and narrow (horizontal dimension).

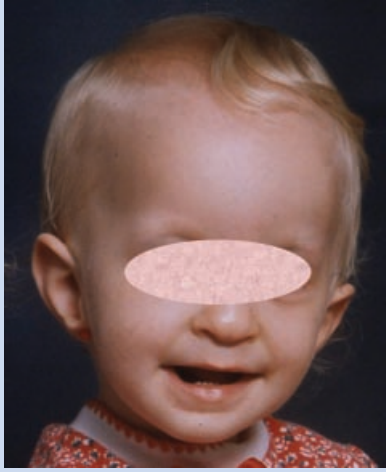

FIG. 68. *Chin, short*. Note the reduced vertical distance from the vermillion border of the lower lip to the inferior-most point of the chin.

Chin, Tall

Definition: Increased vertical distance from the vermillion border of the lower lip to the inferior-most point of the chin (Fig. 69). *subjective*

Synonym: Chin, long

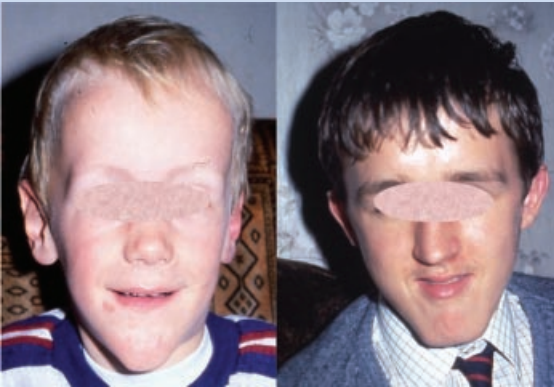

FIG. 69. *Chin, tall*. Note the increased vertical distance from the vermillion border of the lower lip to the inferior-most point of the chin.

Chin, Vertical Crease

Definition: Vertical crease in the fat pad of the chin with the face at rest (Fig. 70). *subjective*

Comments: A vertical crease must be distinguished from an *H-shaped crease of the chin*.

Replaces: Chin, cleft

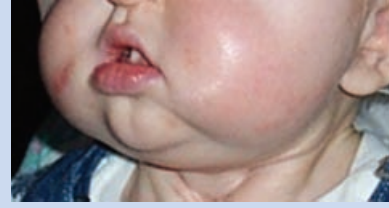

FIG. 70. *Chin, vertical crease*. Note the vertical crease in the fat pad of the chin.

NECK

Bull-neck: See *Neck, broad*

Neck, Broad

Definition: Increased width of the neck when viewed from the front or back (Fig. 71). *subjective*

Comments: Neck circumference may provide an objective measure of increase in width. Neck circumference is measured in a horizontal plane at the level of the most prominent portion of the thyroid cartilage, using a tape measure, with the head held erect and eyes facing forward. See *Neck webbing* for a related finding.

Synonyms: Neck, thick; Neck, wide

Replaces: Bull-neck

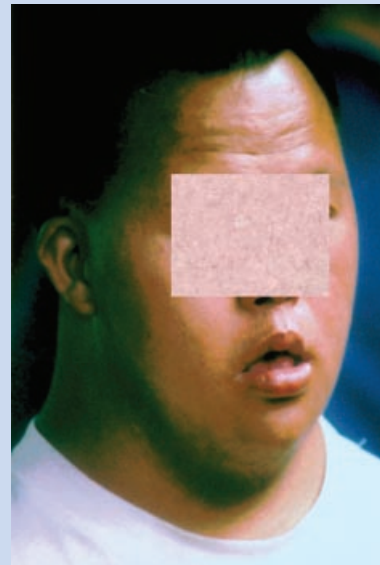

FIG. 71. *Neck, broad*. Note the increased width of the neck.

Neck, Long

Definition: Increased distance from the point where neck and shoulders meet to the inferior margin of the occipital bone (Fig. 72). *subjective*

Comments: No objective measure is available

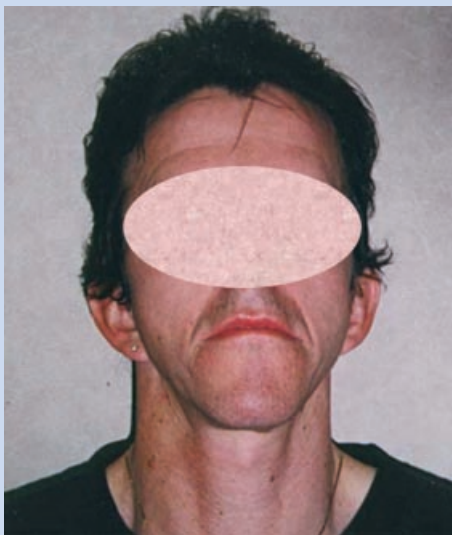

FIG. 72. *Neck, long*. Note the increased distance from the point where neck and shoulders meet to the inferior margin of the occipital bone.

Neck, Short

Definition: Decreased distance from the point where neck and shoulders meet to the inferior margin of the occipital bone (Fig. 73). *subjective*

Comments: No objective measure is available

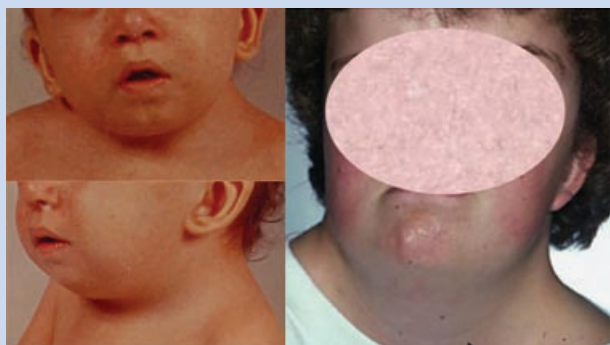

FIG. 73. *Neck, short*. Note the decreased distance from the point where neck and shoulders meet to the inferior margin of the occipital bone.

Neck, thick: See *Neck, broad*

Neck Webbing

Definition: A paravertically oriented fold of skin on the posterolateral aspect of the neck, usually extending from the mastoid region of the skull to the acromion, and best appreciated in frontal or posterior view (Fig. 74). *subjective*

Comments: This feature is often accompanied by a *Low posterior hairline*, but this should be coded separately.

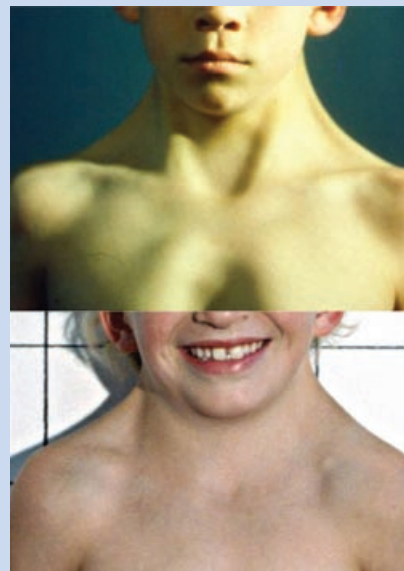


FIG. 74. *Neck webbing*. Note the bilateral folds of skin on the posterolateral aspect of the neck.

Synonym: Pterygium colli

Neck, wide: See *Neck, broad*

Nuchal Skin, Redundant

Definition: Excess skin around the neck, often lying in horizontal folds (Fig. 75). *subjective*

Comments: With age and increased vertical growth of the neck, excess nuchal skin may disappear and the neck may become broad or webbed. If the skin folds are vertical or paravertically, the term *Neck webbing* should be used.

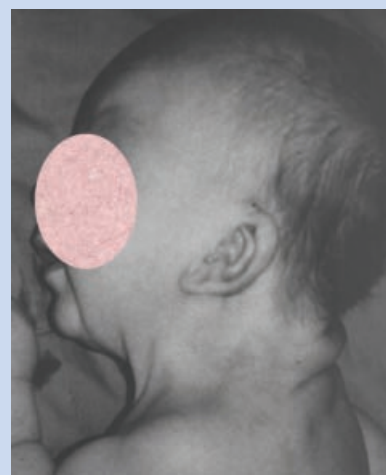

FIG. 75. *Nuchal skin, redundant*. Note the excess skin around the neck.

Pterygium colli: See *Neck webbing*

ACKNOWLEDGMENTS

We are grateful to Astrid Sibbes for drawing Figures 1–4. This paper was reviewed and edited by the co-Chairs of the International Dysmorphology Terminology working group (Judith Allanson, Leslie Biesecker, John Carey, and Raoul Hennekam). This review and editing was necessary to increase the consistency of formatting and content among the six manuscripts [Allanson et al., 2008; Biesecker et al., 2008; Carey et al., 2008; Hall et al., 2008; Hennekam et al., 2008; Hunter et al., 2008]. While the authors of the papers are responsible for the original definitions and drafting of the papers, final responsibility for the content of each paper is shared by the authors and the four co-Chairs.

REFERENCES

- Allanson JE, Biesecker LG, Carey JC, Hennekam RC. 2008. Elements of morphology: Introduction. *Am J Med Genet Part A* 149A:2–5.
- Biesecker LG, Aase JM, Clericuzio C, Gurrieri F, Temple K, Toriello H. 2008. Elements of morphology: Standard terminology for the hands and feet. *Am J Med Genet Part A* 149A:93–127.
- Carey JC, Cohen MM Jr, Curry C, Devriendt K, Holmes L, Verloes A. 2008. Elements of morphology: Standard terminology for the lips, mouth, and oral region. *Am J Med Genet Part A* 149A:77–92.
- Farkas LG. 1981. *Anthropometry of the head and face in medicine*. New York: Elsevier.
- Hall JG, Allanson JE, Gripp K, Slavotinek A. 2007. *Handbook of normal physical measurements*. 2nd edition. New York: Oxford University Press.
- Hall BD, Graham JM Jr, Cassidy SB, Opitz JM. 2008. Elements of morphology: Standard terminology for the periorbital region. *Am J Med Genet Part A* 149A:29–39.
- Hennekam RC, Cormier-Daire V, Hall J, Méhes K, Patton M, Stevenson R. 2008. Elements of morphology: Standard terminology for the nose and philtrum. *Am J Med Genet Part A* 149A:61–76.
- Hunter AGW, Frias F, Gillissen-Kaesbach G, Hughes HE, Jones KL, Wilson L. 2008. Elements of morphology: Standard terminology for the ear. *Am J Med Genet Part A* 149A:40–60.