

EDITOR'S NOTE

The following article by Hennekam and colleagues represents the latest contribution to the *Elements of Morphology* series. The authors propose standard terminology for the male and female genitalia. Like the other articles in the *Elements* series, this paper is

available through free access online at the Wiley Online Library page for the *American Journal of Medical Genetics*.

John C. Carey
Editor-in-chief

Elements of Morphology: Standard Terminology for the External Genitalia

Raoul C.M. Hennekam,^{1*} Judith E. Allanson,² Leslie G. Biesecker,³ John C. Carey,⁴ John M. Opitz,⁴ and Eric Vilain⁵

¹Department of Pediatrics and Clinical Genetics, Academic Medical Center, University of Amsterdam, Amsterdam, The Netherlands

²Department of Genetics, Children's Hospital of Eastern Ontario, Department of Pediatrics, University of Ottawa, Ottawa, Canada

³National Human Genome Research Institute, National Institutes of Health, Bethesda, Maryland

⁴Division of Medical Genetics, Human Genetics, Pathology, Obstetrics and Gynecology, University of Utah, Salt Lake City, Utah

⁵Departments of Human Genetics, Pediatrics and Urology, David Geffen School of Medicine, UCLA, Los Angeles, California

Manuscript Received: 9 November 2012; Manuscript Accepted: 25 January 2013

An international group of clinicians working in the field of dysmorphology has initiated the standardization of terms used to describe human morphology. The goals are to standardize these terms and reach consensus regarding their definitions. In this way, we will increase the utility of descriptions of the human phenotype and facilitate reliable comparisons of findings among patients. Discussions with other workers in dysmorphology and related fields, such as developmental biology and molecular genetics, will become more precise. Here we introduce the anatomy of the male and female genitalia, and define and illustrate the terms that describe the major characteristics of these body regions. Published 2013. This article is a U.S. Government work and is in the public domain in the USA.

Key words: nomenclature; definitions; ontology; genitalia; male genitalia; female genitalia; anatomy; anthropometry; morphology; dysmorphology

INTRODUCTION

General

This paper is part of a series of papers defining the morphologic variations of the human body detectable by surface examination [Biesecker et al., 2009; Carey et al., 2009; Hall et al., 2009; Hennekam et al., 2009; Hunter et al., 2009; Allanson et al., 2009b]. Additional papers on the morphology of the limbs and trunk are in preparation. The series is accompanied by an introductory paper describing general aspects of this project [Allanson et al., 2009a].

How to Cite this Article:

Hennekam RCM, Allanson JE, Biesecker LG, Carey JC, Opitz JM, Vilain E. 2013. Elements of morphology: Standard terminology for the external genitalia. *Am J Med Genet Part A* 161A:1238–1263.

The reader is encouraged to consult the introduction when using the definitions.

MALE EXTERNAL GENITALIA

Anatomy of the Male External Genitalia

The normal anatomy of the male external genitalia is shown in Figures 1 and 2. Some anatomical landmarks deserve specific mention as these are not used consistently.

Grant sponsor: NIH; Grant number: # 1 R01 HD068138; Grant sponsor: Intramural Research Program of the National Human Genome Research Institute.

*Correspondence to:

Dr. R.C. Hennekam, Department of Pediatrics, Academic Medical Center, Floor H7-236, Meibergdreef 9, 1105 AZ Amsterdam, The Netherlands.

E-mail: r.c.hennekam@amc.uva.nl

Article first published online in Wiley Online Library (wileyonlinelibrary.com): 6 May 2013

DOI 10.1002/ajmg.a.35934

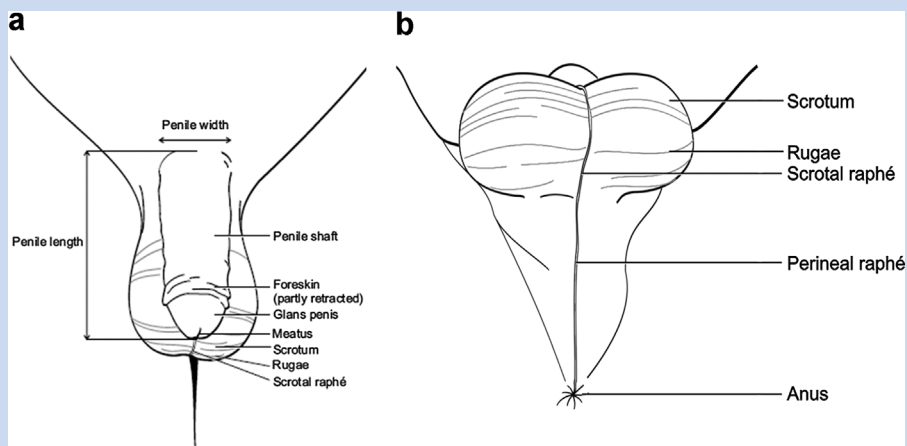


FIG. 1. Anatomy of external male genitalia. a: Anterior overview. b: Inferior overview.

Penile shaft: the part of the penis running from the abdominal wall to the corona.

Penile raphé: slightly elevated line of tissue on the ventral aspect of the shaft of the penis, continuing on to the foreskin.

Corona: a semi-circular prominence of the glans of the penis, situated on the dorsum of the penile shaft. In a flaccid penis it is usually covered by the foreskin except in men who have been fully circumcised.

Glans penis: the rounded tip of the penis, demarcated from the shaft by the sulcus. In a flaccid penis it is usually covered by the foreskin except in men who have been fully circumcised.

Meatus: a slit-like opening on the tip of the glans of the penis, running in a ventral–dorsal direction.

Urethral raphé: a slightly elevated ridge of skin extending from the ventral aspect of the meatus to the frenulum.

Foreskin: a loose fold of skin (outer) and mucous membrane (inner) arising from the shaft of the penis, and in a flaccid penis usually covering the glans. In young boys, the demarcation of the foreskin and glans is often not fully formed, prohibiting retraction of the foreskin below the corona.

Frenulum of the foreskin: a band of elastic tissue covered by mucous membrane on the ventral side of the penis attaching the foreskin to the glans of the penis.

Scrotum: a loose sac of skin containing the testes and located inferior to the base of the penis. Scrotal skin has small elevations (rugae) on the surface and is more pigmented than the remainder of the body, irrespective of ethnic background, although this distinction is more obvious in individuals with a dark skin.

Scrotal raphé: a slightly elevated ridge of tissue running from the base of the penis to the midline of the perineum. The scrotal raphe is in continuity with the penile raphé superiorly and the perineal raphé inferiorly. Slight hyperpigmentation of the genital raphés (penile, scrotal, and perineal) is almost invariably present.

Perineal raphé: a slightly elevated ridge of tissue in the midline of the perineum running from the inferior attachment of the scrotum to the anus and in continuity with the scrotal raphé.

Testis: a mobile ovoid-shaped organ palpable and usually partly visible through the skin of the scrotum.

Epididymis: an oblong organ attached to the testis. The epididymis can be visualized by trans-illumination and is palpable in the scrotum.

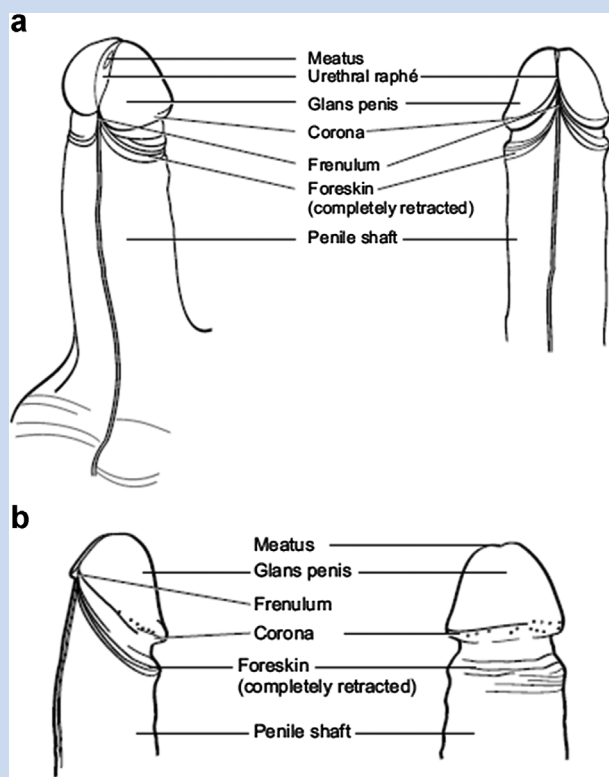


FIG. 2. Anatomy of external male genitalia. a: Anterior and side view of the penis with the prepuce removed. b: Detailed side and posterior view of the penis with the prepuce removed.

Pubertal Stages

The timing of puberty varies greatly in the general population and is influenced by genetic and environmental factors [Gajdon et al., 2009]. In evaluating the pubertal development in a child, ethnic background and intra-familial variation should be taken into account. Tanner stages are commonly used to score pubertal development [Tanner, 1986]. In males, the stages are determined by assessing the length and width of the penis, size of the testes, and pubic hair growth (Fig. 3). As each of these components is defined here separately, the pubertal stages are not discussed in further detail.

Measurements of the Male External Genitalia

Measurements of the penis are possible using sliding calipers or a straight-edged plastic ruler. The reliability of measurements using a tape measure is poor. Penile length is measured from the base of the gently stretched penis at the pubic symphysis to the tip of the glans without including the foreskin. Fat pads at the base of the penis

influence this measurement and the ruler should be pressing against the pubic symphysis. Determining of the size of the testes are performed either by estimation of the size of the testes by palpation and comparison with a Prader orchidometer (Fig. 4), or by measuring width and length of the testis using calipers, straight ruler, or tape measure. Results of measurements determined by calipers, rulers or tape measures typically yield larger estimates of the testicular volume than those by Prader orchidometers, and, over time, measurements in individual patients should be performed using the same method.

The reader is referred to the Handbook of Normal Physical Measurements [Hall et al., 2007] for detailed descriptions of measurement techniques and growth standards. Except for pubertal developmental stages, growth standards are provided for Caucasians of Northern European extraction only, but abundant data on penile growth in individuals of other ethnic backgrounds have been published.

Anatomical Variation

Variations of the anatomy of the male external genitalia may be assessed as quantitative (objective or anthropometric) traits and qualitative (subjective or categorical) features:

1. Variations in length: long penis; short penis.
2. Variations in width: wide penis; narrow penis.
3. Variations in length and width: absent penis; absent foreskin; small scrotum; absent scrotum, (apparently) absent testis; small testis; large testis; supernumerary testis.
4. Variations in shape or position: ambiguous genitalia; bladder exstrophy, bifid penis; penile torsion, epispadias; hypospadias; microphallus; penile chordee; webbed penis; penoscrotal transposition; accessory scrotum, bifid scrotum; shawl scrotum; ectopic scrotum, cryptorchidism; hydrocele.
5. Variations in cutaneous manifestations: freckled genitalia; hyperpigmented genitalia; hypopigmented genitalia; sparse pubic hair.

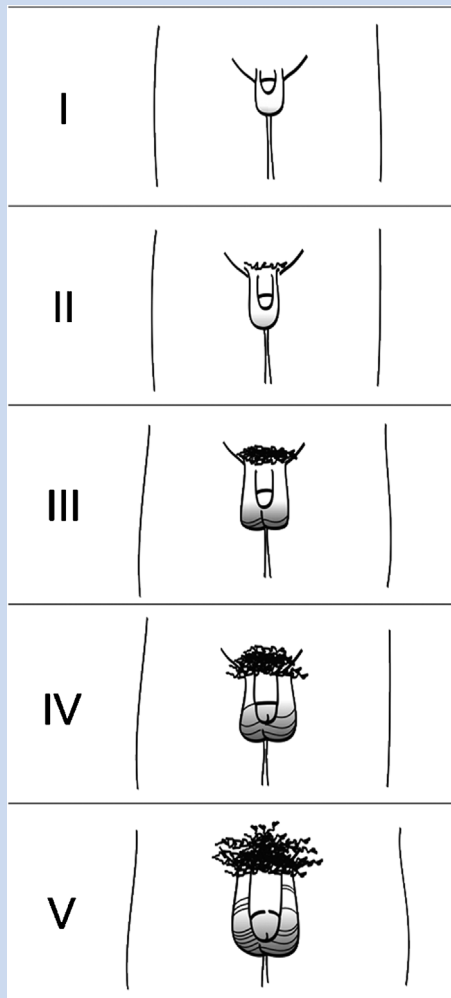


FIG. 3. Puberty stages males according to Tanner [1986].




FIG. 4. Prader orchidometer.

The various findings are listed alphabetically. If a feature is indicated in ***bold-italics***, the feature is listed and a definition is available. The terms are alphabetized based on the physical feature, not the modifier.

Investigating the genitalia should always be performed with the observed person in a relaxed position. The presence of a nurse or parent is advisable. Small children are best investigated in their parent's lap. The testes can be palpated in a supine position but it may be useful to ask the observed person to squat as this allows better palpation. Repeat genital examinations may be embarrassing for the subject [Lee et al., 2006] and should be performed only when indicated.

DEFINITIONS

Anorchia: See ***Testis, (apparently) absent***

Aphallia: See ***Penis, absent***

Aposthia: See ***Foreskin, absent***

Bladder, Exstrophy

Definition: Eversion of the posterior bladder wall through the congenitally absent lower anterior abdominal wall and anterior bladder wall (Fig. 5). *objective*

Comments: Exstrophy of the bladder can be associated with ***Epispadias*** and ***Bifid penis*** or in females with ***Bifid clitoris***, a bifid uterus, and a ***Septated vagina***, each of which should be coded separately.

Chordee

Definition: Ventral, lateral, or ventrolateral bowing of the shaft and glans penis of more than 30 degrees (Fig. 6). *objective*

Comments: The degree of variation of penis curvature is a continuum, but traditionally 30 degrees is considered the threshold for surgical intervention on chordee [Bologna et al., 1999]. Bowing usually becomes more obvious in an erect penis, but is frequently also palpable when stretching a flaccid penis. Chordee can be congenital or acquired; if the former, it can be associated with ***Webbed Penis*** or ***Hypospadias***, which should be coded separately.

Cryptorchidism

Definition: Testis in inguinal canal. *objective*

Comments: The gonad is mobile and can be retracted superiorly by the cremaster muscle reflex stimulated, for instance, by cold or touch. A retracted testis is not cryptorchidism. An abdominal testis cannot be distinguished by physical examination from an (***Apparently***) ***absent testis*** and requires radiological (or, rarely, surgical) procedures for assessment.

Synonym: Testis, undescended

Diphallus: See ***Penis, bifid***

Epispadias

Definition: Dorsal placement of the urethral opening (Fig. 7). *objective*

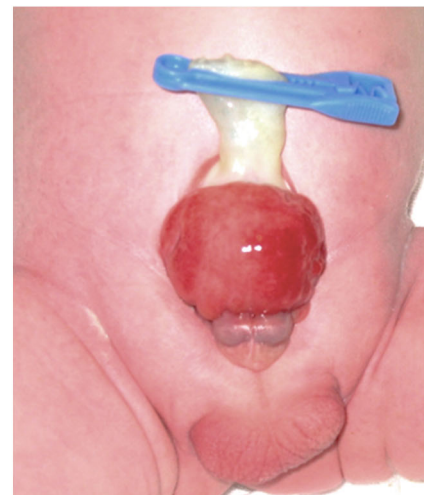
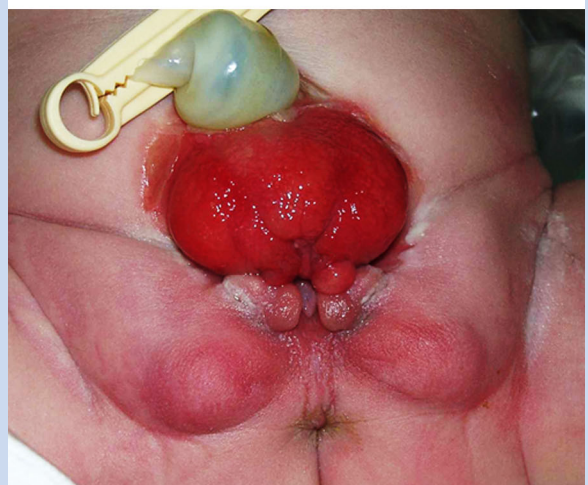
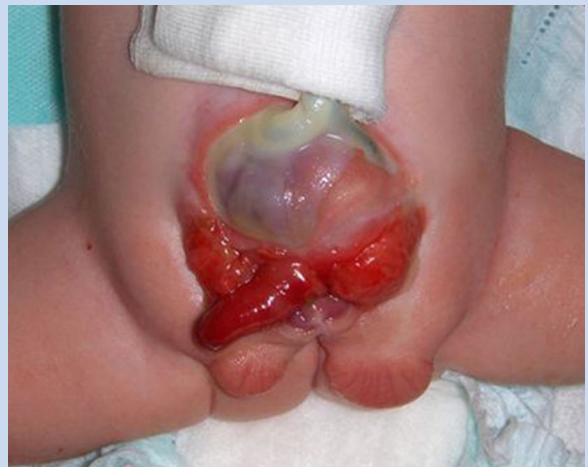

FIG. 5. Bladder exstrophy. Courtesy of Dr. Anne-Karoline Ebert. Reprinted with permission from Ebert et al. [2009].

Comments: Epispadias may be present in a phenotypic male, female, or an individual with ambiguous genitalia. A meatus in a phenotypic male may be positioned either on the glans (glandular or balanic epispadias), the shaft (penile epispadias) or at the

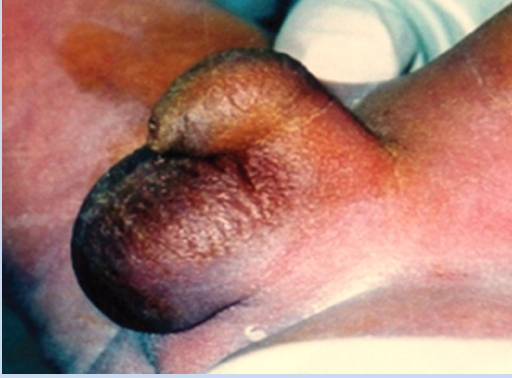

FIG. 6. Chordee. Courtesy of Dr. Montasser El-Koutby. Reprinted with permission from El-Koutby and El Gohary [2010].

attachment of the penis to the abdominal wall (penopubic epispadias). Alternatively, the urethra may be an open groove along the dorsal shaft of the penis, with no readily recognized meatus. Epispadias is a frequent component of *Bladder exstrophy*, but should be coded separately.

Foreskin, Absent

Definition: Complete absence of the foreskin (Fig. 8). *objective*

Comments: Absence of the foreskin can be accompanied by *Cryptorchidism* and *Hypospadias*, which should be coded separately.

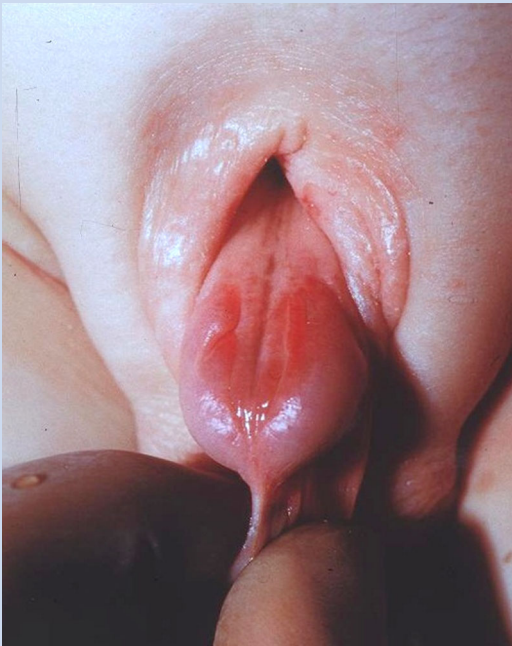

FIG. 7. Epispadias. Courtesy of Dr. Anne-Karoline Ebert. Reprinted with permission from Ebert et al. [2009].

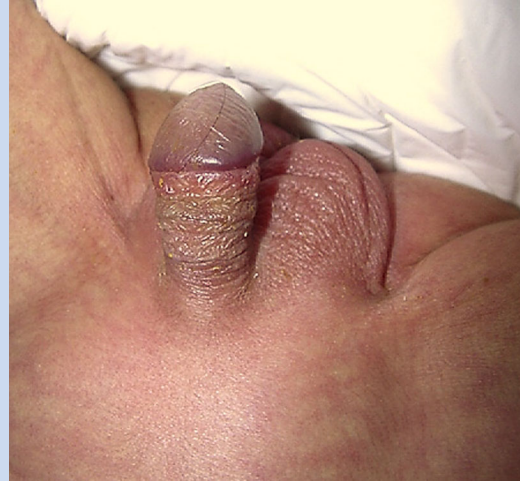

FIG. 8. Foreskin, absence. Courtesy of Dr. S. Sadeghipour and Dr. N. Esmailzadehha. Reprinted with permission from Sadeghipour and Esmailzadehha [2010].

Synonym: Aposthia

Foreskin, aposthia: See *Foreskin, absent*

Genitalia, Ambiguous

Definition: External genitalia without typical male or female appearance (Fig. 9). *subjective*

Comments: Note that this term can include or combine variations in size and shape, with partial or complete absence of structures. It is preferable to describe the individual components, which are defined below. It is nonetheless a widely used bundled term and as such is retained here (for the definition of a “bundled term” see Allanson et al. [2009a]). The distinction of this finding from a marked degree of *Hypospadias* is an example of how this term can be problematic.

Synonym: Intersex genitalia

Genitalia, ephelides: See *Genitalia, freckled*

Genitalia, Freckled

Definition: One or more brown punctate macules on the skin of the genitalia (Fig. 10). *objective*

Comments: This should be differentiated from *Hyperpigmented genitalia* in which an area larger than a freckle or the complete external genitalia are hyperpigmented. The description should be qualified by a description of the affected part(s).

Synonym: Genitalia, ephelides

Genitalia, Hyperpigmented

Definition: Localized or generalized increased genital pigmentation (Fig. 11). *subjective*

Comments: This is an assessment of the relative pigmentation of the genitalia compared to the overall pigmentation of the individ-

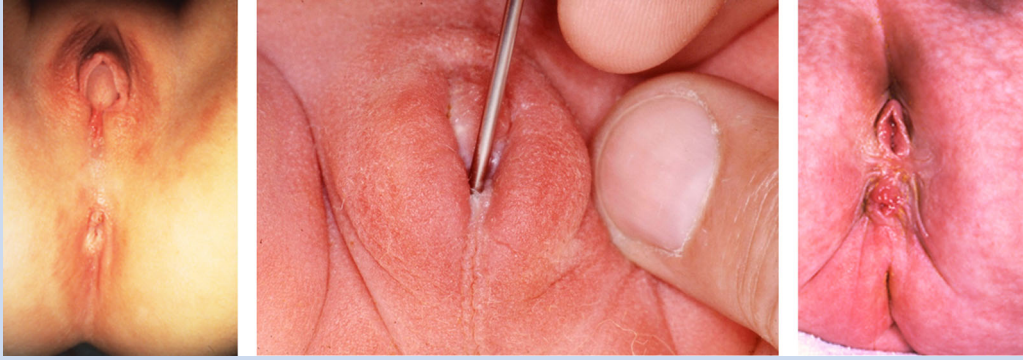

FIG. 9. Ambiguous genitalia.

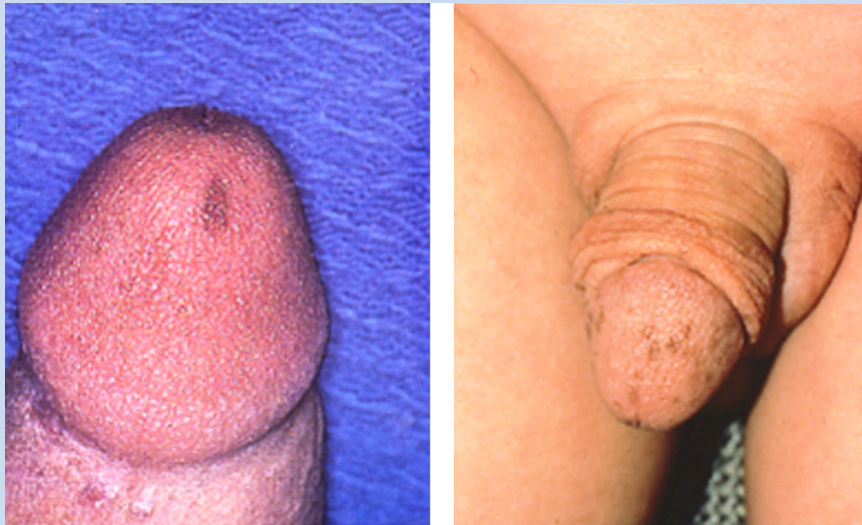

FIG. 10. Freckled genitalia.

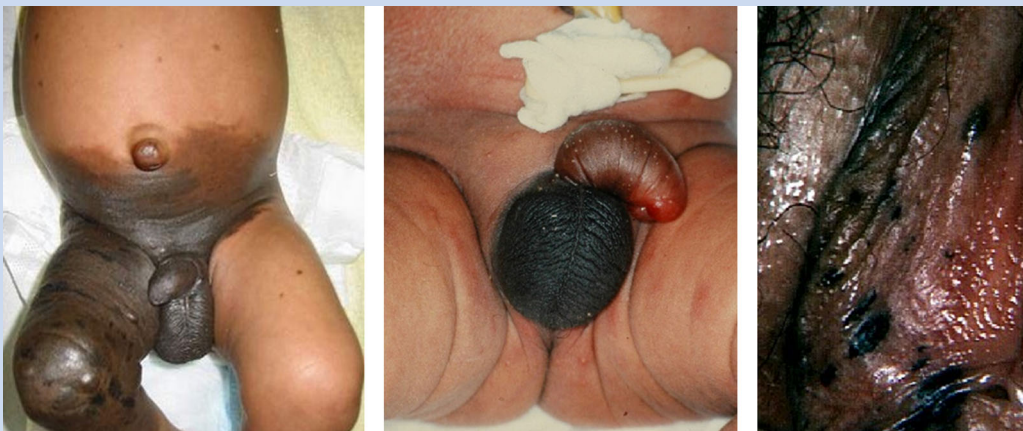

FIG. 11. Hyperpigmented genitalia in males (left and middle) and female (right).

ual. Hyperpigmentation can affect other parts of the body or be restricted to the genitalia. Genital hyperpigmentation can be generalized or localized. Localized areas of hyperpigmentation of the glans of the penis are especially common. This should be differentiated from **Freckled genitalia** in which one or more small, focal areas of hyperpigmentation are present. Localized hyperpigmentation can be objectively determined due to the difference from the immediate surrounding tissue color, while generalized hyperpigmentation may be more difficult to determine and is therefore a subjective manifestation. If the finding is localized, the description should be appended with a description of the affected part(s).

Replaces: Penile melanosis

Genitalia, Hypopigmented

Definition: Localized or generalized decreased genital pigmentation (Fig. 12). *subjective*

Comments: This is an assessment of the relative pigmentation of the genitalia compared to the overall pigmentation of the individual. Hypopigmentation can affect other parts of the body or be restricted to the genitalia. Genital hypopigmentation can be generalized or localized. Localized hypopigmentation can be objectively determined due to the difference from the immediate surrounding tissue color, while generalized hypopigmentation may be more difficult to determine and is therefore a subjective manifestation.

Genitalia, intersex: See **Genitalia, ambiguous**

Hydrocele

Definition: Presence of increased fluid around testis leading to an enlarged scrotum or hemiscrotum (Fig. 13). *Subjective*

Comments: The testis itself may not be palpable in the presence of large fluid amounts. The assessment of this finding may be aided by trans-illumination.

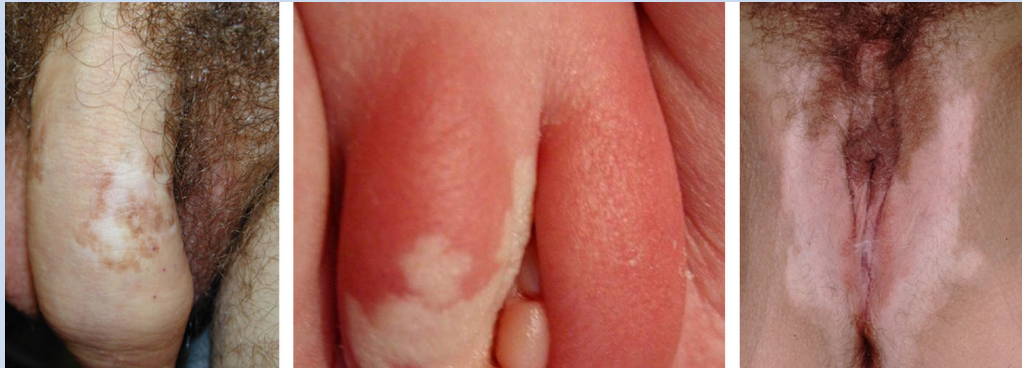

FIG. 12. Hypopigmented genitalia in male (left) and females (middle and right).

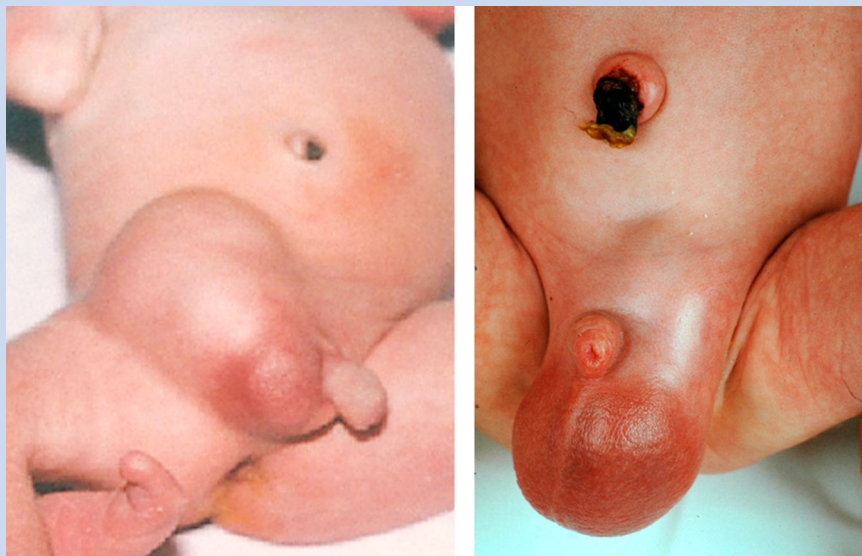


FIG. 13. Hydrocele.

Hypospadias

Definition: Ventral placement of the urethral opening (Fig. 14). *objective*

Comments: Hypospadias is categorized in several ways, the most classical one being first degree (urethral opening on the ventral glans), second degree (urethral opening on the ventral shaft), and third degree (urethral opening on the perineum). Second degree hypospadias is frequently accompanied by *Chordee* of the penis, which should be coded separately. The widely used Duckett classification [Baskin and Duckett, 1996] categorizes hypospadias into glandular, coronal, distal penile shaft (or “anterior”) subgroup, mid-shaft (or “middle”) subgroup, or proximal penile shaft, penoscrotal, and perineal (or “posterior”) subgroup. A surgically oriented categorization to classify hypospadias has been developed based on the position of the division of the corpus spongiosum relative to the penile shaft and bony structures of the pelvis [Orkiszewski, 2012].

Macro-orchidism: See *Testis, large*

Macropenis: See *Penis, long*

Megalopenis: See *Penis, long*

Micropenis: See *Penis, short*

Microphallus

Definition: Length of penis more than 2 SD below the mean for age accompanied by hypospadias (Fig. 15). *objective* OR

Apparently decreased length of penis for age with hypospadias. *Subjective*

Comments: Traditionally a distinction is made between a *Short penis*, a short penis with otherwise normal anatomy, versus *microphallus*, a short penis with hypospadias. Penile length is the distance between the midline attachment of the gently stretched, flaccid penis above the pubic symphysis and tip of the glans. Details on measurement of the penis can be found elsewhere [Hall et al., 2007]. There are no reliable studies showing a relation between ethnicity and penile length [Adams, 1996]. There are some data on interethnic differences in the lower limit of penile length in newborns

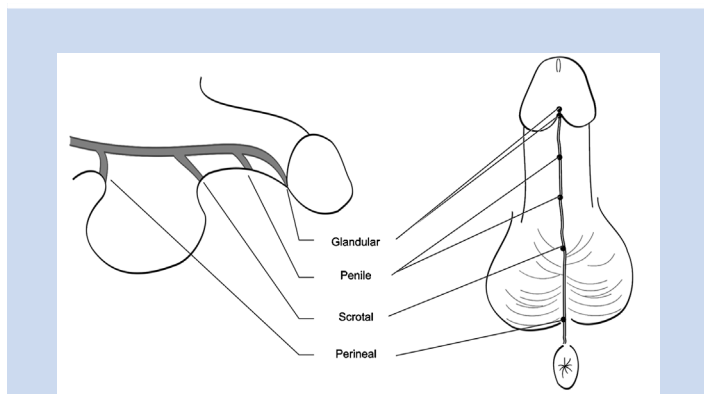


FIG. 14. Various forms of hypospadias. There are various classification systems (see text).

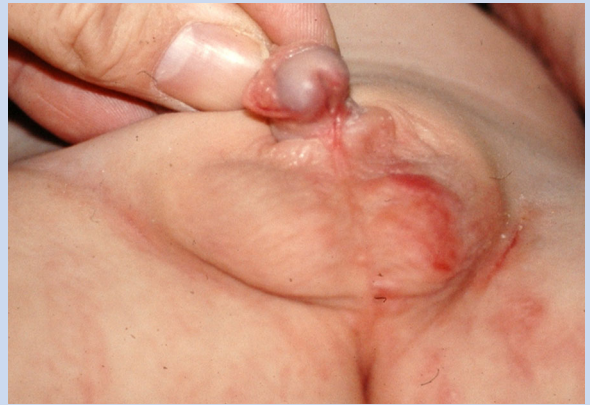

FIG. 15. Microphallus.

[Cheng and Chanoine, 2001]. A short penis should be differentiated from an inconspicuous penis, for instance due to excessive suprapubic fat (“buried”) [Bergeson et al., 1993]. We also recognize that shortness of a penis is defined by some subspecialists as penile length more than 2.5 SD below the mean.

Replaces: Penis, hypoplastic; Penis, hypotrophic; Penis, small

Penile melanosis: See *Genitalia, hyperpigmented*

Penis, Absent

Definition: Lack of recognizable penile structures (Fig. 16). *objective*

Comments: Absence of the penis is always accompanied by abnormal position of the meatus (usually in the perineum, sometimes in the rectum), may be accompanied by *Cryptorchidism* [Chibber et al., 2005], and is often associated with non-genital anomalies [Roth et al., 1981], which all should be coded separately. Absent penis should be differentiated from a penis concealed within pre-pubic fat tissue.

Synonym: Aphallia

Penis, Bifid

Definition: Two penile structures, separated from the tip to the base of the shaft (Fig. 17). *Objective* OR

Longitudinal indentation, cleft, or depression of the glans with or without involvement of the shaft of the penis. *Objective*

Comments: Note the second definition denotes a bundled term, but as it is commonly used in practice it is kept here. In individuals with complete duplication often one will find *Hypospadias*, *Epispadias*, *Bladder exstrophy*, or *Bifid scrotum*, which should be coded separately, as well as urinary tract duplications, renal anomalies, and gastrointestinal duplications [Keckler et al., 2009]. The terms indicate the presence of (part of) two penises, but do not indicate whether they are caused by splitting or double formation.

Synonym: Diphallus; Penis, duplicated

Penis, duplicated: See *Penis, bifid*

Penis, hyperplastic: See *Penis, long*

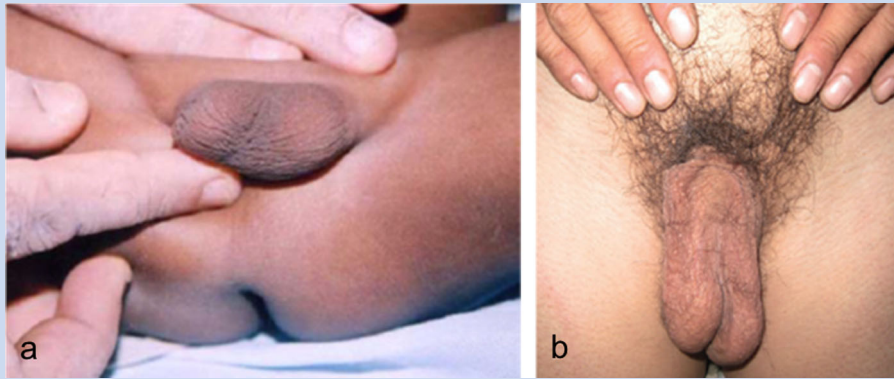


FIG. 16. Absent penis. Courtesy of Dr. Ruchi Gupta (panel A) and Dr. Li Fubiao (panel B). Panel A reprinted with permission from Rattan et al. [2010]. Panel B reprinted with permission from Wang et al. [2011].

Penis, hypertrophic: See *Penis, long*

Penis, hypoplastic: See *Penis, short*

Penis, hypotrophic: See *Penis, short*

Penis, large: Not defined as this is a bundled term encompassing both a *Long penis* and *Wide penis*

Penis, Long

Definition: Penile length more than 2 SD above the mean for age (Fig. 18). *objective* OR

Apparently increased penile length for age. *Subjective*

Comments: Penile length is the distance between the midline attachment of the gently stretched, flaccid penis above the pubic symphysis and tip of the glans. Details on measurement of the penis can be found elsewhere [Hall et al., 2007]. This measurement and

assessment may not be possible for an individual with *Chordee*. There are no reliable studies showing a relation between ethnicity and penile length [Adams, 1996].

Replaces: Penis, hyperplastic; Penis hypertrophic; Megalopenis; Macropenis; Penis, large

Penis, Narrow

Definition: Penile width more than 2 SD below the mean for age. *objective* OR

Circumference of the flaccid penis more than 2 SD below the mean for age. *objective* OR

Apparently decreased penile width for age. *subjective*

Comments: Penile width is the distance between left and right side of the flaccid penis at the attachment to the skin above the pubic symphysis. Normal values for penile width only exist for newborns [Cheng and Chanoine, 2001] and adults [Schneider et al., 2001].

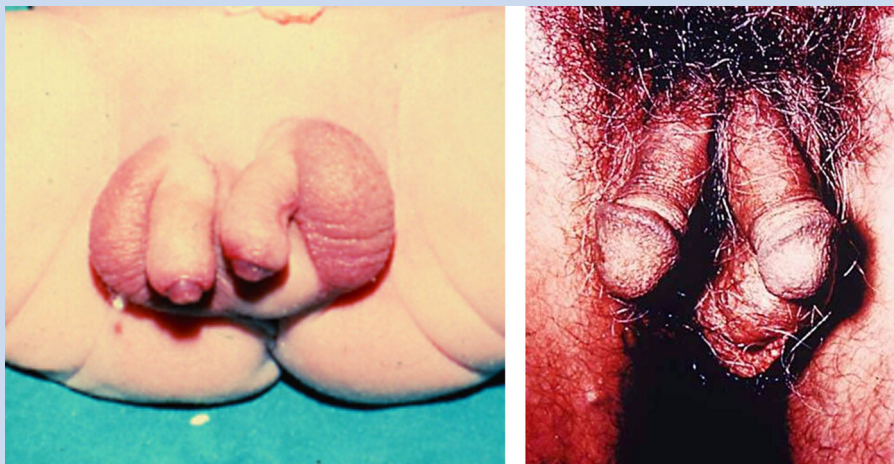


FIG. 17. Bifid penis.

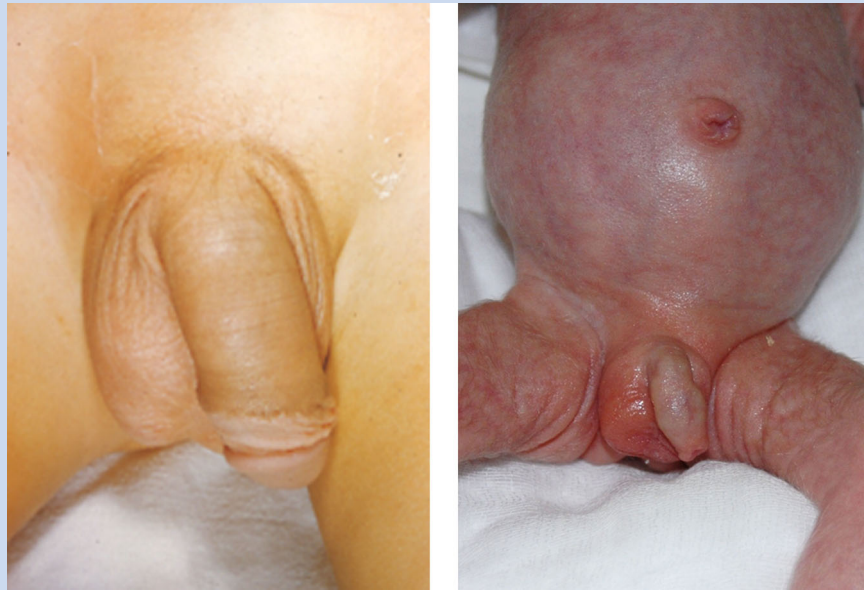

FIG. 18. Long penis (in newborn children).

Alternatively, penile circumference can be measured, as normal values are available at all ages [Damon et al., 1990]. Note the site of measurement (base; mid-shaft; under glans) may differ in the various studies [Ajmani et al., 1985; Ponchiotti et al., 2001; Cinaz et al., 2012]. It is important that the measurement site be consistent with that of the published norms.

Penis, Short

Definition: Penile length more than 2 SD below the mean for age (Fig. 19). *objective* OR

Apparently decreased penile length for age. *subjective*

Comments: Traditionally a distinction is made between micropenis, a short penis with otherwise normal anatomy versus

Microphallus, a short penis with hypospadias. Penile length is the distance between the midline attachment of the gently stretched, flaccid penis above the pubic symphysis and tip of the glans. Details on measurement of the penis can be found elsewhere [Hall et al., 2007]. There are no reliable studies showing a relation between ethnicity and penile length [Adams, 1996]. There are some data on interethnic differences in the lower limit of penile length in newborns [Cheng and Chanoine, 2001]. A short penis should be differentiated from an inconspicuous penis, for instance due to excessive suprapubic fat (“buried”) [Bergeson et al., 1993]. Micropenis (or small penis) is sometimes used as a bundled term for short and narrow penis. We recommend that the term not be used in this way and that narrowness be coded separately. We also recognize that shortness of a penis is defined

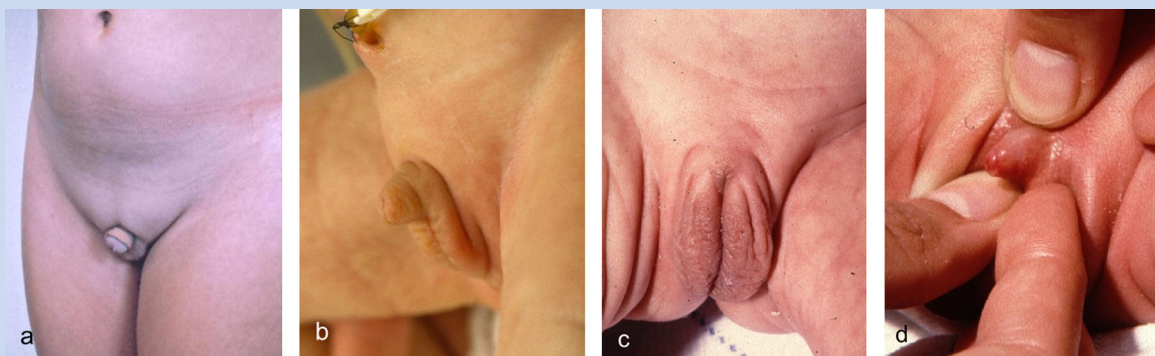


FIG. 19. Short penis. Please note that on panel C the penis seems to be absent, but can be made visible in the same patient in panel D by pushing surrounding tissues backward.

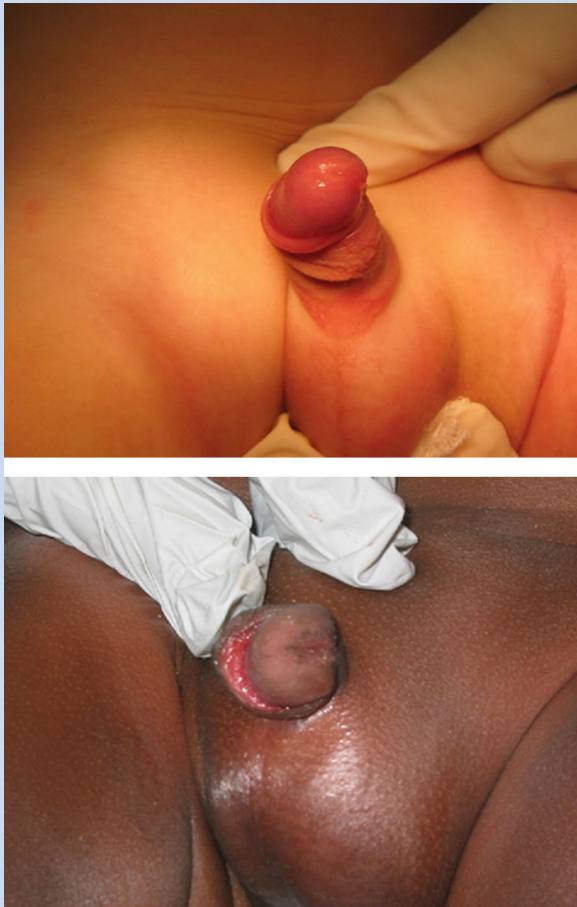

FIG. 20. Torsion of the penis. Courtesy of Dr. Barry Kogan. Reprinted with permission from Bauer and Kogan [2009].

Penis, small: Not defined as this is a bundled term encompassing both *Short penis* and *Narrow penis*.

Penis, Torsion of the

Definition: Rotated position of the glans, with or without the penile shaft, of 30 degrees or more (Fig. 20). *objective*

Comments: Penile torsion is defined traditionally as being between 30 and 180 degrees rotation [Montag and Palmer, 2011]. Penile torsion is usually counter clockwise and is often associated with *Chordee* and *Hypospadias*, which should be coded separately.

Penis, Webbed

Definition: Ventral skinfold extending from penis to scrotum (Fig. 21). *objective*

Comments: The distal limit of the skinfold can be located on the penile shaft or the tip of the penis. Webbing has been subclassified into a primary form and secondary form (for instance after circumcision) [El-Koutby and Amin el Gohary, 2010] and may be accompanied by *Chordee*, which should be coded separately.

Penis, Wide

Definition: Distance between left and right side of the flaccid penis at the attachment to the skin above the pubic symphysis more than 2 SD above the mean for age (Fig. 22). *objective* OR

Circumference of the flaccid penis more than 2 SD above the mean for age. *objective* OR

Apparently increased distance for age between the left and right side of the flaccid penis at the attachment to the skin above the pubic symphysis. *subjective*

Comments: Normal values for penile width only exist for newborns [Cheng and Chanoine, 2001] and adults [Schneider et al., 2001]. Alternatively penile circumference can be measured, as normal values are available at all ages [Damon et al., 1990]. Note the site of measurement (base; mid-shaft; under glans) may differ in

by some subspecialists as penile length more than 2.5 SD below the mean.

Synonym: Micropenis

Replaces: Penis, hypoplastic; Penis, hypotrophic; Penis, small

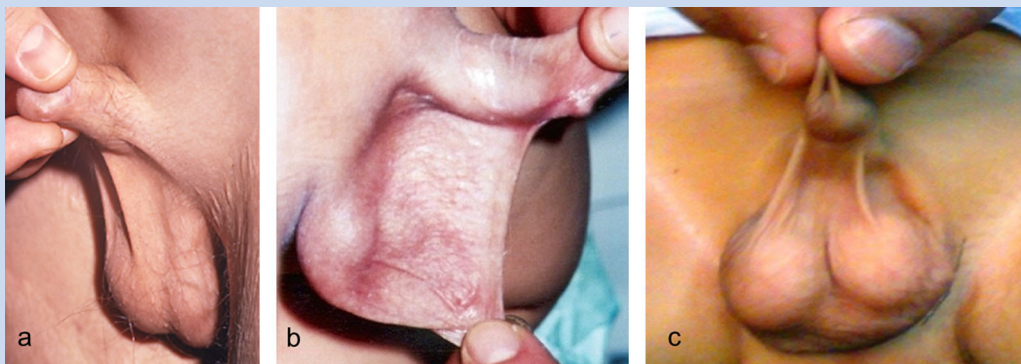

FIG. 21. Webbed penis. Panels B and C courtesy of Dr. Montasser El-Koutby. Reprinted with permission from El-Koutby and El Gohary [2010].

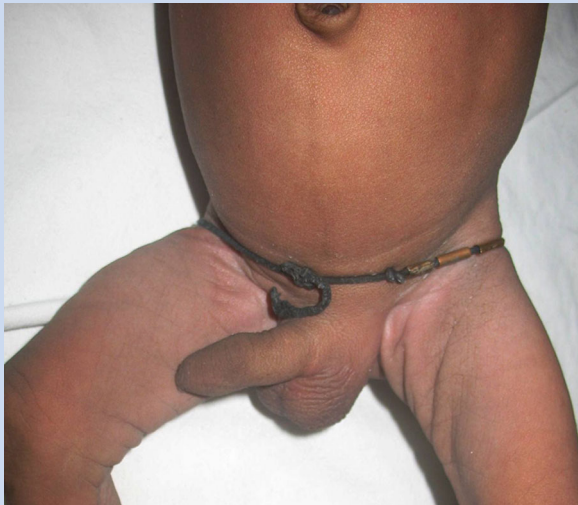

FIG. 22. Wide penis (newborn child). Courtesy of Dr. Sheela Nampoothiri.

the various studies [Ajmani et al., 1985; Ponchiotti et al., 2001; Cinaz et al., 2012]. It is important that the measurement site be consistent with that of the published norms.

Penoscrotal transposition

Definition: Positioning of the scrotum superior to the penis (Fig. 23). *objective*

Comments: The base of the penis is entirely covered by the *scrotum*, which may be *Bifid*. If so, this should then be coded separately. If only part of the scrotum is located superior to the penis, the term *Overriding scrotum* is used instead.

Synonyms: Prepenile scrotum

Replaces: Doughnut scrotum

Polyorchidism: See *Testis, supernumerary*

Pubic hair, hypotrichosis of: See *Pubic hair, sparse*

Pubic hair, Sparse

Definition: Apparently decreased number of hairs per unit area relative to the pubertal development as judged by other components of pubertal maturity (Fig. 24) *subjective*

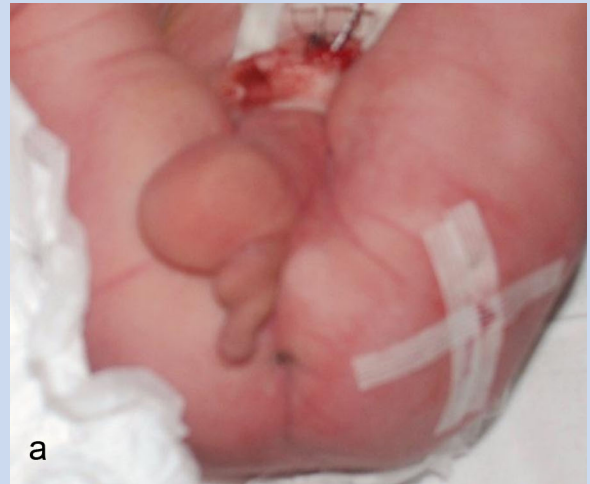Comments: (Pubic) hypotrichosis should not be used as a synonym as, formally, it means underdevelopment of the hair. No normal values for the number of hairs per unit area exist.

Replaces: Pubic hair, thinning; Pubic hair, thin; Pubic hypotrichosis

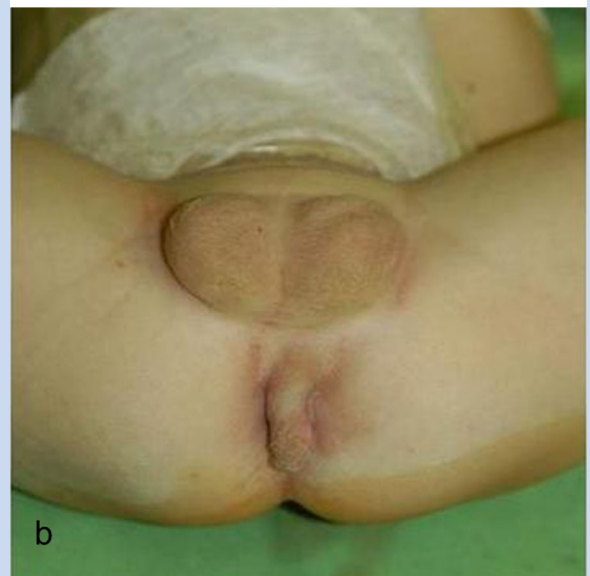
Pubic hair, thin(ning): See *Pubic hair, sparse*

Scrotum, Absent

Definition: Absence of scrotal sac (Fig. 25). *objective*



a



b

FIG. 23. Penoscrotal transposition. Courtesy of Dr. Trine Prescott and Dr. Kathrine Bjørge (panel A) and Dr. Khaled Fathi (panel B). Panel B reprinted with permission from Fathi et al. [2010].

Comments: Both the sac and rugae are absent. This finding may be accompanied by an (*Apparently*) *absent testis* and *Cryptorchidism* [Janoff and Skoog, 2005], which should be coded separately.

Scrotum, Accessory

Definition: Additional scrotum, or part of a scrotum in an abnormal location (Fig. 26). *objective*

Comments: An accessory scrotum is typically located on the perineum, frequently associated with perineal lipoma, and occasionally with *Hypospadias* or *Bifid penis*, which should be coded separately.

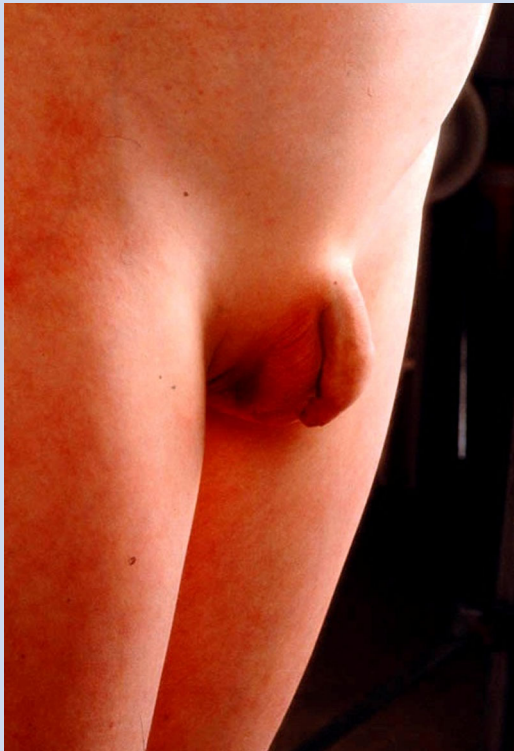


FIG. 24. Sparse pubic hair (in a pubertal male).

Scrotum, Bifid

Definition: Midline indentation or cleft of the scrotum (Fig. 27). *objective*

Comments: A testis may or may not be present in each half of the scrotum.

Scrotum, doughnut: See *Penoscrotal transposition*

Scrotum, Ectopic

Definition: Scrotum in a position other than the usual position inferior to the base of the penis (Fig. 28). *objective*

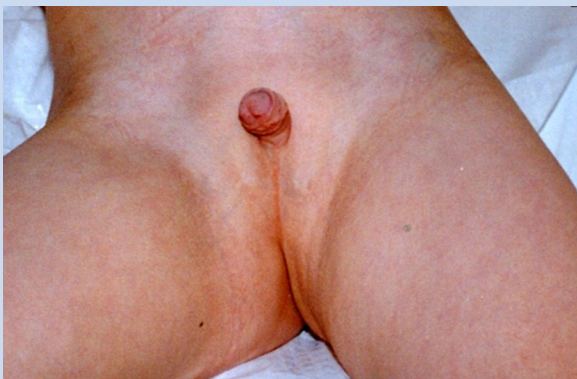

FIG. 25. Absent scrotum.

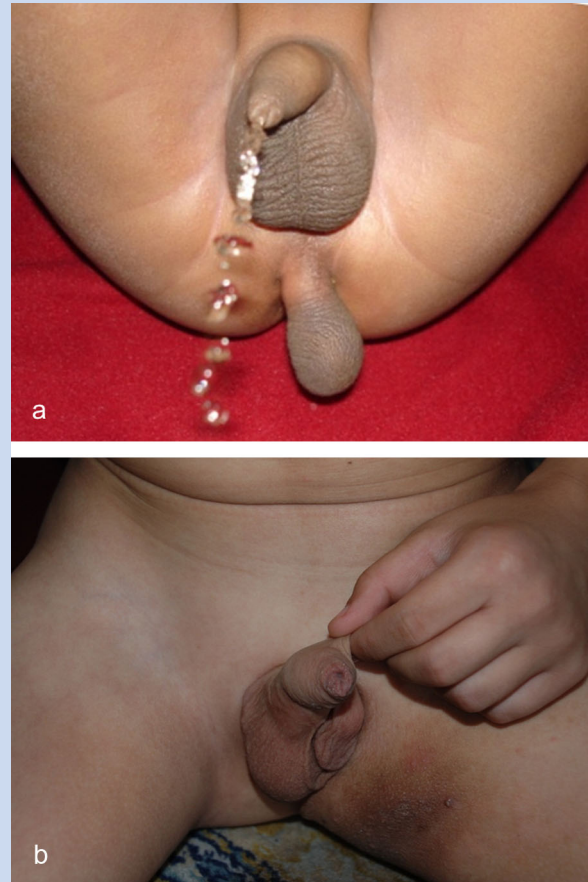


FIG. 26. Accessory scrotum. Courtesy of Dr. Paval Ganesan (panel A) and Dr. Zoran Gucev (panel B). Panel B reprinted with permission from Gucev et al. [2010].

Comments: This term is distinguished from *Accessory scrotum*, as there is no significant scrotal tissue in the normal position in ectopic scrotum. This definition excludes the finding of *Penoscrotal transposition* or *Overriding scrotum*. Usually the scrotum is split and there is unilateral ectopia. The ectopic scrotum is typically located supra-inguinally, but may be located elsewhere such as on the upper thigh. A testis is commonly present in the ectopic scrotum. Ectopic scrotum can be accompanied by *Chordee* or *Bifid penis* [Hoar et al., 1998], which should be coded separately, and by renal and non-urogenital malformations

Scrotum, hypoplastic: See *Scrotum, small*

Scrotum, hypotrophic: See *Scrotum, small*

Scrotum, Overriding: See *Scrotum, shawl*

Scrotum, prepenile: See *Penoscrotal transposition*

Scrotum, Shawl

Definition: Superior margin of the scrotum superior to the base of the penis (Fig. 29). *subjective*

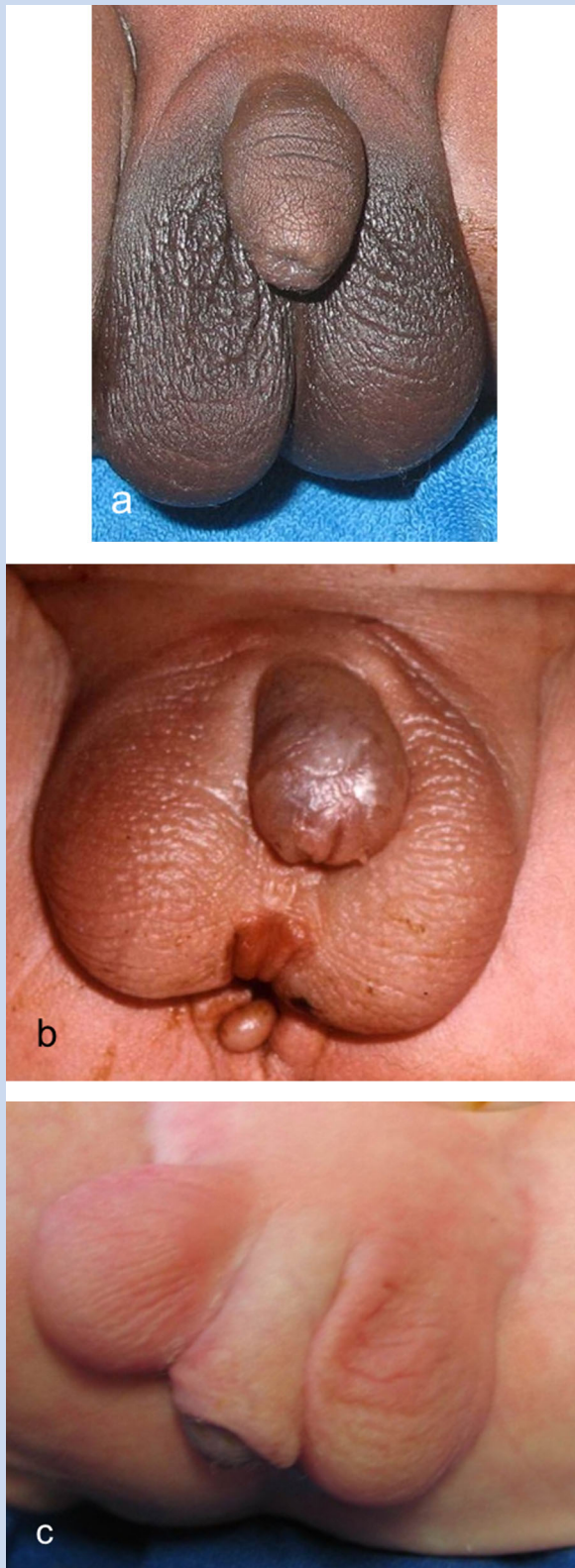


FIG. 27. Bifid scrotum. Note that in panels A and B the scrotum shows only a mild indentation and in panel C the scrotum is completely bifid.

Comments: A congenital overriding scrotum may disappear with growth and development, especially during puberty. If the entire scrotum is located superior to the penis, the term **Penoscrotal transposition** is used instead.

Synonym: Overriding scrotum

Scrotum, Small

Definition: Apparently small scrotum for age (Fig. 30). *subjective*

Comments: A small scrotum is often accompanied by **Cryptorchidism** which should be coded separately. The size of the scrotum is dependent on the ambient temperature: a low temperature may cause the testes to retract, leading to the false impression of a small scrotum.

Synonym: Scrotum, underdeveloped

Replaces: Scrotum, hypotrophic; Scrotum, hypoplastic

Scrotum, underdeveloped: See **Scrotum, small**

Testis, (Apparently) Absent

Definition: Testis not palpable in the scrotum or inguinal canal. *objective*

Comments: Absence can be congenital or not (vanishing testis). Definitive assessment can only be made by imaging or surgical studies, in order to exclude an intra-abdominal testis, which should be coded as **Cryptorchidism**. True absence of a testis can be difficult to prove. Anorchia is true absence of both testes, and can only be determined by imaging or surgical studies.

Testis, enlarged: See **Testis, large**

Testis, hyperplastic: See **Testis, large**

Testis, hypertrophic: See **Testis, large**

Testis, hypoplastic: See **Testis, small**

Testis, hypotrophic: See **Testis, small**

Testis, Large

Definition: Size of the testis more than 2 SD above the mean for age (Fig. 31). *objective* OR

Apparently increased size of the testis for age. *subjective*

Comments: Details on measurement of the testis can be found elsewhere [Hall et al., 2007]. This is in fact a bundled term indicating an increase in testis length and width but is retained here because of its utility and the availability of objective normal values.

Synonym: Macro-orchidism; Testis, overdeveloped

Replaces: Testis, hyperplastic; Testis, hypertrophic, Testis enlarged

Testis, overdeveloped: See **Testis, large**

Testis, Small

Definition: Size of the testis more than 2 SD below the mean for age (Fig. 32). *objective* OR

Apparently decreased size of the testis for age. *subjective*

Comments: Details on measurement of the testis can be found elsewhere [Hall et al., 2007].

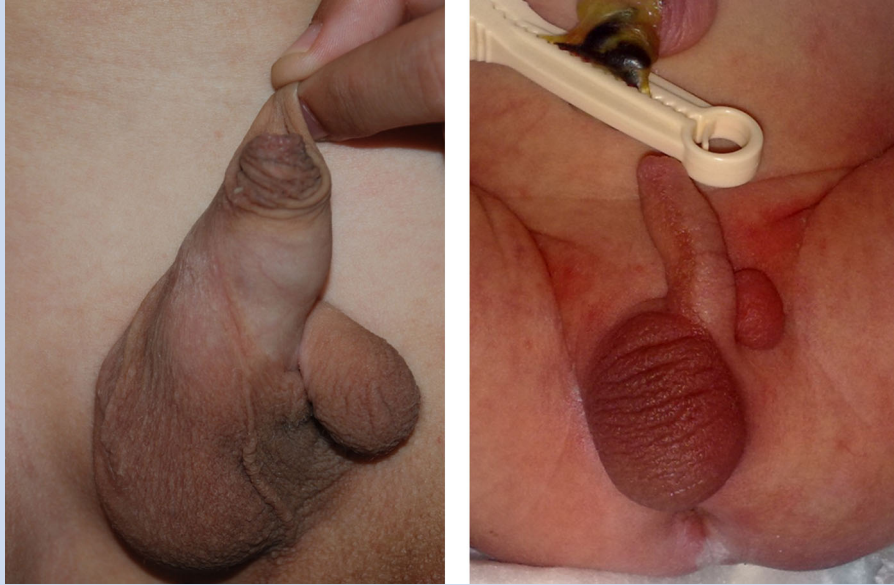

FIG. 28. Ectopic scrotum (panel a courtesy of Dr. Zoran Gucev, panel b courtesy of Dr Stefanos Gardikis). Panel A reprinted with permission from Gucev et al. [2010]. Panel B reprinted with permission from Gardikis et al. [2012].

Synonym: Testis, underdeveloped

Replaces: Testis, hypoplastic; Testis, hypotrophic

Testis, Supernumerary

Definition: More than two testes present in a hemi-scrotum or one inguinal canal (Fig. 33). *objective*

Comments: Urologists use a subclassification of supernumerary testes [Bergholz and Wenke, 2009]. A supernumerary testis may reside in the abdomen, but this is not included in the present definition as it cannot be determined by physical examination. A supernumerary testis can be difficult to distinguish from a large epididymis. Triorchidism is sometimes used to describe a single supernumerary testis.

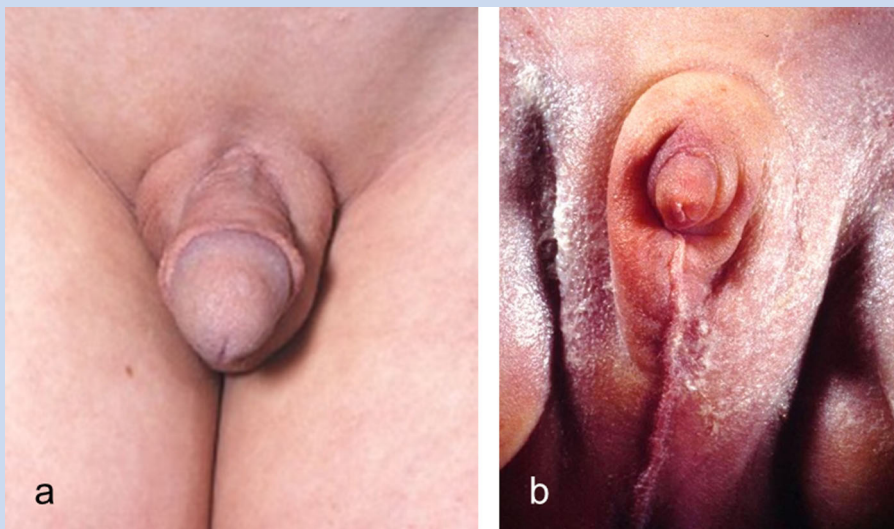


FIG. 29. Shawl scrotum. Note only partly overriding scrotum in panel A and complete overriding in panel B.

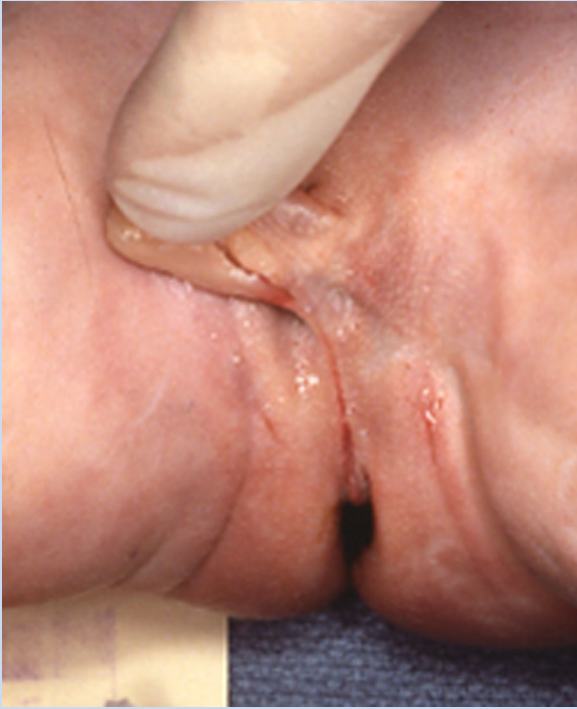

FIG. 30. Small scrotum.

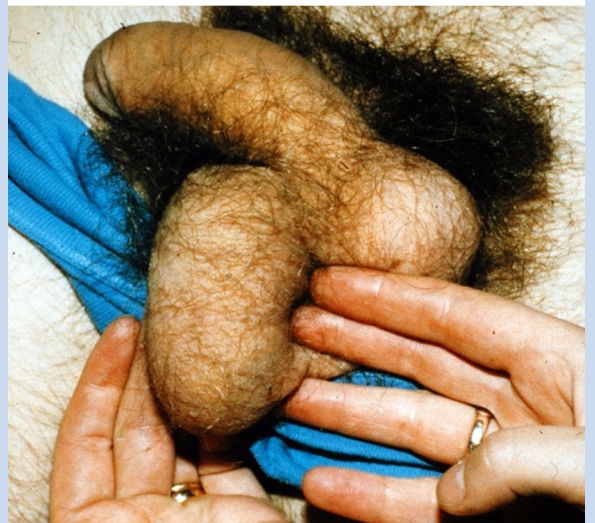
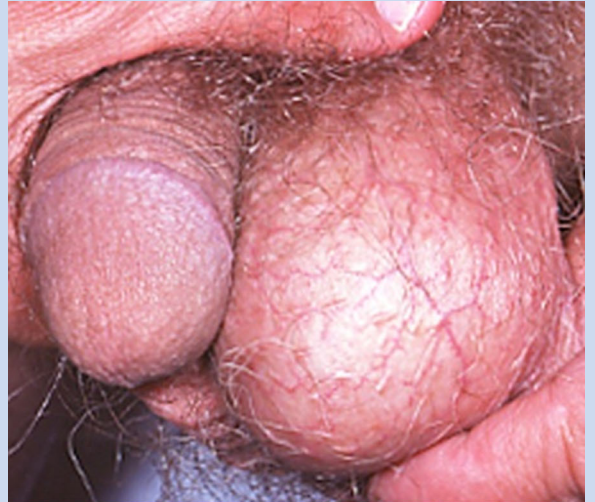
FIG. 31. Large testis.

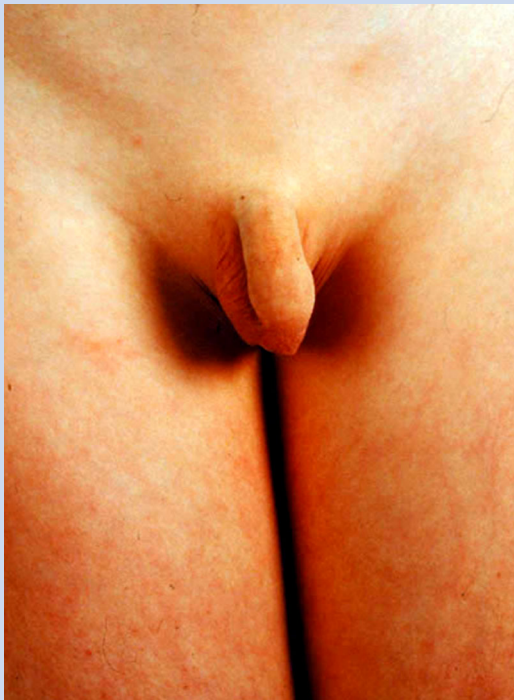


FIG. 32. Small testis (in a pubertal boy).

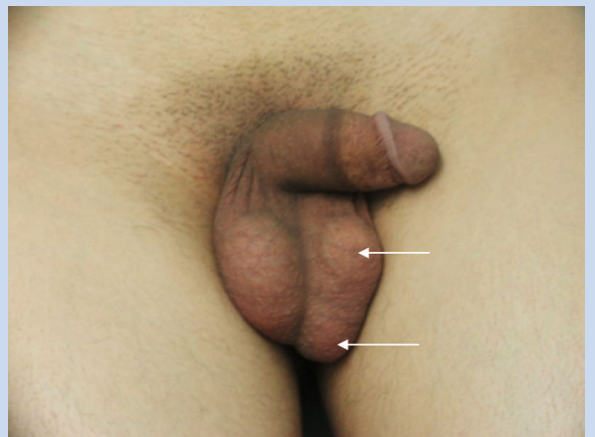

FIG. 33. Supernumerary testis (two testes in left hemiscrotum indicated by arrows). Courtesy of Dr. Ali Feyzullah Şahin. Reprinted with permission from Yalcinkaya et al. [2011].

Synonym: Polyorchidism

Testis, underdeveloped: See *Testis, small*

Testis, undescended: See *Cryptorchidism*

FEMALE EXTERNAL GENITALIA

Anatomy of the Female External Genitalia

Normal anatomy of the female external genitalia is shown in Figure 34. Some anatomical landmarks deserve specific mention as these are not always used consistently.

Labia majora: Two relatively broad soft tissue skin-covered swellings running alongside one another inferoposteriorly, in close proximity anteriorly at the mons pubis (sometimes called anterior commissure) and joining at the posterior commissure. They encircle the vulval vestibule, which contains the urethra and vagina. In young girls the skin is smooth and only slightly hyperpigmented, but the skin gradually undergoes further hyperpigmentation, hair growth and rugae formation. The inner part is covered by thin skin and mucous membrane and contains many sebaceous glands.

Labia minora: Two relatively narrow, hairless soft tissue swellings medial to the labia majora, covered with mucous membranes, running inferoposteriorly from the base of the clitoris to fuse posteriorly at the fourchette. There is marked variation in size of the labia minora, and, in postpubertal females, they often protrude beyond the labia majora.

Interlabial sulci: the regions between the inner parts of the labia majora and outer parts of the labia minora.

Clitoris: Cap-shaped organ supero-anterior to the entrance of the vagina, partly covered by a foreskin (hood). The size of the clitoris depends on whether it is erect or flaccid.

Clitoral foreskin (hood): Skin fold overriding and partially covering the glans of the clitoris and inferioposteriorly continuous with the labia minora.

Clitoral frenula: Small elastic tissue folds covered by mucous membranes running from the glans of the clitoris to the labia minora.

Hymen: Epithelial fold partly covering the inferior opening of the vagina. The virginal hymen has an opening that is variable in size, shape, and position (Fig. 35).

Vagina: Hollow organ ending inferiorly at the vulval vestibule (introitus) between the labia minora, and superiorly at the cervix of the uterus. The vagina is collapsed most of the time.

Vulva: Region delimited by the labia majora and containing the labia minora, clitoris, urethral meatus, and introitus. The vulval vestibule (introitus) is the region between the labia minora.

Puberty

The timing of puberty varies greatly in the general population and is influenced by genetic and environmental factors [Gajdon et al., 2009]. In evaluating the pubertal development, ethnic background and intra-familial variation should be taken into account. Tanner stages are used to score pubertal development [Marshall and Tanner, 1969; Tanner, 1986]. In females the stages are determined by the size of the breasts and nipples, pigmentation and rugae formation of the labia, and pubic and axillary hair growth (Fig. 36). As each of these components is defined here separately, the pubertal stages are not discussed in further detail.

Measurements of the Female External Genitalia

Measurement of the clitoris is the only measurement of female external genitalia commonly used in the clinic. Measurements of the clitoris are possible using sliding calipers, or a straight-edged plastic ruler. Reliability of measurements using a tape measure is poor. Length is measured from the base of the clitoris at the pubic symphysis to the tip without including the foreskin. Fat pads at the base of the clitoris influence this measurement and the ruler should be pressing against the pubic ramus. The reader is referred to the Handbook of Normal Physical Measurements [Hall et al., 2007] for detailed descriptions of measurement techniques and growth standards. Except for pubertal developmental stages growth standards are provided for Caucasians of Northern European origin only.

Anatomical Variation

Anomalies of the female external genitalia may be classified into quantitative (objective or anthropometric) traits and qualitative (subjective or categorical) features:

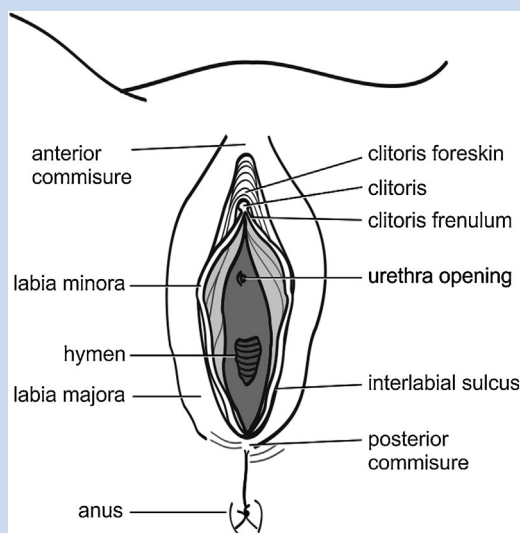


FIG. 34. Anatomy of female external genitalia.

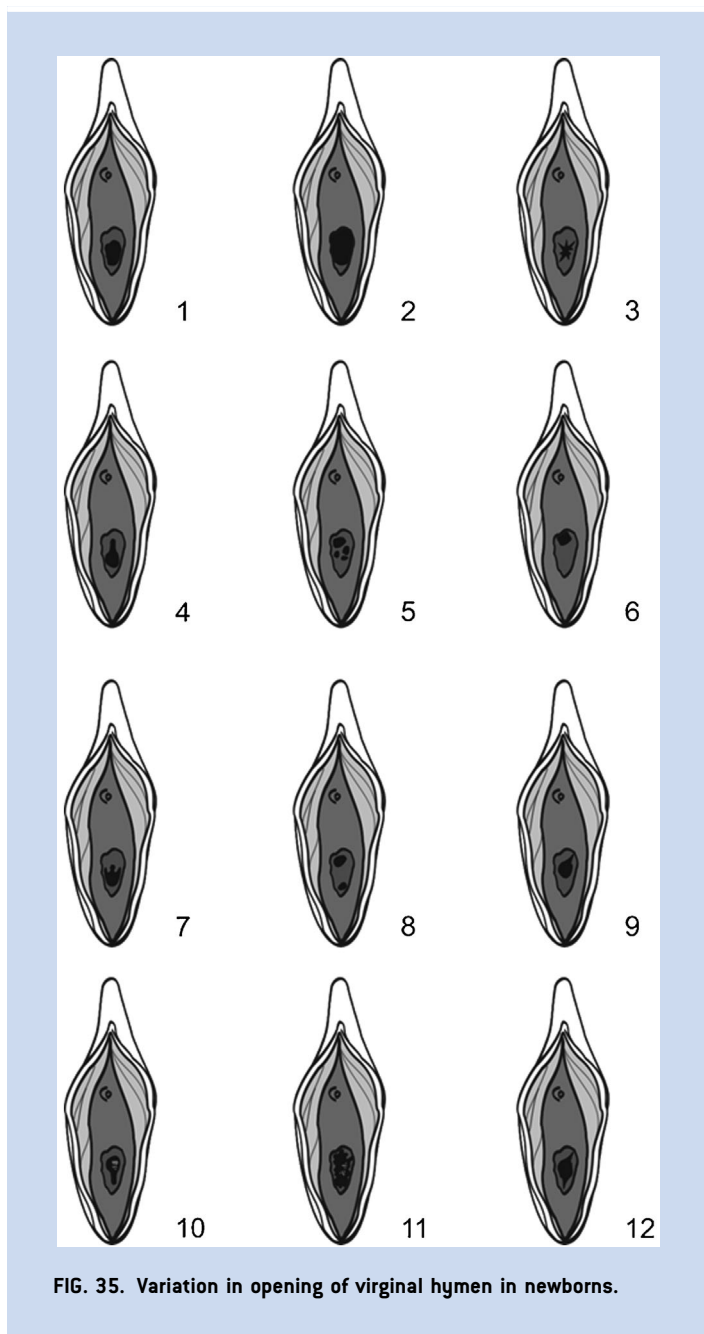


FIG. 35. Variation in opening of vaginal hymen in newborns.

1. Variations in length and width: large clitoris; small clitoris; absent labia majora; absent labia minora; large labia majora; small labia majora; prominent labia minora.
2. Variations in shape, number, or position: bifid clitoris; duplicated clitoris; fused labia minora; epispadias; hypospadias; atretic vaginal opening; septated vagina.
3. Variations in skin manifestations: freckled genitalia; hyperpigmented genitalia; hypopigmented genitalia; exaggerated rugosity of the labia majora; sparse pubic hair.

The various features are listed alphabetically. If a feature is indicated in **bold-italics**, the feature is listed and a definition is available. The terms are alphabetized based on the physical feature, not the modifier.

Investigating the genitalia should always be performed with the observed person in a relaxed position. The presence of a nurse or parent is advisable. Small children are best investigated in their parent's lap. Repeated genital examinations may be embarrassing for the subject [Lee et al., 2006] and should be performed only when indicated.

DEFINITIONS

Clitoris, Bifid

Definition: Two clitorides located side by side (Fig. 37). *objective*

Comments: The word bifid indicates the presence of a split clitoris, as opposed to a supernumerary clitoris, which could be described as **Duplicated clitoris**. A bifid clitoris is almost invariably accompanied by **Epispadias**, which should be coded separately.

Clitoris, Duplicated

Definition: A supernumerary clitoris (Fig. 38) *objective*

Comments: A duplicated clitoris is much less common than a **Bifid clitoris**, which should be considered first in most cases [Kurth, 1958].

Synonym: Clitoris, supernumerary

Clitoris, hyperplastic: See **Clitoris, large**

Clitoris, hypertrophic: See **Clitoris, large**

Clitoris, hypoplastic: See **Clitoris, small**

Clitoris, hypotrophic: See **Clitoris, small**

Clitoris, Large

Definition: Clitoral length more than 2 SD above the mean for age (Fig. 39). *objective* OR

Apparently increased length of the clitoris for age. *subjective*

Comments: Clitoral length is the distance between the attachment of the clitoris anterior to the pubic bone and tip of the clitoris. Details on measurement of the clitoris can be found elsewhere [Oberfield et al., 1989; Litwin et al., 1991; Sane and Pescovitz, 1992; Verkauf et al., 1992; Phillip et al., 1996; Akbiyik and Kutlu, 2010]. Subjective assessment of clitoral size can be confounded by **Small labia majora** and therefore objective assessment is preferred. The word "large" literally indicates an increase in both width and length, but in practice only the length of the clitoris is measured.

Synonym: Clitoromegaly; Clitoris, overdeveloped; Clitoris, long

Replaces: Clitoris, hypertrophic; Clitoris, hyperplastic

Clitoris, long: See **Clitoris, large**

Clitoris, overdeveloped: See **Clitoris, large**

Clitoris, Small

Definition: Clitoral length more than 2 SD below the mean for age (Fig. 40). *objective* OR

Apparently decreased length of the clitoris for age. *subjective*

Comments: Clitoral length is the distance between the attachment of the clitoris anterior to the pubic bone and tip of the clitoris. Details on measurement of the clitoris can be found elsewhere [Oberfield et al., 1989; Litwin et al., 1991; Sane and Pescovitz, 1992; Verkauf et al., 1992; Phillip et al., 1996; Akbiyik and Kutlu, 2010]. Subjective

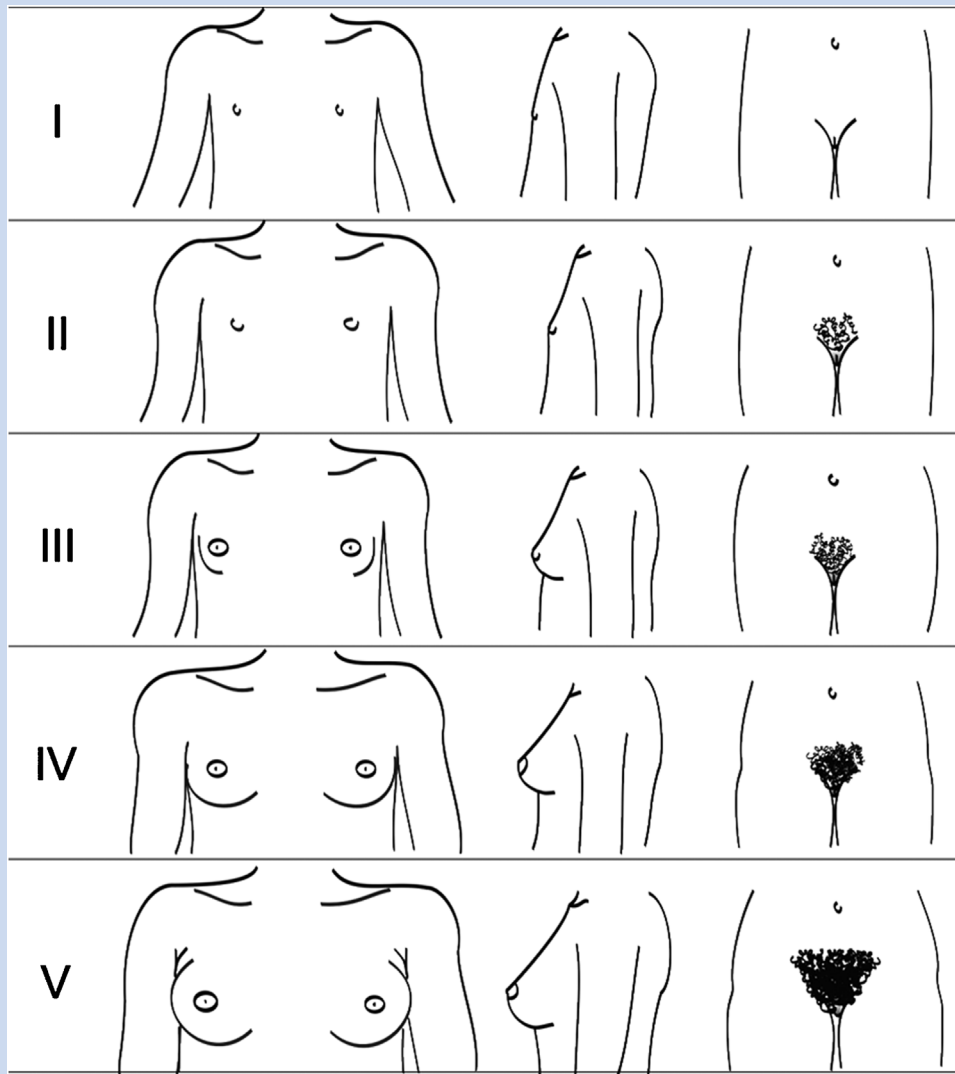


FIG. 36. Puberty stages females according to Tanner [1986].

assessment of clitoral size can be confounded by obesity and therefore objective assessment is preferred. The word small literally indicates a decrease in both width and length, but in practice only the length of the clitoris is measured.

Synonym: Clitoris, underdeveloped

Replaces: Clitoris, hypotrophic; Clitoris, hypoplastic

Clitoris, supernumerary: See *Clitoris, duplicated*

Clitoris, underdeveloped: See *Clitoris, small*

Clitoromegaly: See *Clitoris, large*

Epispadias

Definition: Dorsal placement of the urethral opening (Fig. 37). *objective*

Comments: In a phenotypic female, epispadias may be accompanied by a *Bifid clitoris*, which should be coded separately.

Epispadias is a frequent component of *Bladder exstrophy*, but should be coded separately.

Genitalia, Ambiguous

Definition: External genitalia without typical male or female appearance (Fig. 9). *subjective*

Comments: Note that this term can include or combine variations in size and shape, with partial or complete absence of structures. It is preferable to describe the individual components, which are defined below. It is nonetheless a widely used bundled term and as such is retained here (for the definition of a “bundled term” see Allanson et al. [2009a]).

Synonym: Intersex genitalia

Genitalia, ephelides: See *Genitalia, freckled*

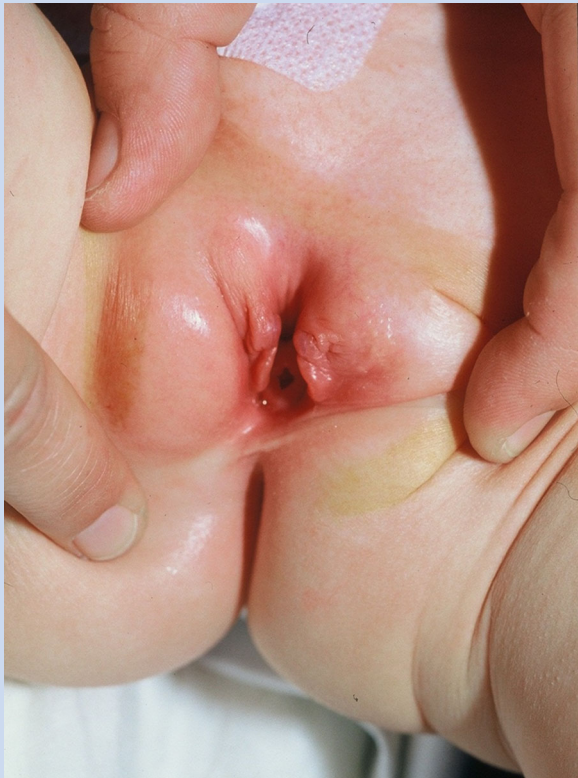

FIG. 37. Bifid clitoris. Note the co-occurrence of epispadias. Courtesy of Dr. Anne-Karoline Ebert. Reprinted with permission from Ebert et al. [2009].

Genitalia, Freckled

Definition: One or more brown punctate macules on the skin of the genitalia (Fig. 10). *objective*

Comments: This should be differentiated from *Hyperpigmented genitalia* in which an area larger than a freckle is/the complete

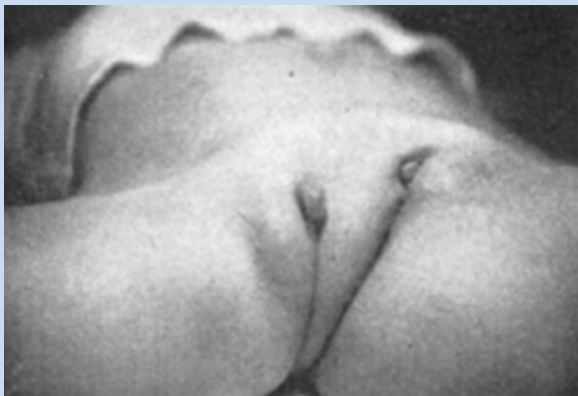

FIG. 38. Duplicated clitoris. Reprinted with permission from Kurth [1958].

external genitalia are hyperpigmented. The description should be qualified by a description of the affected part(s).

Synonym: Genitalia, ephelides

Genitalia, Hyperpigmented

Definition: Localized or generalized increased genital pigmentation (Fig. 11). *subjective*

Comments: This is an assessment of the relative pigmentation of the genitalia compared to the overall pigmentation of the individual. Hyperpigmentation can affect other parts of the body or be restricted to the genitalia. Genital hyperpigmentation can be generalized or localized. It should be differentiated from *Freckled genitalia* in which one or more small, focal areas of hyperpigmentation are present. Localized hyperpigmentation can be objectively determined due to the difference from the immediate surrounding tissue color, while generalized hyperpigmentation may be more difficult to determine and is therefore a subjective manifestation. If the finding is localized, the description should be appended with a description of the affected part(s).

Genitalia, Hypopigmented

Definition: Localized or generalized decreased genital pigmentation (Fig. 12). *subjective*

Comments: This is an assessment of the relative pigmentation of the genitalia compared to the overall pigmentation of the individual. Hypopigmentation can affect other parts of the body or be restricted to the genitalia. Genital hypopigmentation can be generalized or localized. Localized hypopigmentation can be objectively determined due to the difference from the immediate surrounding tissue color, while generalized hypopigmentation may be more difficult to determine and is therefore a subjective manifestation.

Genitalia, intersex: See *Genitalia, ambiguous*

Hypospadias

Definition: Urethral meatus located on the anterior vaginal wall (Fig. 41). *objective*

Comments: The location of the meatus can be from just above the introitus up to deep into the vagina near the cervix (fornix). Female hypospadias can be associated with *Bladder exstrophy*, which should be coded separately

Labia Majora, Absent

Definition: No discernable labia majora (Fig. 42). *subjective*

Comments: None of the three attributes of labia majora is present: no tissue mass, no hyperpigmentation, no rugae formation.

Labia majora, hyperplastic: See *Labia majora, large*

Labia majora, hypertrophic: See *Labia majora, large*

Labia majora, hypoplastic: See *Labia majora, small*

Labia majora, hypotrophic: See *Labia majora, small*

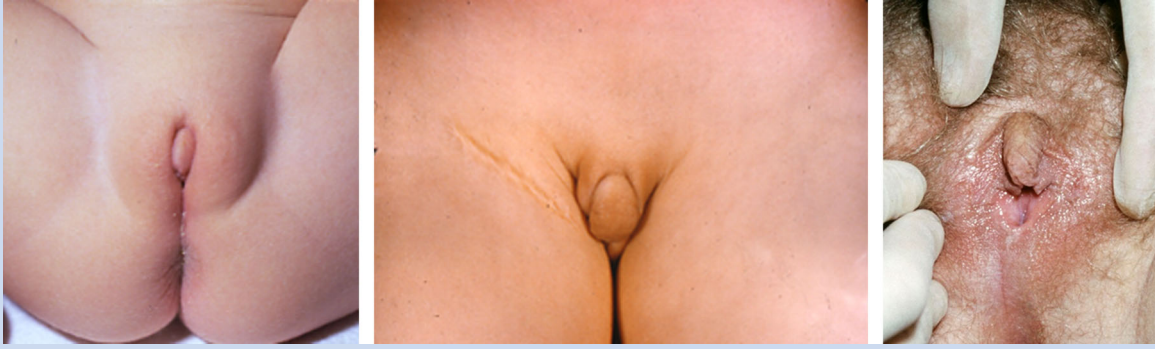

FIG. 39. Large clitoris.

Labia Majora, Large

Definition: Increased volume of the labia majora (Fig. 43). *subjective*

Comments: Large labia majora may be accompanied by *Hyperpigmented genitalia* or *Exaggerated rugosity of the labia majora*, which should be coded separately.

Synonym: Labia majora, overdeveloped

Replaces: Labia majora, hypertrophic; Labia majora, hyperplastic

Labia Majora, Exaggerated Rugosity of the

Definition: Marked rugae formation of the skin of the labia majora (Fig. 44). *subjective*

Comments: Some rugae formation is typically found on the labia majora, but less than on the scrotum.

Replaces: Scrotum-like labia majora

Labia majora, overdeveloped: See *Labia majora, large*

Labia majora, scrotum-like: See *Labia majora, exaggerated rugosity of the*

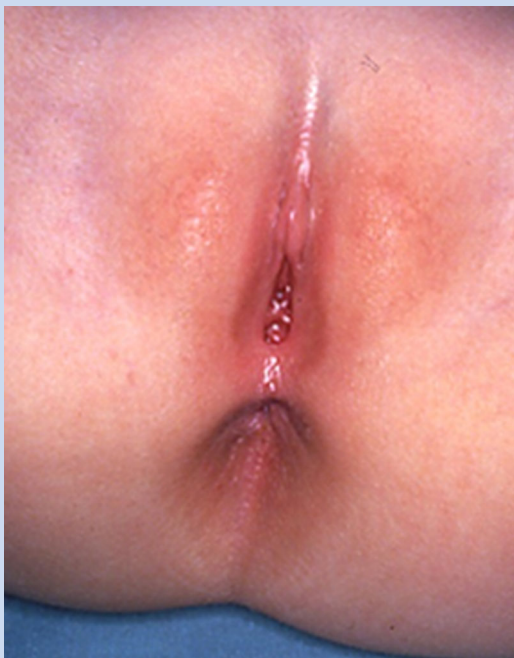

FIG. 40. Small clitoris.

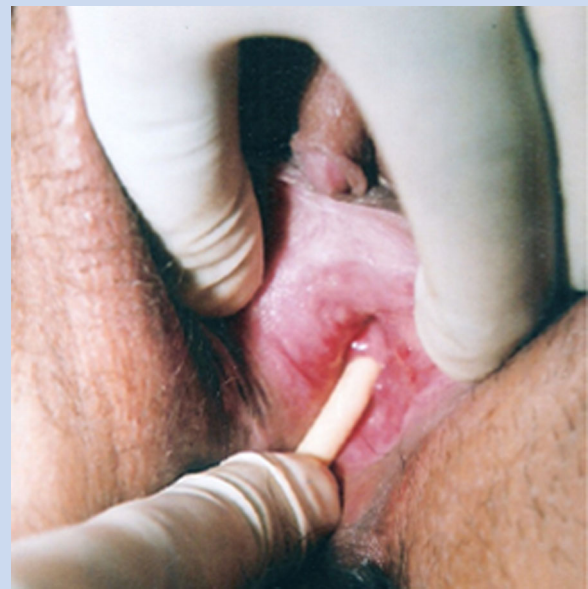

FIG. 41. Hypospadias (a catheter being in hypospadiac opening high in the anterior vaginal wall). Courtesy of Dr. Amilal Bhat. Reprinted with permission from Bhat et al. [2010].

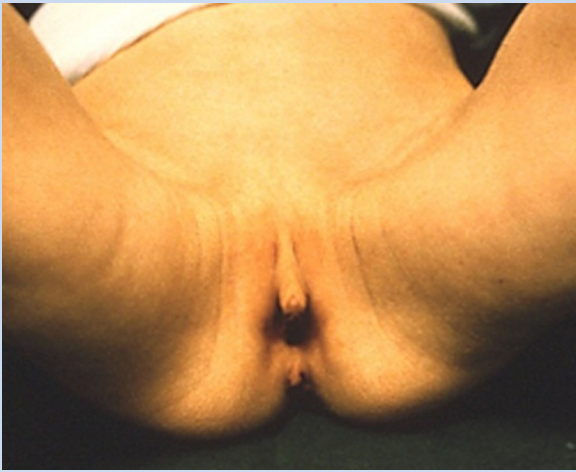

FIG. 42. Absent labia majora.




FIG. 43. Large labia majora. Courtesy of Dr. Ariachery Ammini. Reprinted with permission from Kulshreshtha et al. [2010].

Labia Majora, Small

Definition: Apparently decreased soft tissue volume of the labia majora (Fig. 45). *subjective*

Comments: The hyperpigmentation and mild rugae formation of the labia majora may or may not be decreased.

Synonym: Labia majora, underdeveloped

Labia majora, underdeveloped: See **Labia majora, small**

Labia Minora, Absent

Definition: No recognizable soft tissue folds medial to the labia majora (Fig. 46). *subjective*

Labia Minora, Fused

Definition: Lack of separation of the labia minora over part or all of their length (Fig. 47). *objective*

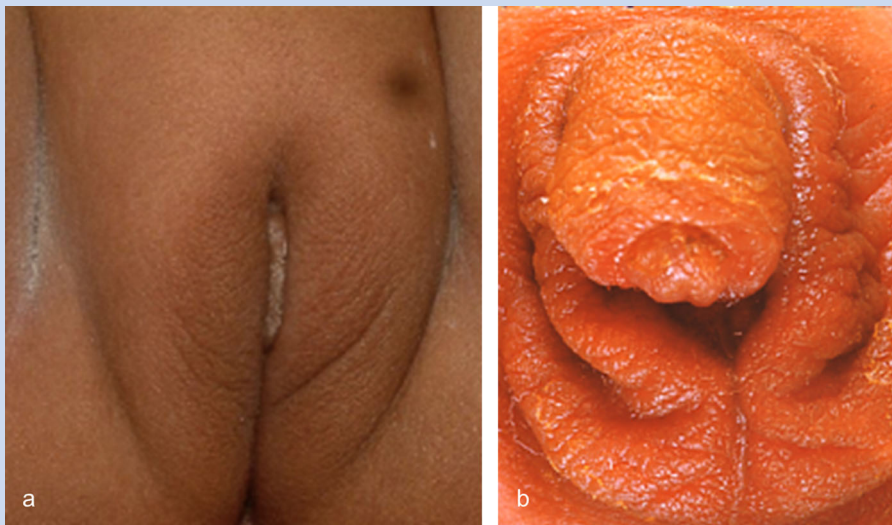


FIG. 44. Labia majora with mild (a) and more marked (b) rugae formation. Note enlargement of clitoris as well in panel B. Panel a courtesy of Dr. Ariachery Ammini. Panel a reprinted with permission from Atilgan et al. [2009].

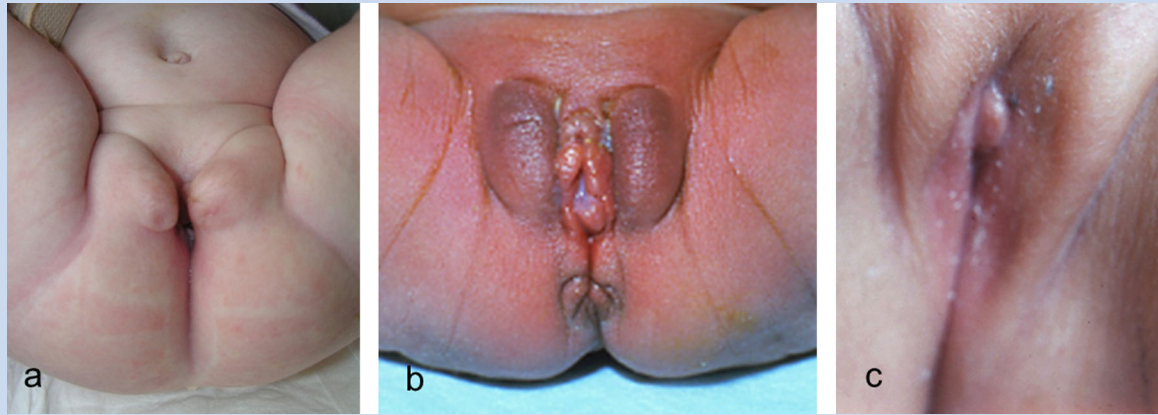


FIG. 45. Small upper part (panels a and b) and lower part (panel C) of labia majora.

Comments: Fusion is not infrequent in newborn girls and separation may occur spontaneously in the first few years of life.

Labia Minora, Prominent

Definition: Apparent increase in volume of the labia minora (Fig. 48). *subjective*

Comments: Variation in the size of labia minora is considerable. This is in fact a bundled term as it may indicate an increase of length, width and/or thickness, but it is useful in practice and therefore kept here. Labia minora may appear prominent in the presence of **Small labia majora**.

Pubic hair, hypotrichosis: See **Pubic hair, sparse**

Pubic hair, Sparse

Definition: Apparently decreased number of hairs per unit area relative to the pubertal development as judged by other components of pubertal maturity (Fig. 49) *subjective*

Comments: (Pubic) hypotrichosis should not be used as a synonym as, formally, it means underdevelopment of the hair. No normal values for the number of hairs per unit area exist.

Replaces: Pubic hair, thinning; Pubic hair, thin; Pubic hypotrichosis

Pubic hair, thin(ning): See **Pubic hair, sparse**

Vagina, Atretic Opening of the

Definition: No discernable entrance to the vagina on the vulva (Fig. 50). *objective*

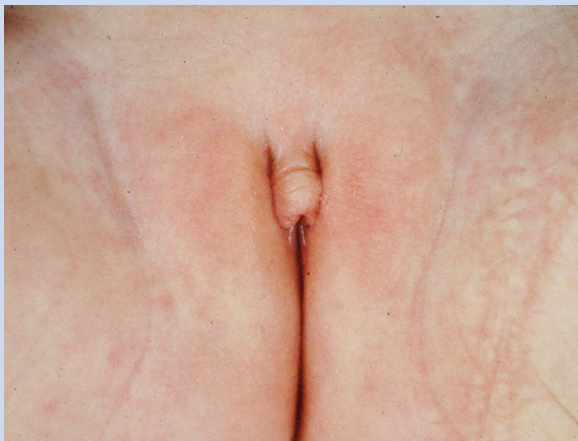


FIG. 46. Absent labia minora. Note this causes a seemingly large clitoris which is in fact of normal size.

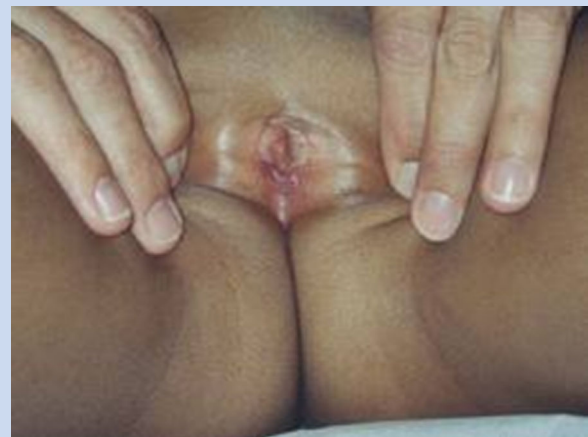

FIG. 47. Fused labia minora. Courtesy of Dr. AKC Leung.

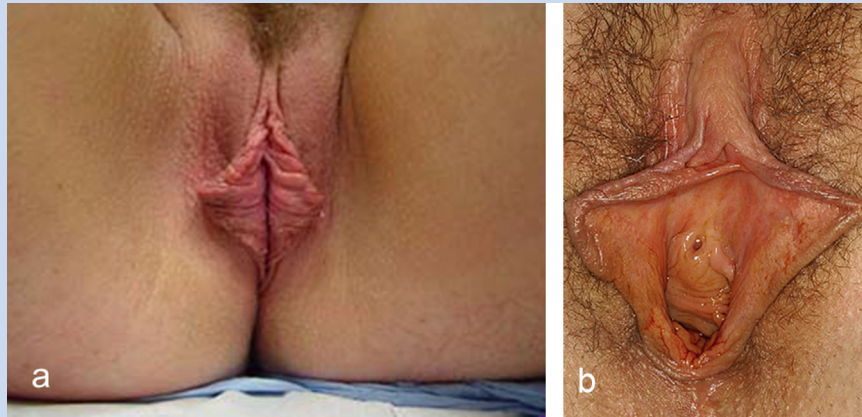


FIG. 48. Prominent labia minora which is unilateral on the right panel. Panel a courtesy of Dr. Warren Ellsworth, panel b courtesy of Dr. Charles Malata. Panel a reprinted with permission from Ellsworth et al. [2010]. Panel B reprinted with permission from Solanki et al. [2010].

Comments: An atretic opening may occur independent of atresia of the remainder of the vagina, which needs further radiological and/or surgical investigations to diagnose.

Vagina, Septated

Definition: Apparent lateral division of the vagina by a thin tissue wall visible at the introitus (Fig. 51). *objective*

Comments: The term does not indicate the pathogenetic mechanism and does not distinguish a double vagina from a septum within a single vagina. Neither a transverse vaginal septum nor a

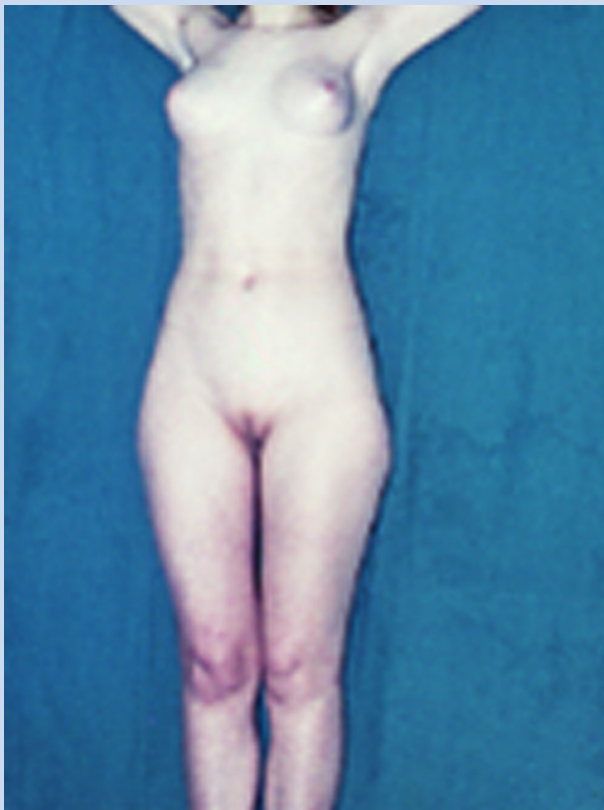

FIG. 49. Sparse pubic hair (in a pubertal female).

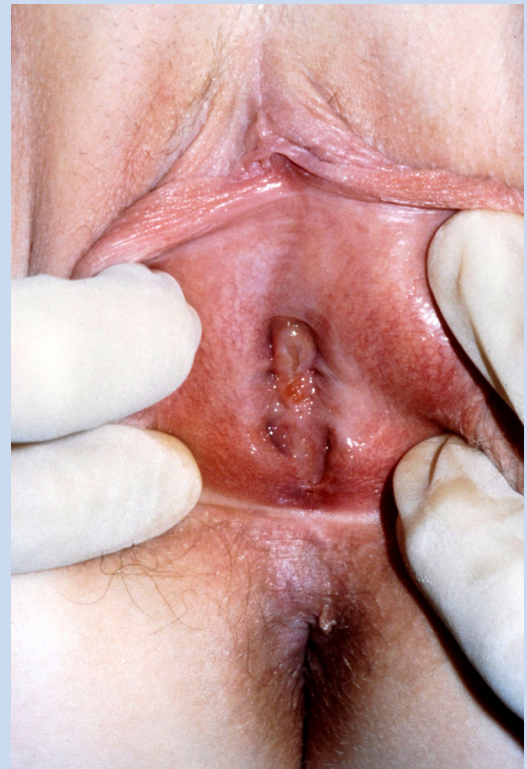

FIG. 50. Atretic opening of the vagina.

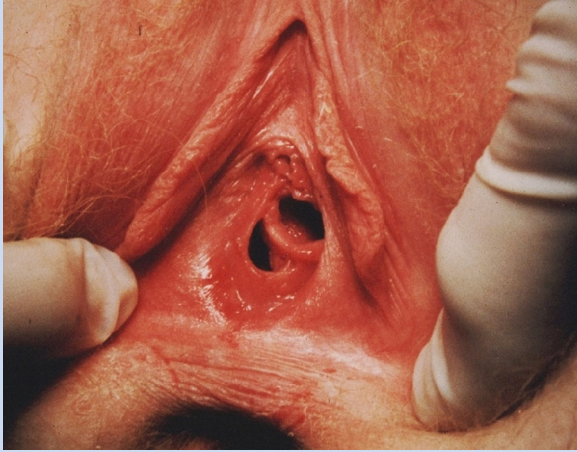


FIG. 51. Septated vagina.

septum present in the deeper two-thirds of the vagina can be assessed on external physical examination.

ACKNOWLEDGMENTS

We are pleased to thank Astrid Sibbes, Medical Photography and Illustration, Academic Medical Centre, Amsterdam for all drawings, and Dr. F.B. Lammes, pediatric gynecologist, for making his photography collection available to us. E.V. is partially funded by the DSD Translational Research Network (NIH grant # 1 R01 HD068138), and L.G.B. is supported by the Intramural Research Program of the National Human Genome Research Institute.

REFERENCES

- Adams MV. 1996. *The multicultural imagination: Race, color, and the unconscious*. London: Routledge. p 164.
- Ajmani ML, Jain SP, Saxena SK. 1985. Anthropometric study of male external genitalia of 320 healthy Nigerian adults. *Anthropol Anz* 43:179–186.
- Akbiyik F, Kutlu AO. 2010. External genital proportions in prepubertal girls: A morphometric reference for female genitoplasty. *J Urol* 184:1476–1481.
- Allanson JE, Biesecker LG, Carey JC, Hennekam RCM. 2009a. Elements of morphology: Introduction. *Am J Med Genet Part A* 149A:2–5.
- Allanson JE, Cunniff C, Hoyme HE, McGaughan J, Muenke M, Neri G. 2009b. Elements of morphology: Standard terminology for the head and face. *Am J Med Genet Part A* 149A:6–28.
- Atilgan D, Uluocak N, Erdemir F, Parlaktas BS. 2009. Female epispadias: A case report and review of the literature. *Kaohsiung J Med Sci* 25:613–616.
- Baskin LS, Duckett JW. 1996. Hypospadias, in adult and pediatric urology. In: J. Gillenwater, J. Grayhack, S. Howards, M. Mitchell, editors. *Adult and pediatric urology*, 4th edition, St. Louis: Mosby.
- Bauer R, Kogan BA. 2009. Modern technique for penile torsion repair. *J Urol* 182:286–291.
- Bergeson PS, Hopkin RJ, Bailey RB, Mc Gill LC, Piatt JP. 1993. The inconspicuous penis. *Pediatrics* 92:794–799.
- Bergholz R, Wenke K. 2009. Polyorchidism: A meta-analysis. *J Urol* 182:2422–2427.
- Bhat A, Saxena R, Bhat MP, Dawan M, Saxena G. 2010. Female hypospadias with vaginal stones: A rare congenital anomaly. *J Pediatr Urol* 7:70–74.
- Biesecker LG, Aase JM, Clericuzio C, Gurrieri F, Temple IK, Toriello H. 2009. Elements of morphology: Standard terminology for the hands and feet. *Am J Med Genet Part A* 149A:93–127.
- Bologna RA, Noah TA, Nasrallah PF, McMahon DR. 1999. Chordee: Varied opinions and treatments as documented in a survey of the American Academy of Pediatrics, Section of Urology. *Urology* 53:608–612.
- Carey JC, Cohen MM Jr, Curry CJR, Devriendt K, Holmes LB, Verloes A. 2009. Elements of morphology: Standard terminology for the lips, mouth and oral region. *Am J Med Genet Part A* 149A:77–92.
- Cheng PK, Chanoine JP. 2001. Should the definition of micropenis vary according to ethnicity? *Horm Res* 55:278–281.
- Chibber PJ, Shah HN, Jain P, Yadav P. 2005. Male gender assignment in aphallia: A case report and review of the literature. *Int Urol Nephrol* 37:317–319.
- Cinaz P, Yeşilkaya E, Onganlar YH, Boyraz M, Bideci A, Camurdan O, Baki Karaoğlu A. 2012. Penile anthropometry of normal prepubertal boys in Turkey. *Acta Paediatr* 101:e33–e36.
- Damon V, Berlier P, Durozier B, François R. 1990. Study of the dimensions of the penis from birth to adult age and as a function of testicular volume. *Pediatric* 45:519–522.
- Ebert AK, Reutter H, Ludwig M, Rösch WH. 2009. The extrophy-epispadias complex. *Orphanet J Rare Dis* 4:23.
- El-Koutby M, Amin el Gohary M. 2010. Webbed penis: A new classification. *J Indian Assoc Pediatr Surg* 15:50–52.
- Ellsworth WA, Rizvi M, Lypka M, Gaon M, Smith B, Cohen B, Dinh T. 2010. Techniques for labia minora reduction: An algorithmic approach. *Aesth Plast Surg* 34:105–110.
- Fathi K, Perovic S, Pinter A. 2010. Successful surgical correction of an extreme form of ectopic penis. *J Pediatr Urol* 6:426–428.
- Gajdon ZKZ, Hirschhorn JN, Palmert MR. 2009. What controls the timing of puberty? An update on progress from genetic investigation. *Curr Opin Endocrinol Diabetes Obes* 16:16–24.
- Gardikis S, Kambouri K, Tsalkidis A, Angelidou M, Pitiakoudis M, Vaos G. 2012. Inguinal ectopic scrotum in a neonate: Case report and literature review. *Pediatr Int* 54:575–576.
- Gucev Z, Castori M, Tasic V, Popjordanova N, Hasani A. 2010. A patient with unilateral tibial aplasia and accessory scrotum: A pure coincidence or nonfortuitous association? *Case Report Med* 2010:898636.
- Hall JG, Allanson JA, Gripp K, Slavotinek A. 2007. *Handbook of normal physical measurements*, 2nd edition. New York: Oxford University Press.
- Hall BD, Graham JM Jr, Cassidy SB, Opitz JM. 2009. Elements of morphology: Standard terminology for the periorbital region. *Am J Med Genet Part A* 149A:29–39.
- Hennekam RCM, Cormier-Daire V, Hall JG, Méhes K, Patton M, Stevenson RE. 2009. Elements of morphology: Standard terminology for the nose and philtrum. *Am J Med Genet Part A* 149A:61–76.
- Hoar RM, Calvano CJ, Reddy PP, Bauer SB, Mandell J. 1998. Unilateral suprainguinal ectopic scrotum. The role of the gubernaculum in the formation of an ectopic scrotum. *Teratology* 57:54–59.

- Hunter A, Frias J, Gillessen-Kaesbach G, Hughes H, Jones K, Wilson L. 2009. Elements of morphology: Standard terminology for the ear. *Am J Med Genet Part A* 149A:40–60.
- Janoff DM, Skoog SJ. 2005. Congenital scrotal agenesis: Description of a rare anomaly and management strategies. *J Urol* 173:589–591.
- Keckler S, Stephany HA, Spilde TL, Snyder CL. 2009. Isolated diphallia: Case report and literature review. *Eur J Pediatr Surg* 19:254–255.
- Kulshreshtha B, Khadgawat R, Eunice M, Ammini AC. 2010. Congenital adrenal hyperplasia: Results of medical therapy on appearance of external genitalia. *J Pediatr Urol* 6:555–559.
- Kurth ME. 1958. Incomplete duplication of the female external genitalia or double clitoris. *Am J Surg* 96:596–599.
- Lee PA, Houk CP, Ahmed SF, Hughes IA. 2006. Consensus statement on management of intersex disorders. International Consensus Conference on Intersex. *Pediatrics* 118:e488–e500.
- Litwin A, Aitkin I, Merlob P. 1991. Clitoral length assessment in newborn infants of 30 to 41 weeks gestational age. *Eur J Obstet Gynecol Reprod Biol* 38:209–212.
- Marshall WA, Tanner JM. 1969. Variations in the pattern of pubertal changes in girls. *Arch Dis Child* 44:291–303.
- Montag S, Palmer LS. 2011. Abnormalities of penile curvature: Chordee and penile torsion. *Sci World J* 11:1470–1478.
- Oberfield SE, Mondok A, Shahrivar F, Klein JF, Levine LS. 1989. Clitoral size in full-term infants. *Am J Perinatol* 6:453–454.
- Orkiszewski M. 2012. A standardized classification of hypospadias. *J Pediatr Urol* 8:410–414.
- Phillip M, De Boer C, Pilpel D, Karplus M, Sofer S. 1996. Clitoral and penile sizes of full term newborns in two different ethnic groups. *J Pediatr Endocrinol Metab* 9:175–179.
- Ponchietti R, Mondaini N, Bonafé M, Di Loro F, Biscioni S, Masieri L. 2001. Penile length and circumference: A study on 3,300 young Italian males. *Eur Urol* 39:183–186.
- Rattan KN, Kajal P, Pathak M, Kadian YS, Gupta R. 2010. Aphallia: Experience with 3 cases. *J Pediatr Surg* 45:e13–e16.
- Roth JK Jr, Marshall RH, Angel JR, Daftary M, Lewis RW. 1981. Congenital absence of penis. *Urology* 17:579–583.
- Sadeghipour RS, Esmailzadehha N. 2010. Aposthia: A case report. *J Pediatr Surg* 45:317–319.
- Sane K, Pescovitz OH. 1992. The clitoral index: A determination of clitoral size in normal girls and in girls with abnormal sexual development. *J Pediatr* 120:264–266.
- Schneider T, Sperling H, Lümmer G, Syllwasschy J, Rübber H. 2001. Does penile size in younger men cause problems in condom use? A prospective measurement of penile dimensions in 111 young and 32 older men. *Urology* 57:314–318.
- Solanki NS, Tejero-Trujeque R, Stevens-King A, Malata CM. 2010. Aesthetic and functional reduction of the labia minora using the Maas and Hage technique. *J Plast Reconstr Aesth Surg* 63:1181–1185.
- Tanner JM. 1986. Normal growth and techniques of growth assessment. *Clin Endocrinol Metab* 15:411–451.
- Verkauf BS, Von Thron J, O'Brien WF. 1992. Clitoral size in normal women. *Obstet Gynecol* 80:41–44.
- Wang H, Guo K, Wang J, Liu L, Li F. 2011. Aphallia in an adult male with 46, XY karyotype. *Int J Urol* 18:540–542.
- Yalcinkaya S, Sahin C, Sahin AF. 2011. Polyorchidism: Sonographic and magnetic resonance imaging findings. *Can Urol Assoc J* 5:e84–e86.